

# An Analysis of Trends of Incidence And Pathological Study of Non Specific Granulomatous Prostatitis Encountered in Turp Specimens And Its Correlation with Serum PSA Levels

Alpana choudhary<sup>1</sup>, Alok choudhary<sup>2</sup>

<sup>1</sup>Associate Professor (Department Of Pathology, JNU  
Institute For Medical Sciences And Research Centre, Jaipur, India.)

<sup>2</sup>Consultant Paediatrician (Rajgovind Child Clinic, Jaipur, India.)

Corresponding Author: Alpana Choudhary 1,

---

**Abstract:** Introduction: Granulomatous prostatitis is an inflammatory condition of the prostate that histologically features the presence of granulomas. In general, granulomatous prostatitis accounts for fewer than 1% of benign inflammatory conditions of the prostate. The epidemiologic correlations depend in part on the etiology.

Methods: The study was done on 94 specimens over a period of three years. Sections from each case of histopathologically diagnosed non specific granulomatous prostatitis on hematoxylin and eosin (H & E) were stained with Periodic Acid Schiff (PAS) and Ziehl-Neelsen stain (Z N stain) for acid fast bacilli to confirm infectious granulomatous prostatitis.

Results: Out of total 94 cases, 11 cases (11.70%) of NSGP, 8 cases (8.51%) of prostatic adenocarcinoma, 1 case (1.07%) of prostatic abscess, 1 case (1.07%) of prostatic TB and 63 cases (67.01%) of BPH and 10 cases (10.64%) of BPH with chronic prostatitis were observed. All the cases (11.70%) of non specific granulomatous prostatitis shows raised PSA level and clinically they were diagnosed as carcinoma prostate in 9 cases and 2 cases as benign prostatic hyperplasia with marginally elevated PSA level. None of these were suspected as granulomatous prostatitis on clinical basis.

Conclusion: Distinction between non specific and infectious granulomatous prostatitis is important for therapeutic reasons to reduce the unnecessary hospital treatment and financial burden on patients as these lesions closely mimic prostatic carcinoma. Moreover there is no specific pattern of clinical, biochemical and ultrasound findings that allows the diagnosis of granulomatous prostatitis or differentiates it from prostatic carcinoma. Hence, histomorphological diagnosis is gold standard in differentiating various prostatic lesions.

**Keywords:** Ca prostate, Tuberculosis, PSA, TURP, Prostatitis.

---

Date of Submission: 16-11-2017

Date of acceptance: 02-12-2017

---

## I. Introduction

Granulomatous prostatitis accounts for 0.8 – 1% of benign inflammatory conditions of the prostate [1]. It is subclassified as infectious granulomas, non specific Granulomatous prostatitis, post biopsy granulomas and systemic granulomatous prostatitis [2]. The lesion consists of a lobular dense infiltrate of lymphocytes, plasma cells and histiocytes. Non specific granulomatous prostatitis and xanthogranulomatous prostatitis may occur in the transition and peripheral zones, whereas post biopsy granulomatous prostatitis occurs around the resection site and along the biopsy tract. The granulomas in systemic granulomatous conditions may be centered on blood vessels [3]. Infectious granulomatous prostatitis caused by fungal organisms usually occurs in immunocompromised patients with disseminated mycoses [2]. Prostate tuberculosis is much less common than renal, vesiculo-seminal and epididymal tuberculosis. Thus many urologists are unfamiliar with the diagnosis and management of prostatic tuberculosis with many cases found incidentally following transurethral resection [4]. The possible modes of involvement include a descending infection from the urinary organs, direct

intracanalicular extension from a neighbouring tuberculous focus in the genital tract or a hematogenous spread. On the basis of clinical observations and animal experiments, Sporer et al.[5] suggested that tuberculosis of the prostate is almost always the result of one or perhaps successive hematogenous seedings. Direct extension may occur; however, descending infection of the prostate has never been encountered.[5] It is well established that the predisposing factors associated with the development of tuberculosis include prolonged steroid use, immunosuppressive therapy, diseases that impair cell mediated immunity, and diseases with poor immune mechanisms.[4] Tuberculosis of the prostate gland presents with diffuse caseating epithelioid cell granulomas which are not confined to the periglandular/periductal region, as seen in cases of nonspecific granulomatous prostatitis. Other infectious agents, such as treponema pallidum, viruses[6] and various fungi[7], are rare causes of granulomatous prostatitis. Histochemical stains like PAS, Gomori's stain and Ziehl Nielsen stain are helpful in confirming infectious etiology. In most cases the cause of granulomatous prostatitis is unknown[8], but granulomatous prostatitis can occur after various predisposing/precipitating events, e.g. urinary tract infections (71%)[9], transurethral resection of prostate/open prostatectomy[10] and needle biopsy[11]. Recently, a higher incidence of granulomatous prostatitis was found in patients who had been treated with intravesical bacilli Calmette–Guerin[12-14]. Nonspecific granulomatous prostatitis is usually an incidental finding, with an incidence of <3.4% in unselected series of patients[15]; it is detected in 0.44% of routine prostatectomy specimens and in 0.29[10] to 3.3%[16] of needle prostate biopsies. It is important to differentiate non specific granulomatous prostatitis from specific granulomatous prostatitis, as this type is a self limiting benign condition, while the latter requires specific treatment[17].

Non specific granulomatous prostatitis accounts for most cases of granulomatous prostatitis (upto 69%) [18]. In most laboratories, a serum PSA level of 4ng/ml is the cutoff between normal and abnormal, although some guidelines designate values above 2.5 ng/ml as abnormal. One limitation of PSA is that while it is organ-specific, it is not cancer-specific. BPH, prostatitis, prostatic infarcts, instrumentation of the prostate, and ejaculation also increase serum PSA levels. Conversely, 20 to 40% of patients with organ-confined prostate cancer have a PSA value of 4.0 ng/ml or less. PSA present in the serum is mostly bound to plasma proteins but also includes a minor free fraction. The percentage of free PSA (the ratio of free PSA to total PSA) is lower in men with prostate cancer than in men with benign prostatic diseases.[19] Granulomatous prostatitis may cause a relatively mild and transient increase in serum PSA level which resolves when the inflammation subsides. The clinical triad of high fever, symptoms of prostatitis, and a hard prostate on palpation is present in one fifth of cases and suggest the diagnosis.

A preoperative diagnosis of carcinoma is made in about 30% of cases because of the firmness of the lesion, caused by dense fibrosis [20]. The microscopic changes can simulate carcinoma in needle biopsy specimens [21]. The major significance of this lesion is that the rectal examination in nonspecific granulomatous prostatitis commonly reveals nodularity or induration and serum PSA levels may be elevated such that carcinoma of the prostate is often suspected [22]. Hence histopathology remains the gold standard method for diagnosis of granulomatous prostatitis.

The aim of this study was to highlight the significance of uncommonly encountered inflammatory lesion non specific granulomatous prostatitis on histopathological examination encountered on TURP specimens and its association with PSA level as it mimics prostate cancer clinically, biochemically, ultrasonographically and radiologically.

## **II. Material And Methods**

This study was done over a period of three years (2015 – 2017) on 94 specimens all types of prostatic specimens including TURP and needle biopsies were considered in this study. Inadequate biopsies and poorly preserved prostatic specimens were excluded. The cases with histopathological diagnosis of non specific granulomatous prostatitis were retrieved. The data comprises of patients age, presenting complaints, digital rectal examination findings and biochemical findings like PSA levels. Entire prostatic chips were processed which was received and processed on fully automatic tissue processor. Sections from each case of histopathologically diagnosed non specific granulomatous prostatitis on hematoxylin and eosin (H & E) were stained with Periodic Acid Schiff (PAS) and Ziehl Neelsen stain (Z N stain) for acid fast bacilli to confirm infectious granulomatous prostatitis. The H & E special stains were done as per the procedure described by John D Bancroft [23].

### III.Results

This study was done on 94 specimens received for histopathological examination, out of which 83 were TURP 91.49% and 11 were trucut prostatic biopsies (8.51%). There was no history of previous prostatic surgery in any of the cases. Age of patients ranged from 23 to 85 with a mean of (50 – 85) years. The young age of patient (23 years) was only in one case of prostatic abscess. Most frequent symptoms were lower urinary tract symptoms (LUTS), increases in frequency of micturition. One DRE, the prostate was hard, enlarged and nodular with grade I – III. In no case granulomatousprostatitis was mentioned as a possible diagnosis. In the present study 11 cases(11.70%) out of 94 cases of non specific granulomatousprostatitis were observed, 8 cases (8.51%) of prostatic adenocarcinoma, 1 case (1.07%) of prostatic abscess, 1 case (1.07%) of prostatic tuberculosis, and 63 cases (67.01%) of benign prostatic hyperplasia were observed and 10 cases(10.64%)of benign prostatic hyperplasiawith chronic prostatitis. Histopathology of 94 cases of prostate on TURP is seen in Table 2. In 11 cases (11.70%) of non specific granulomatousprostatitis, three (3/11) showed giant cells. All the cases shows raised PSA level and clinically they were diagnosed as carcinoma prostate in 9 cases and 2 cases as benign prostatic hyperplasia with marginally elevated PSA level.

DRE revealed grade II – III hard enlarged nodular prostate in 8 cases while 3 cases were unremarkable. PSA levels ranged from 3.3% ng/ml to 30.1 ng/ml with mean PSA levels of 16.3 ng/ml. Correlation of Serum PSA with prostatic lesions diagnosed on TURP is seen in Table 3. TRUS showed hypoechoic shadows in 4 cases and in rest of 7 cases TRUS was unremarkable. None of these were suspected as granulomatousprostatitis on clinical basis. BPH was the most frequent finding seen in 63 (67.01%). Maximum numbers of lesions were seen in age group 61 to 70 yrs (41.49%) with an average age of presentation of 65 years. All prostatic specimens were broadly classified into non neoplastic 86 (91.50%) and neoplastic 8 (8.51%). The age distribution of neoplastic and non neoplastic lesions is shown in Table 1.

**Table No. 1:AgeDistribution OfNeoplastic And Non Neoplastic Lesions (94)**

Age (years)	Non neoplastic n (%)	Neoplasticn (%)
20-30	1 (1.06)	-
31-40	1 (1.06)	-
41-50	7 (7.45)	-
51-60	23 (24.47)	-
61-70	39 (41.49)	3 (3.19)
71-80	13 (13.83)	5 (5.32)
81-90	2 (2.13)	-
Total	86 (91.49)	8 (8.51)

**Table No. 2: Histopathology of 94 cases of prostate on TURP**

Histopathological finding on TURP	No. of cases(94)	Percentage
Benign Prostatic Hyperplasia	63	67.01
BPH with chronic prostatitis	10	10.64
Prostatic abscess	01	1.07
Tubercular prostatitis	01	1.07
Non specific granulomatousprostatitis	11	11.70
Adenocarcinoma prostate	08	8.51

**Table No. 3: Correlation of Serum PSA with prostatic lesions diagnosed on TURP**

S.PSA	BPH	BPH with CP	Prostatic abscess	Tubercular prostatitis	Non specific granulomatousprostatitis	Adenocarcinoma	Total
<4	56	6	-	-	-	-	62
4-10	07	4	-	-	-	-	11
10-20	-	-	-	01	01	-	02
20-30	-	-	-	-	07	-	07
30-40	-	-	01	01	03	-	04
>40	-	-	-	-	-	08	08
Total	63	10	01	01	11	08	94

#### **IV. Discussion**

Granulomatous prostatitis is a distinct clinical and pathological entity, apparently a reaction to extravasated prostatic secretions into the surrounding tissues secondary to obstruction and infection within the prostate. The disease occurs at a slightly earlier age than prostatic carcinoma. NSGP which is characterized by infiltrates of histiocytes and other inflammatory cells along with destruction of the prostate glandular structures can be misdiagnosed as high grade prostate cancer [21] {Figure 1}. In countries where PSA screening is a routine, more than 90 per cent of prostate cancers are being detected as a localized disease and only 4 per cent of prostate cancers present in metastatic stage [24]. There is no PSA level below which a man can be informed that prostate cancer does not exist. Rather, the risk of prostate cancer and that of high grade disease, is continuous as PSA increases [25]. Non specific granulomatous prostatitis mimics prostate carcinoma on rectal examination and ultrasonography and can result in an elevated serum PSA level.

Serum PSA level in NSGP is often in the range of 20-30 ng/ml with PSA > 4ng/ml seen in the majority of NSGP when granulomatous and chronic inflammation is florid and diffuse, prostate ducts may not be appreciated and therefore, it may raise the suspicion for a high – grade, Gleason pattern 5 carcinoma. The association of NSGP and adenocarcinoma is not surprising, as prostatic adenocarcinoma is prevalent in middle-aged and elderly men. A panel of Immunohistochemical tests can reliably distinguish between these conditions. It is important to make this distinction as the prognosis of NSGP is excellent, with most cases resolving spontaneously, although some will require local therapy, symptomatic or specific therapy. The problem is often amplified if poor preservation or mechanical artifacts elevated with granulomatous prostatitis but normal levels have also been reported [26]. The patients PSA level is usually elevated with granulomatous prostatitis but normal levels have also been reported [27]. If granulomatous prostatitis is diagnosed on needle biopsy after referral for a high PSA level and an abnormal prostate on DRE, reports suggest the treatment of granulomatous prostatitis as indicated. This should resolve over a period of months, and the PSA level should return to the normal range for the patient. However, if this does not occur and the prostate still feels abnormal, then a re-biopsy is warranted.

Non Specific Granulomatous Prostatitis is the most prevalent form of granulomatous prostatitis. In a series of cases of granulomatous prostatitis diagnosed by needle biopsy, 77% were reclassified as non – specific [21]. The cause of NSGP has not been established but it has been postulated to be a manifestation of a foreign body response to extravasated prostatic secretions derived from obstructed ducts (28, 29). Serum PSA levels may be mildly to markedly elevated (21, 30) and the transrectal ultrasound pattern may simulate carcinoma (30,31), further raising the index of suspicion for malignancy and necessitating needle biopsy in some cases. NSGP is most commonly seen in men 50 to 69 years old with a range of 18 to 86 years. It is present in 0.5% to 3.4% of prostate specimens and accounts for approximately two thirds of all granulomatous processes of the prostate [32] observed at histological examination.

Granulomatous prostatitis was seen in 11 of 94 cases ( 11.70%). Two of 11 cases showed granulomatous with Langhans's giant cells and small foci of necrosis; however, Ziehl Nelson (20%) staining in this case was negative for AFB and no history of bacillus Calmette-Guerin vaccine instillation could be elicited. Also, the granulomas were seen in close proximity to acini and thus were finally labeled as a non specific type. In one case well defined epithelioid cell granulomas with extensive caseous necrosis was seen {Figure 2}. Positivity for AFB was also seen. In all other cases, non specific granulomas composed of collection of epithelioid cells were present around the ruptured acini.

Tuberculosis of the prostate is usually secondary to tuberculous infection of the upper urinary tract [33-35]. But it can occur primarily or secondarily to tuberculous infection of the epididymis or seminal vesicles [33-35]. Histopathological changes include focal necrosis with caseation and rarely calcification [36]. The prostate gland can become distorted and indurated because of fibrotic change [36].

On clinical examination, a tuberculous prostate gland is normal or small with a localized, painless, irregular surface or hard areas. Urinalysis is normal, and urine culture is negative. Therefore, it is sometimes difficult to differentiate this entity from carcinoma of the prostate when the prostate is hard and nodular on digital rectal examination and the urine is negative for tuberculosis bacilli [37,33,34]. Mycobacterium tuberculosis can be detected in prostatic fluid [4,37,38]. The tuberculin skin test is nearly always positive but cannot be relied on because of the age of the patients. A negative test cannot preclude a diagnosis of mycobacterial infection. The PSA level may be normal or increased [37]. Imaging studies may be helpful in the

diagnosis, but a definitive diagnosis of tuberculous prostatitis must be made by bacteriologic and microscopic examination via transrectal needle biopsy of the prostate. A transrectal ultrasound guided biopsy of the prostate can produce a reliable diagnosis of tuberculosis of the prostate. Tuberculosis of the prostate, though rare, can mimic prostate cancer as well as BPH. A high index of suspicion is therefore needed in order to avoid misdiagnosis particularly those practicing in the developing countries.

## V. Conclusion

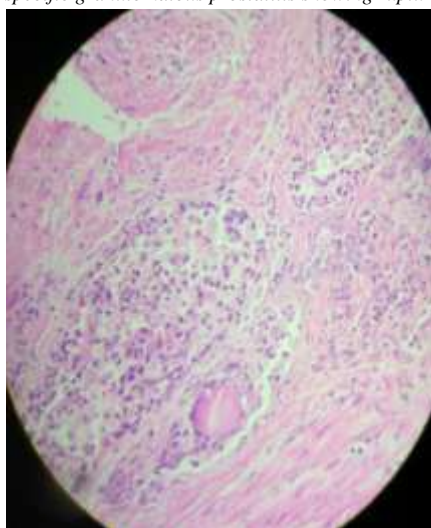
It has to be emphasized that despite being an uncommonly encountered association, all cases of TURP specimens should be thoroughly sampled and studied to reduce the unnecessary hospital treatment and management burden on patients as these lesions closely mimic prostatic carcinoma. Moreover distinction between non specific and infectious granulomatous prostatitis is important for therapeutic reasons. Granulomatous prostatitis may cause a relatively mild and transient increase in serum PSA level which resolves when the inflammation subsides. Non specific granulomatous prostatitis is most common type of granulomatous prostatitis. There is no specific pattern of clinical, biochemical and ultrasound findings that allows the diagnosis of granulomatous prostatitis or differentiates it from prostatic carcinoma. Hence, histomorphological diagnosis is gold standard in differentiating various prostatic lesions.

## References

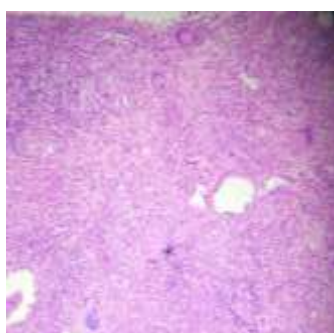
- [1]. Alexander RB, Mann DL, Borkowski AA. et al. Granulomatous prostatitis linked to HLA – DRB 1<sup>0</sup> 1501. J Urol 2004;171:2326-9.
- [2]. Epstein JI, Netto GJ, eds. Biopsy Interpretation of the prostate. 2008. 4<sup>th</sup>ed:
- [3]. Ronald chin – Hong G. Pathology of granulomatous prostatitis. 2015.
- [4]. Gow JG. Genitourinary tuberculosis. In: Walsh PC, Retik AB, Vaughan ED, et al., editors. Campbell's Urology. 7<sup>th</sup>ed. Philadelphia: WB Saunders; 1998. pp. 817-8.
- [5]. Sporer A, Auerback MD. Tuberculosis of the prostate. Urology. 1978;11:362-5.
- [6]. Clason AE, McGeorge A, Garland C, Abel BJ. Urinary retention and granulomatous prostatitis following sacral herpes zoster infection: A report of 2 cases and review of literature. Br J Urol. 1982;54:166-7.
- [7]. Hinchey WW, Someren A. Cryptococcal prostatitis. Am J Clin Pathol. 1981;75:257.
- [8]. Alexander RB, Mann DL, Borkowski AA, Fernandez-Vina M, Klyushnenkova EN, Kodak J, et al. Granulomatous prostatitis linked to HLA-DRB1\*1501. J Urol. 2004;171:2326-9.
- [9]. Stillwell TJ, Engen DE, Farrow GM. The clinical spectrum of granulomatous prostatitis: A report of 200 cases. J Urol. 1987;138:320-3.
- [10]. Val-Bernal JF, Zaldumbide L, Garijo FM, Gonzalez-Vela MC. Nonspecific (idiopathic) granulomatous prostatitis associated with low-grade prostatic adenocarcinoma. Ann Diagn Pathol. 2004;8:242-6.
- [11]. Bahnsen RR. Elevation of prostate specific antigen from bacillus Calmette Guerin-induced granulomatous prostatitis. J Urol. 1991;146:1368-9.
- [12]. Lamm DL, Stogdill VD, Stogdill BJ, Crispen RG. Complications of bacillus Calmette-Guerin immunotherapy in 1,278 patients with bladder cancer. J Urol. 1986;135:272-4.
- [13]. Oates RD, Stilman MM, Freedlund MC, Siroky MB. Granulomatous prostatitis following bacillus Calmette-Guerin immunotherapy of bladder cancer. J Urol. 1988;140:751-4.
- [14]. Mukamel E, Konieczky M, Engelstein D, Cytron S, Abramovici A, Servadio C. Clinical and pathological findings in prostates following intravesical bacillus Calmette-Guerin instillations. J Urol. 1990;144:1399-400.
- [15]. Sorensen FB, Marcussen N. Non-specific granulomatous prostatitis. Ugeskr Laeger. 1989;151:287-90.
- [16]. Miralles TG, Gosalbez F, Menendez P, Perez-Rodriguez A, Folgueras V, Cabanilles DL. Fine needle aspiration cytology of granulomatous prostatitis. Acta Cytol. 1990;34:57-62.
- [17]. O'Dea MJ, Hunting DB, Greene LF. Non-specific granulomatous prostatitis. J Urol. 1977;118:58-60.
- [18]. Rafique M, Yaqoob N. Xanthogranulomatous prostatitis: a mimic of carcinoma of prostate. World J Surg Oncol. 2006 Jun 5. 4: 30.
- [19]. Kumar V, Abbas AK, Fausto N, editors. Prostate. In: Robbins Pathologic Basis of Disease. 9<sup>th</sup> ed. Philadelphia: Saunders Company.
- [20]. Rosai J. In: Rosai & Ackerman's surgical pathology 10<sup>th</sup> ed. Vol 1. Missouri: Mosby; 2011. Male reproductive system; pp. 1287-1314.
- [21]. Oppenheimer JR, Kahane H, Epstein JI. Granulomatous prostatitis on needle biopsy. Arch Pathol Lab Med 1997, 121: 724-729.
- [22]. Epstein JI. The prostate and seminal vesicles. Sternberg's diagnostic surgical pathology, 2004. 4<sup>th</sup> ed. 45: 2086-87.
- [23]. Bancroft JD. Theory and practice of histology techniques. 6<sup>th</sup> ed. Churchill Livingstone: Elsevier; 2008. The Haematoxylin and Eosin. In: John D. Bancroft's PP. 121-133.
- [24]. Altekruse SF, Kosary C, Krapcho M, Neyman N, Aminou R, Waldron W, et al; editors. SEER cancer statistics review 1975-2007. Bethesda, MD: National Cancer Institute; 2010.
- [25]. Thompson IM, Rauler DK, Goodman PJ et al: Prevalence of prostate cancer among men with a prostate – specific antigen level < 0r = 4.0 ng per milliliter. N Engl J Med 2004;350:2239.
- [26]. Rajal B.S, Ming Z. Prostate Biopsy Interpretation: An illustrated guide. Benign Mimics of prostate carcinoma. 2012; 7:79-111.
- [27]. Clements R, Thomas KG, Griffiths GJ, Peeling WB. Transrectal ultrasound appearances of granulomatous prostatitis. Clin Radiol 1993;47:174-7.
- [28]. Schmidt JD. Non specific granulomatous prostatitis: classification, review and report of cases. J Urol 1965; 94: 607-615.

- [29]. O' Dea MJ, Hunting DB, Greene LF. Non specific granulomatousprostatitis. J Urol 1977; 118: 58-60.
- [30]. Speights VO Jr, Brawn PN. Serum prostate specific antigen levels in non specific granulomatousprostatitis. Br. J Urol 1996;77: 408-410.
- [31]. Bude R, BreeRI, Adler RS, Jafri SZ, Transrectal ultrasound appearance of granulomatousprostatitis. J Uetransound Med 1990; 9: 677-680.
- [32]. Ming Z, George N, Jonathan E. Uropathology :High yield pathology. Non neoplastic disease of prostate. 2012. 1-49.
- [33]. Ney C,FriedenbergRM.Theprostate.Radiographic atlas of the genitourinary system.Philadelphia:JB Lippincott, 1981:1553-607.
- [34]. Wang JH,ChangT.Tuberculosis of the prostate:CTappearance.J Comp Assist Tomogr 1991;15:269-70.
- [35]. Wang JH,SheuMH,LeeRC.Tuberculosis of the prostate:MRappearance.J Comp Assist Tomogr 1997;21:639-40.
- [36]. AuerbachO.Pathology of urogenitaltuberculosis.New Intern Clin 1940;3:21.
- [37]. KostakopoulosA,EconomouG,PicrameosD,MacrichoritisC,TekerlekisP,KalliakmanisN.Tuberculosis of the prostate.IntUrolNephrol 1998;30:153-7.
- [38]. SporerA,OppenheimerG.Tuberculosis of prostate and seminal vesicles.JUrol 1957;78:278-86.

*Figure1 Photomicrograph of non specific granulomatous prostatitis showing ruptured acini and inflammatory process.*



*Figure 2.tubercular prostatitis showing caseating granuloma along with Langerhans and foreign body giant cells.*



\*Alpana choudhary. “An Analysis f Trends of Incidence And Pathological Study of Non Specific Granulomatous Prostatitis Encountered in Turp Specimens And Its Correlation with Serum Psa Levels.” IOSR Journal of Dental and Medical Sciences (IOSR-JDMS) , vol. 16, no. 08, 2017, pp. 122-127