

Surgical Management of Paediatric Humerus Fractures with Tens - A Retrospective Analysis.

¹Dr. Raja Ramesh Badavath, ²Dr. P.A. Shraavan Kumar
^{1,2}Assistant Professor, Department of Orthopaedics, NIMS hospital, Hyderabad.
Corresponding Author : Dr P.A. Shraavan Kumar

Abstract: Controversy persists regarding surgical management of long bone injuries in the age between 6 to 16 years. Titanium elastic nail (TEN) fixation was originally meant as an ideal treatment method for femoral fractures, but was gradually applied to other long bone fractures in children, as it represents a compromise between conservative and surgical therapeutic approaches with satisfactory results and minimal complications. The present study is a retrospective analysis of 34 children who were operated for humerus diaphyseal injuries with TENS system. Results were analysed and discussed in the study. Results favoured operative management of diaphyseal injuries of humerus in children aged 6-15 years with TENS, for early mobilisation, ease of care of injured extremity and for its advantages with no major complications and technical ease of surgery, and also minimal damage to tissues in view of it being a closed percutaneous method.

Date of Submission: 30-10-2017

Date of acceptance: 28-11-2017

I. Introduction

In the last two decades there was an increased interest in the operative treatment of paediatric fractures, although debate persisted over its indications. There is a little disagreement concerning the treatment of long bone fractures in children less than 6 years (POP cast) and adolescents older than 16 years (locked intramedullary nailing). Controversy persists regarding the age between 6 to 16 years. Titanium elastic nail (TEN) fixation was originally meant as an ideal treatment method for femoral fractures, but was gradually applied to other long bone fractures in children, as it represents a compromise between conservative and surgical therapeutic approaches with satisfactory results and minimal complications. Over the past 20 years, paediatric orthopaedists have tried a variety of methods to treat paediatric long bone fractures to avoid prolonged immobilisation and complications. Ender's nail stainless steel implants that proved to be inadequate for adult femoral and tibial fractures but may be effective for paediatric fractures although they may not be elastic enough as their modulus of elasticity is higher than titanium nails. In the contrary, TENS are more elastic, thus limiting the amount of permanent deformation during nail insertion; they promote healing by limiting stress shielding in addition to their biocompatibility without metal sensitivity reactions. In the present study, we have retrospectively evaluated humeral diaphyseal fractures treated by TENS in paediatric population at our institute.

II. Methodology

All the paediatric humerus diaphyseal fractures of children aged 6-14 years and operated with TENS (Titanium Elastic Nailing System) at our institute from 2012-2016 were included in the study. Compound fractures, Infective non unions, children with Osteogenesis Imperfecta were excluded from the study. A standard surgical technique as described underneath was followed in operating these fractures.

Surgical technique :

When retrograde insertion was done, a longitudinal incision is made laterally at the level of the lateral epicondyle. The cortex is opened with a 3.2- or 4.5-mm drill bit, depending on the size of the implant desired, and the drill is advanced under image intensification through the lateral column of the distal humerus into the medullary canal. The size of the implant is selected to be approximately 40% of the diameter of the canal, and two equally sized implants should be used to prevent asymmetric force on opposite cortices. The nail is prebent and driven to the fracture site, reduction is then obtained in a closed or open manner, and the implant is subsequently driven proximally to stabilize the fracture. A second small incision is then made over the medial epicondyle. This is extended adequately to both visualize and protect the ulnar nerve or to allow blunt dissection down to the medial epicondyle with a hemostat to assure that the ulnar nerve is not within the operative field. Again, a 3.2- or 4.5-mm drill is used to open the cortex and drill through the medial column into the medullary canal. A second nail is then selected, prebent and advanced to the fracture site, advanced across the fracture site,

and impacted into the proximal humerus. The nails are driven proximally to within 1–2 cm of the proximal humeral physis, cut as close as possible to the insertion site, and impacted into place. Alternatively, both retrograde implants can be inserted through the lateral cortex to decrease risk of injury to the ulnar nerve³.

When antegrade insertion is indicated, both the insertion points are located laterally and distal to the insertion of the deltoid muscle because of presence of neurovascular bundle on medial side. We got C-S construct instead of C-C (double C) construct⁴. A more distal entry point could cause injury to the radial nerve. The nail insertion points are separated from each other vertically by 1.5 – 2.5 cm and horizontally by 0.5 – 1 cm (Fig 1). The cortex is entered using a 3.2- or 4.5-mm drill bit and the opening subsequently enlarged using a clamp. A single flexible nail is inserted into the bone and passed into the distal fracture fragment as far as possible into the supracondylar area. The procedure is repeated to add a second implant. A small portion of the nail is left out of the cortex proximally to facilitate removal

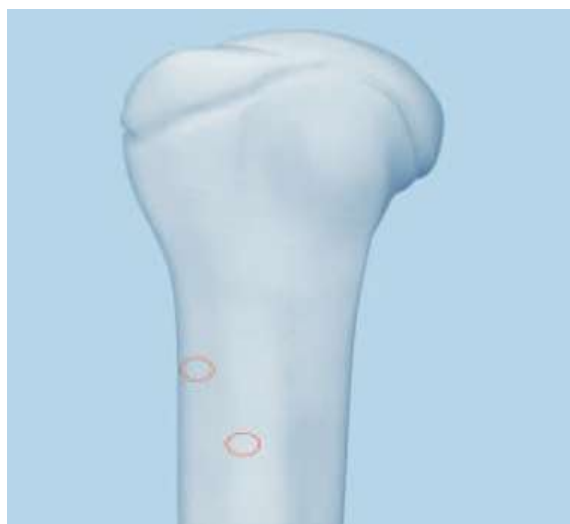


Figure-1: Entry Point For Antegrade Tens Nailing Of Humerus

Postoperative care:

In patients with an ipsilateral radius or ulna fracture, the forearm fracture was stabilized with either Kirschner wire fixation or titanium flexible nails and placed into a posterior elbow splint. Patients without ipsilateral upper extremity fracture were either splinted or placed into a soft dressing and given a sling for comfort for 10–14 days. Suture removal done at 2 weeks. gentle mobilisation exercises started at 2 weeks.

Radiographs were typically obtained 2 weeks postoperatively to check for loss of reduction and at 6, 12 and 24 weeks postoperatively to evaluate healing^{5,6}.

The final outcome based on the above observations is done as per Flynn’s criteria. Flynn’s criteria^{2,7,8}.

TENS outcome score (Flynn et al)

RESULTS	Excellent	Satisfactory	Poor
VARIABLES at 24 weeks			
Limb-length inequality	< 1.0 cm	< 2.0 cm	> 2.0 cm
Malalignment	5 degrees	10 degrees	>10 degrees
Unresolved pain	Absent	Absent	Present
Other complications	None	Minor and	Major and

Interpretation of Results as per Flynn’s criteria :

Excellent: when there was anatomical or near anatomical alignment, no leg length discrepancy with no preoperative problems.

Satisfactory: when there was acceptable alignment and leg length with resolution of preoperative problems.

Poor : in the presence of unacceptable alignment or leg length with unresolved preoperative problems.

All the children were regularly followed up to 6 months on OPD basis for evaluation of Clinical and radiological outcome. Results were analysed and discussed.

III. Results

A total of 34 paediatric humerus diaphysial fractures treated by TENS at our institute and who were followed for not less than 6 months were included in the study. All the children had their implant removed at an average duration of 7.4 months (5-10 Months). Average age of the study group was 10.4 years (5 - 14 : Range). Boys were more in number than girls (Boys n= 21, Girls N= 13). Mode of injury in the study group is tabulated in Table no 1.

Table 1: Mode of Injury in the study population :

Mode of injury	Number of Children	%
RTA	20	58.8
Self fall	11	32.3
Fall from height	3	8.8
Total	34	100.0

Transverse pattern of fracture was commonly noted followed by oblique and comminuted. Segmental fractures of humerus was not noted in our study group. Pattern of fracture in the group is tabulated in Table 2.

Pattern of fracture	Number of Children
Transverse	12
Oblique	9
Spiral	5
Segmental	0
Comminuted	8
Total	34

Table 2 : Pattern of fracture in study population.

11 patients underwent open reduction after attempts of CRIF. 100 % union rate was noted. average time of union being 13.1 weeks (Range 11-21 weeks). Comminuted fractures healed faster. One case of transverse fracture healed slowest at 21 weeks of time. None of the cases needed bone grafting as a primary or secondary procedure. There was no significant relation of ORIF vs CRIF in terms of fracture healing in the study.

Time for union	Number of patients
< / = 12 weeks	28
>12 - 18 weeks	5
>18 - 24 weeks	1
Total	34

Table 3 : Time to Union

Evaluation of outcome by Flynn's criteria is tabulated as follows.

Table 3 : Range of movements at 24 weeks(degrees)

Range of movements(degrees)	Number of patients	%
Full range	31	91
Mild restriction	2	6
Moderate restriction	1	3
Severe restriction	0	0
Total	34	100

Outcome	Number of patients (n=34)	%
Excellent	25	73.5
Satisfactory	9	26.5
Poor	0	0.0

Table 4 : Results of study group.

73.5 % of the patients had excellent outcome at the time of last follow up at 6 months time. None of them had poor outcome. There were no major complications in terms of nonunion, Malunion (Varus, Valgus angulation > 15 degrees, and Rotational alignment >5 degrees) in any of the patient. No patient had any iatrogenic neurological injury. One child had superficial infection at surgical site that resolved after 10 days of suture removal with antibiotics given as per culture of discharge. One patient had moderate restriction of movement of elbow. This patient had prolonged immobilisation with POP and also had delayed healing comparative to other cases.

Discussion

Children with traumatic humeral shaft fractures require operative treatment in cases where surgical stabilization of humeral shaft fractures is required to assist with patient mobilization, wound care, or the maintenance of adequate alignment. The surgical technique of stabilizing humeral shaft fractures with titanium elastic nails is straightforward and can be performed in either a retrograde or antegrade manner. Establishing an antegrade entry is perhaps more straightforward; however, this approach requires that the rotator cuff be incised in line with its fibers. Retrograde entry is our current preference, although it also requires careful opening of the cortex to avoid iatrogenic distal humeral fracture and careful dissection to avoid iatrogenic nerve injury. Antegrade entry is used when severe soft tissue trauma about the elbow contraindicates an entry point at the medial or lateral epicondyle.




Fig 2 : Case Profile : 1) Pre op X ray with transverse humerus diaphyseal fracture. 2) immediate post op X ray. 3) 2 weeks Follow up X ray. 4) 3 months follow up X ray showing callus . 5) X ray after implant removal and complete healing of bone. 6) Functional outcome of child.

The results presented here demonstrate that flexible nails provide the stability required to allow for timely fracture healing in children with traumatic humeral shaft fractures. Most of the children of our patient cohort have returned to full activity. All fractures healed without delay or malunion. Treating surgeons must be

vigilant and regular in carrying out follow-ups to ensure that the nails remain in an adequate position throughout the healing period. Any child with evidence of nail migration and especially impending skin breakthrough should return to the operating room for revision of fixation or trimming of the implants. After healing, the removal of implants need not be done routinely; however, most patients complain of pain and tenderness over the tip of nails which would be the primary reason for implant removal.

IV. Conclusion

Titanium elastic nail fixation is an ideal procedure for treating humeral shaft fractures in which stabilization is indicated as it provides stable fixation, with minimal soft tissue stripping at the fracture site, and allows early mobilization of the extremity. The development of the TEN sfixation method has putanend to criticism of the surgical treatment of paediatriclong bone fractures ,asitavoid sanygrowth disturbance by preserving the epiphyseal growth plate, it avoids bone damage or weak ening through thee lasticity of the construct,which provid esaload sharing, biocompatible internal splint, and finally it entails a minimal risk of bone infection.

References

- [1]. MetaizeauJP.Stableelasticnailingforfracturesofthefemurinchildren.JBoneJoint
- [2]. Surg Br 2004;86:954-957
- [3]. GamalElAdl,MohamedF.Mostafa,MohamedA.Khalil,AhmedEnan.Titaniumelasticnailfixationforpaediatricfemoralandtibialfractures ActaOrthop.Belg2009; 75: 512-520
- [4]. Garg S, Matthew BD, Perry LS, Scott JL, Gordon JE. Surgical treatment of traumatic pediatric humeral diaphyseal fractures with titanium elastic nails. J Child Orthop 2009 April; 3(2): 121–127.
- [5]. Hosalkar HS, Nirav KP, Robert HC, Glaser DA, Morr MA, Herman MJ. Intramedullary Nailing of Pediatric Femoral Shaft Fracture; J Am Acad Orthop Surg August 2011; 19:472-481.
- [6]. Sink EL, Francis F, John P, Katherine F, Jane Gralla. Decreased Complications of Pediatric Femur Fractures With a Change in Management. J Pediatric Orthop 2010 October/November; 30 (7): 633–637. 82
- [7]. Navdeep S, Kanav P, Suhail V, Harish D. Closed reduction and internal fixation of fractures of the shaft of the femur by the Titanium Elastic Nailing System in children. The Internet Journal of Orthopedic Surgery. 2010; 17(1).
- [8]. MorozL,LaunayF,KocherMS,NewtonPO,FrickSL,SponsellerPD,FlynnJM.
- [9]. Titanium elastic nailing of fractures of the femur in children: predictors of complications and poor outcome. J Bone Joint Surg Br 2006; 88:1361-1366
- [10]. FlynnJM,HreskoT,ReynoldsRA,BlaiserRD,DavidsonR,KasserJ.Titanium elasticnailsforpediatricfemurfractures - amulticenterstudyofearlyresultswith analysis of complications. J Pediatr Orthop 2001;21(1):4-8.

*Dr Raja Ramesh Badavath. "Surgical Management of Paediatric Humerus Fractures With Tens - A Retrospective Analysis." IOSR Journal of Dental and Medical Sciences (IOSR-JDMS) 16.11 (2017): 82-86