

Prevalence of Cutaneous Changes in Chronic Renal Failure Patient On Haemodialysis in Tertiary Care Center of Jharkhand.

*Alok Tirkey¹, SoumyaPriyadarshini Tirkey², Umesh Prasad³

¹Senior Resident Dept. of Medicine, Rajendra Institute of Medical Sciences, Ranchi Jharkhand.

²Senior Resident Dept. of Dermatology, Rajendra Institute of Medical Sciences, Ranchi Jharkhand.

³Professor Dept. of Medicine, Rajendra Institute of Medical Sciences, Ranchi Jharkhand.

*Corresponding author: Alok Tirkey

Abstract: Chronic renal failure (CRF) presents with an array of cutaneous manifestations. Cutaneous signs of renal failure are mainly related to chronicity of disease. We evaluated the prevalence of various dermatological manifestations in patients undergoing hemodialysis at least twice a week for minimum of six months at our center. Patients were excluded if they were undergoing hemodialysis less than twice a week or on hemodialysis secondary to ESRD following graft dysfunction. 115 patients were evaluated. Among them, there were 90 male and 25 females. Among the skin changes, pruritus accounted for 53.03%, Xerosis was observed in 49.57%, Diffuse blackish hyper pigmentation was seen in 38.26%. Skin infections was seen in 45.2% of patients. Kyrle's disease was observed only in 5.2%. Nail changes were observed in 38 patients of whom 21 patients had onychomycosis. Discoloration, onycholysis, and splinter hemorrhages were other nail changes seen. Hair changes were observed in 16.2%. Pruritus, xerosis, and pigmentation were higher among skin changes in our study.

Keywords: Chronic Renal Failure, cutaneous changes.

Date of Submission: 14-12-2017

Date of acceptance: 28-12-2017

I. Introduction

Cutaneous signs of renal failure are mainly related to chronicity of disease. Urea frosting, in which crystalline urea is deposited on skin, is now very rare, but dry pigmented skin with excoriation is typical¹. Chronic renal failure is a progressive loss of kidney function over a period of months or years through five stages. The number of patients with end-stage renal disease (ESRD) in India is increasing with an estimated annual incidence of about 100 per million populations². Hemodialysis is one of the therapeutic modalities which can improve the survival in these patients³. About 50–100% of patients with ESRD have at least one associated cutaneous change^{4,5}. Earlier diagnosis and treatment of patients with CRF improves the quality of life and prolongs the life expectancy of these patients, giving time for newer cutaneous manifestations to develop. In a study by Pico *et al.*, all the patients with CRF had one or more skin manifestations⁶, while Bencini *et al.* noticed skin changes in 79% of patients⁷. Our study was conducted to determine the prevalence of cutaneous alterations in CRF patients on hemodialysis.

II. Materials & Method

This study was conducted for 6 months. Patients among 13 years to 70 years were included in this study. Patients undergoing haemodialysis after failure of renal transplant were not included in the study. One hundred and fifteen patients of CRF undergoing hemodialysis were examined for cutaneous manifestations in a tertiary hospital. Patients undergoing regular hemodialysis at least twice a week for a minimum of 12 weeks were evaluated. All patients underwent clinical examination, and relevant investigations were recorded. Dermatological changes were evaluated, confirmed and then recorded. Gram's stain, potassium hydroxide mount and fungal culture were done where indicated, after informed consent. All the data was entered in Microsoft Excel spread sheet. Statistical analysis was done by using Graphpad Prism, version 4, USA. Continuous data was described as arithmetic mean and standard deviation and categorical data as actual numbers and percentages.

III. Results

115 patients were evaluated. Among them, there were 90 male and 25 females. Most of them were in age group 41 to 50 years; the youngest patient was aged 16 years and the oldest 68 years. Serum creatinine was ≥ 5 -7mg/dl in 28 patients, >7 -10mg/dl in 63 and >10 mg/dl in 24 patients. Serum urea was >50 -60mg/dl in 37 patients, >60 -100mg/dl in 65 and >100 in 13 patients. Haemoglobin was < 5 g% in 34 patients, 5.1– 8g% in 69

Prevalence Of Cutaneous Changes In Chronic Renal Failure Patient On Haemodialysis In Tertiary ..

patients and >8g% in 12 patients. The causes of ESRD and cutaneous manifestations were described in Table 1 and 2 respectively. Among cutaneous changes pruritus was recorded in 61 (53.04%) patients, xerosis in 57 patients (49.57%) and diffuse hyperpigmentation in 44 patients (38.26%). 52 patients had infections among these bacterial were in 15, fungal being most common was in 25 patients and viral infection was in 12 patients (figure 3). 38 patients had nail changes, onychomycosis being most common was in 18 patients (figure 4). Other changes seen was onycholysis, discolouration and splinter haemorrhages. Hair changes was seen in 19 patients and mucosal changes in 22 patients. (table 3)

Etiology of chronic renal failure			
cause	male	female	total
DM	50	10	60
HTN	17	8	25
Obstruction	9	3	12
pyelonephritis	4	2	6
others	10	2	12
total	90	25	

Table 1

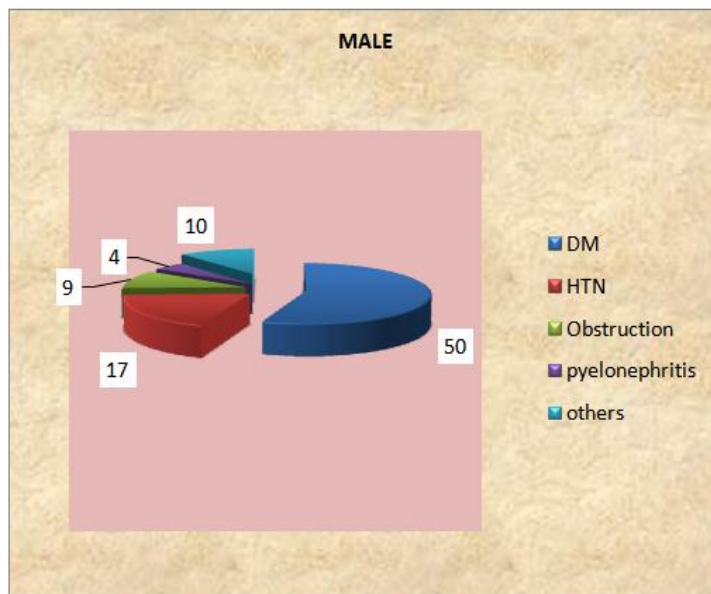


Figure 1

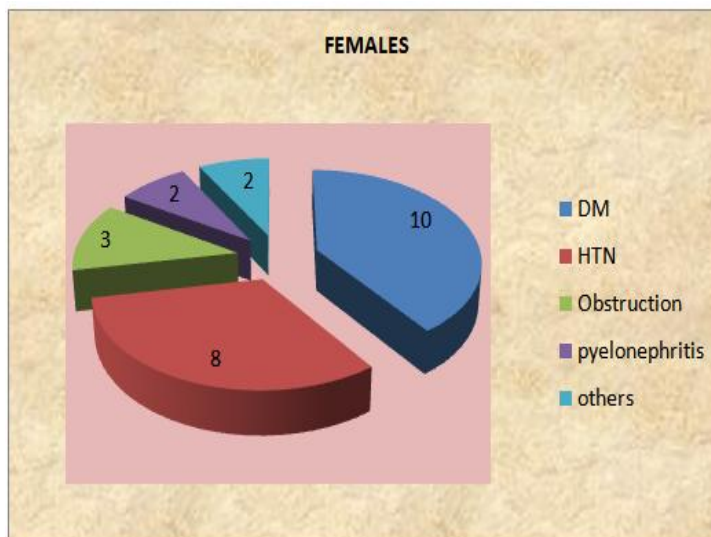


Figure 2

Cutaneous Changes Seen					
Skin Changes	Dm	Htn	Others	Total	%
Pruritus	36	10	15	61	53.03
Xerosis	28	17	12	57	49.57
Hyperpigmentation	25	5	14	44	38.26
Nail Changes	18	8	12	38	33.04
Onychomycosis	11	3	7		
Others	8	5	5		
Hair Changes	10	3	6	19	16.52
Kyrle's Disease	4	0	2	6	5.2
Infections	32	4	16	52	45.2
Bacterial	10	2	4		
Fungal	14	1	10		
Viral	8	1	2		
Mucosal Changes	13	1	8	22	19.13

Table 2

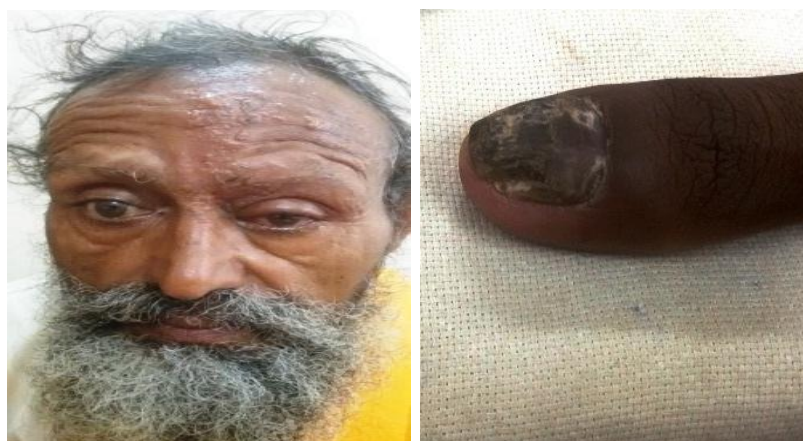

Figure 3 Showing Herpes Zoster Ophthalmicus figure 4 Showing Onychomycosis

IV. Discussion

Pruritus (53.03%) was the most common skin manifestation observed in our patients as compared other studies of Udayakumaret al⁸ but was similar with Praveen et al⁹. Pruritus was found to be common in diabetics. In our study xerosis was found to be the second most common manifestation and was severe in diabetics which were consistent with Kato et al¹⁰. Similar observation was noticed in previous studies with a prevalence of 45–90%¹¹. High dosage of diuretics, reduction in size of sweat glands, and excessive ultrafiltration might be responsible for the above manifestation. Emollients were prescribed to these patients and found to be effective. Diffuse blackish hyperpigmentation was seen in 38.26%, which was relatively high when compared to study of Morton et al who showed hyperpigmentation in 20–22% patients but was consistent with Praveen et al^{9,12}. This is thought to be due to the failure of kidneys to excrete beta-melanocyte stimulating hormone and resultant melanin being deposited in basal layer as well as superficial dermis. Skin infections were comparatively higher in proportion when compared to Udayakumaret al⁸ and Bencini et al¹³. observations. The high incidence of infections (45.2%) might be due to diabetes, low albumin, elevated intracellular calcium, acidosis, or repetitive vascular procedure. Nail changes observed in our study were onychomycosis, discolouration, onycholysis, and splinter hemorrhages. Hair changes were observed with a sparse distribution over body which included dryness and hair discoloration. Dryness (49.57%) was possibly due to decreased sebum secretion. This was high compared to 10–30% in other studies^{14,15}. The reported incidence of oral mucosal changes in hemodialysis patients was 19.13% compared to 90% in previous studies¹⁶. Changes observed in our study were xerostomia, angular cheilitis, gingivitis, and uremic breath. Possible causes include dehydration, mouth breathing, and high concentration of urea, and failure to breakdown into ammonia.

V. Conclusion

In our study, most prevalent cutaneous change was pruritus followed by xerosis, infections and pigmentation. Nail, hair and mucosal changes were less prevalent. To improve quality of life among these patients skin conditions should be early recognized and managed properly.

References

- [1]. Tony Burns, Stephen Breathnach, Neil Cox, Christopher Griffiths, Rooks Textbook Of Dermatology.(Wiley-Blackwell; Hoboken, NJ 2010)
- [2]. Kher V, Madias NE, Harrington JT, et al. End-stage renal disease in developing countries. *Kidney International*. 2002;62(1):350–362. (PubMed)
- [3]. Pastan S, Bailey J. Medical progress: dialysis therapy. *The New England Journal of Medicine*. 1998;338(20):1428–1437. [PubMed]
- [4]. Hajheydari Z, Makhloogh A. Cutaneous and mucosal manifestations in patients on maintenance hemodialysis: a study of 101 patients in Sari, Iran. *Iranian Journal of Kidney Diseases*. 2008;2(2):86–90. [PubMed]
- [5]. Nunley JR. Dermatologic manifestations of renal disease. *eMedicine*. 2002;p. 550.
- [6]. Pico MR, Lugo-Somolinos A. Cutaneous alterations in patients with chronic renal failure. *Int J Dermatol* 1992;31:860-3.
- [7]. Bencini PL, Montagnino G, Citterio A, Graziani G, Crosti C, Ponticelli C. Cutaneous abnormalities in uremic patients. *Nephron* 1985;40:316-21. [PUBMED]
- [8]. Udayakumar P, Balasubramanian S, Ramalingam KS, Lakshmi C, Srinivas CR, Mathew AC. Cutaneous manifestations in patients with chronic renal failure on hemodialysis. *Indian Journal of Dermatology, Venereology and Leprology*. 2006;72(2):119–125. [PubMed]
- [9]. Praveen Kumar KollaMadhavDesaiRam Mohan PathapatiB. MastanValliSuneethaPentyalaG.Cutaneous Manifestations in Patients with Chronic Kidney Disease on Maintenance Hemodialysis Published online 2012 Jul 5. doi: 10.5402/2012/679619.PMCID: PMC3398619
- [10]. Kato A, Hamada M, Maruyama T, Maruyama Y, Hishida A. Pruritus and hydration state of stratum corneum in hemodialysis patients. *American Journal of Nephrology*. 2000;20(6):437–442. [PubMed]
- [11]. Gupta AK, Gupta MA, Cardella CJ, Haberman HF. Cutaneous associations of chronic renal failure and dialysis. *International Journal of Dermatology*. 1986;25(8):498–504. [PubMed]
- [12]. Morton CA, Lafferty M, Hau C, Henderson I, Jones M, Lowe JG. Pruritus and skin hydration during dialysis. *Nephrology Dialysis Transplantation*. 1996;11(10):2031–2036. [PubMed]
- [13]. Bencini PL, Montagnino G, Citterio A. Cutaneous abnormalities in uremic patients. *Nephron*. 1985;40(3):316–321. [PubMed]
- [14]. Tawade YV, Gokhale BB. Dermatological manifestations of chronic renal failure. *Indian Journal of Dermatology, Venereology and Leprology*. 1996;62(3):155–156. [PubMed]
- [15]. Singh G, Singh SJ, Chakrabarty N, Siddharaju KS, Prakash JC. Cutaneous manifestations of chronic renal failure. *Indian Journal of Dermatology, Venereology and Leprology*. 1989;55(3):167–169. (PubMed)
- [16]. Cohen GS. Renal disease. In: Lynch MA, editor. *Burket's Oral Medicine; Diagnosis and Treatment*. 9th edition. Philadelphia, Pa, USA: Lipincott-Raven; 1997. pp. 487–509.

*Alok Tirkey. "Prevalence of Cutaneous Changes in Chronic Renal Failure Patient On Haemodialysis in Tertiary Care Center of Jharkhand." *IOSR Journal of Dental and Medical Sciences (IOSR-JDMS)* 16.12 (2017): 32-35