

## A Unique Case: Solitary Fibrous Tumor of the Mandible

Zanakis N. S<sup>1</sup>, Megas F. V<sup>2</sup>.

<sup>1</sup>Oral And Maxillofacial Surgeon, Department Of Oral And Maxillofacial Surgery, "Hippokraton" General Hospital Of Athens

<sup>2</sup>Otorhinolaryngologist, Private practice

---

**Abstract:** The solitary fibrous tumor (SFT) is a rare soft tissue tumor that most commonly occurs in the pleura cavity. However, it has also been described in other sites of the body. A limited number of SFTs cases have been reported in the soft tissues of the oral cavity. The diagnosis depends on microscopic and immunohistochemical features, although imaging may help. Since this tumor shares a number of similar features with other mesenchymal lesions, the histological diagnosis of SFT may present with difficulties. Close follow-up over several years is recommended due to potential late local recurrence. We present, as we believe, the first case of an endosseous SFT, arising in the mandible.

**Keywords:** Solitary fibrous tumor; Oral cavity; Mandible

---

### I. Introduction

Solitary fibrous tumors (SFTs) were firstly reported in the pleura by Klemperer and Rabin<sup>1</sup> in 1931. These tumors are rare lesions and most commonly arise in the thoracic cavity<sup>2</sup>. Most of them occur as slow-growing painless masses. Rarely, larger tumors may be a source of paraneoplastic syndromes such as hypoglycemia owing to the production of insulin-like growth factor<sup>3,4</sup>. SFT is a mesenchymal neoplasm, previously nomenclatured as localized benign mesothelioma, submesothelioma, or localized fibrous tumor of the pleura<sup>5</sup>. It is now recognized that this may also occurs in extrapleural sites. Recently, however, SFT has been shown to originate from ubiquitous interstitial stem cells in various human tissues and its histopathological criteria have been established by the aid of immunohistochemistry<sup>6</sup>. SFTs arising in the soft tissue of the head and neck account for approximately 10% of all cases<sup>7</sup>. Those occurring in the oral cavity accounts for 3% of all head and neck cases<sup>5</sup>. In the present report we describe the occurrence of a SFT case in the angle region of the mandible. This is the first case report of a SFT arising in the mandible.

### Case report

A 71-year-old Caucasian male patient attended the outpatient department complaining of a swelling in his left lower jaw. The mass was painless and noticed by the patient 5 months ago. Extraoral examination showed a slight fullness of his lower left face. Clinically there was no cervical lymphadenopathy. Hypoaesthesia was evident in the region of distribution of the left inferior alveolar nerve. Intraorally, the lesion, firm in palpation, occupied the mandible from the first molar to the ascending ramus, expanding the buccal and lingual plates. The swelling was covered by healthy mucosa. The Orthopantomogram revealed a diffuse, poorly demarcated endosseous lesion in the region of the left mandibular angle (Fig.1). The computed tomography scan (CT) depicted an endosseous destructive lesion, measured 4.4 x 3.4 cm, causing expansion of the left mandible in all directions, destruction of both plates and lingual extraosseous extension (Fig.2,3). A Fine Needle Aspiration Cytology of the lesion was performed, showing malignant features, yet not specified otherwise. An incisional biopsy followed. The histopathology report indicated either a low grade osteosarcoma or a solitary fibrous tumor with malignant component. The distant metastases work up was negative. The patient under general anesthesia underwent a segmental mandibulectomy via a submandibular approach. The adjacent soft tissues were resected in clinically healthy tissues. The mandible was reconstructive using a 13-hole titanium plate. The postoperative period was uneventful. The patient had been examined regularly on an outpatient basis for one and a half year. At that time there was no clinical evidence of tumor recurrence and a CT scan was negative for findings. Unfortunately, thereafter the patient failed to attend the outpatient clinic.

### Histological findings

The tumor consisted of spindle cells arranged in fascicles, short whorls or diffusely. The cells demonstrate moderate atypia and the mitotic range was 4 mitoses / 10 high power fields. In some areas the cells grow around dilated vessels showing a hemangiopericytomatoid pattern. There were no necrotic areas. Additionally, reactive bone production was also seen, especially at the periphery of the lesion. The lesion was also infiltrating the pre-existing mandibular bone, expanding into the surrounding tissues. Immunohistochemically the tumor cells showed strong positivity against Vimentin, CD34, CD99 and Bcl-2 (Fig.4).

## **II. Discussion**

SFTs are uncommon spindle cell neoplasms of mesenchymal origin<sup>8</sup>. Over 50% of these tumors are located in the thoracic cavity, but extrathoracic tumors have been reported in many sites including the liver, adrenal gland, skin, head and neck etc<sup>2</sup>. In the head and neck, the most commonly affected site is the oral cavity. The most prevalent site is the buccal mucosa followed by the tongue and the lower lip<sup>5</sup>. Cases have been also documented in the orbit, nose and paranasal sinuses, parapharyngeal space, larynx, major salivary glands and thyroid gland. The association of SFTs with the oral cavity, particularly the buccal mucosa, has led to the suggestion that SFT may be associated with trauma<sup>9</sup>. The histopathogenesis of SFT is still controversial. Recent studies have indicated a mesenchymal origin rather than a mesothelial one, which was originally postulated<sup>2,10</sup>. If SFTs originate from immature mesenchymal cells with pluripotential differentiation, they can arise in any mesenchymal tissue of the body including the oral cavity<sup>10</sup>. SFT originating in bone and especially in the mandible has not been previously documented. To our knowledge, this is the first case of SFT arising in the mandible as an intraosseous lesion and spreading to the surrounding tissue, published in the English language literature. On CT the main characteristics were the osteolysis and the extension to the adjacent tissues. The spreading pattern clearly indicates that the tumor was originally located within the mandible. Although such kind of tumors may present with other systemic symptoms, some cases are incidental radiological findings<sup>11</sup>. There are no absolute distinctive diagnostic imaging features. Certain radiographic characteristics may be suggestive and should alert the inclusion of the SFT in the differential diagnosis. The most prominent feature of SFTs on CT and MRI, is that of a well-defined, isodense densely enhancing lesion<sup>9</sup>. Regressive remodeling of adjacent bone is the most common radiographic osseous finding, since most SFTs are benign and slow growing lesions. Nevertheless, the presence of obvious bone destruction is generally associated with more aggressive tumors and the possibility of malignancy should be considered, although this is not always the case<sup>9</sup>. It has been reported<sup>12</sup> that diagnosis can be aided by fine-needle aspiration cytology. This is not supported by the literature and certainly does not apply in the case under discussion. As SFTs, hemangiopericytomas also stain positive for CD34. Some authors<sup>8,13</sup> report that the presence of a basement membrane in hemangiopericytomas also allows them to be distinguished from SFTs. However, it is now generally accepted that the determination of hemangiopericytomas as a separate entity from SFTs may become obsolete because of their histopathologic features, which highly resemble cellular areas of SFTs<sup>14</sup>.

The fourth edition of the WHO Classification of Tumours of Soft Tissue and Bone, published in 2013, classifies SFT and malignant SFT, as intermediate (rarely metastasizing) lesions. The term hemangiopericytoma is abandoned, used only to describe pattern of morphology<sup>15</sup>. The clinical and histological diagnosis of an SFT may present difficulties in distinguishing this entity from other spindle-cell tumors. Immunohistochemistry helps in the distinction of SFTs from other soft tissue sarcomas including synovial sarcoma, benign fibrous histiocytoma, dermatofibrosarcoma protuberans, myofibroma, fibroma, and neurogenic tumors<sup>9</sup>. CD34 is a marker for healthy endothelium and has been found to stain primitive mesenchymal stromal cells and several mesenchymal tumors. All malignant SFTs and 77% of benign SFTs stained positive for CD34 in one study<sup>16</sup>. Therefore, the expression of conventional immunohistochemical markers such as vimentin, CD34, and CD99 might be important in the differential diagnosis of SFT from other spindle cell neoplasms. The absence of S-100 protein is essential for ruling out myogenic, peripheral nerve sheath, fibroblastic and fibrohistiocytic neoplasms with spindle cell features<sup>5,6,17</sup>. An estimated 5% to 20% of thoracic SFTs may have malignant features. On the other hand, malignant extrathoracic tumors are rare. The diagnosis of malignancy is based on both clinical features and histologic findings<sup>9</sup>. Surgery is recognized as the treatment of choice. The majority of SFTs are considered to be benign tumors; and the recommended management is complete surgical resection. In cases of positive resection margins patients should receive adjuvant radiation therapy<sup>9</sup>. Factors that predispose to local recurrence in non-head and neck SFTs, are tumor diameter larger than 10 cm, presence of a malignant component, and positive surgical margins<sup>2</sup>. Other authors also reported that the most important prognostic factor was resectability<sup>3</sup>. In head and neck tumors, the high rate of positive margins reflects more likely the tumor location rather than its biologic features<sup>3,18</sup>. Previous reports note that 13–37% of SFTs were associated with local recurrence or histological malignancy. A tumor recurrence has been described 31 years after surgical excision. Therefore, long-term follow-up is necessary even in cases with findings suggestive of benignity<sup>3,11</sup>.

## **III. Conclusion**

Solitary fibrous tumors of the head and neck region are extremely rare. The characteristic features of these tumors seen on CT or MRI, in conjunction with a benign slow-growing clinical behavior, may help in the diagnosis. Definitive diagnosis is usually made only after tumor resection. These tumors can be surgically excised, and patients who undergo complete surgical resection and do not have any malignant component, can expect a favorable outcome. However, patients with positive surgical margins or patients whose tumors have a malignant component may benefit from adjuvant postoperative radiation therapy<sup>9</sup>.

**References**

- [1]. Klemperer P, Rabin C. Primary neoplasms of the pleura: a report of five cases. *Arch Pathol.* 1931;11:385–412.
- [2]. Gold JS, Antonescu CR, Hajdu C et al. Clinicopathologic correlates of solitary fibrous tumors. *Cancer.* 2002;94:1057-1068. doi:10.1002/cncr.10328
- [3]. England DM, Hochholzer L, McCarthy MJ. Localised benign and malignant fibrous tumors of the pleura: a clinicopathologic review of 223 cases. *Am J Surg Pathol.* 1989;13:640-658.
- [4]. Perros P, Simpson J, Innes JA, Teale JD, McKnight JA. Non-islet cell tumour-associated hypoglycaemia: <sup>111</sup>In-octreotide imaging and efficacy of octreotide, growth hormone and glucocorticosteroids. *Clin Endocrinol.* 1996;44:727-731. doi: 10.1046/j.1365-2265.1996.721542.
- [5]. Alawi F, Stratton D, Freedman P. Solitary fibrous tumor of the oral soft tissues: a clinicopathologic and immunohistochemical study of 16 cases. *Am J Surg Pathol.* 2001;25:900–910.
- [6]. Hanau CA, Miettinen M. Solitary fibrous tumor: histological and immunohistochemical spectrum of benign and malignant variants presenting at different sites. *Hum Pathol.* 1995;26:440–449. doi:10.1016/0046-8177(95)90147-7
- [7]. Brunnemann RB, Ro JY, Ordonez NG, Mooney J, El-Naggar AG, Ayala AG. Extrapleural solitary fibrous tumor: a clinicopathologic study of 24 cases. *Mod Pathol.* 1999;12:1034–1042.
- [8]. Enzinger FM, Weiss SW. *Soft Tissue Tumors.* 3rd ed. New York, Mosby: 1995;351-380. doi:10.1078/0344-0338-00334
- [9]. Ganly I, Patel GS, Stambuk EH, Coleman M, Ghossein R, Carlson D, Edgar M., Shah PJ. Solitary fibrous tumors of the head and neck: a clinicopathologic and radiologic review. *Arch Otolaryngol Head Neck Surg.* 2006;132(5):517-525. doi:10.1001/archotol.132.5.517
- [10]. Sawada N, Ishiwata T, Naito Z, Maeda S, Sugisaki Y, Asano G.
- [11]. Immunohistochemical localization of endothelial cell markers in solitary fibrous tumor: *Pathol Int.* 2002;52:769–776. doi: 10.1046/j.1440-1827.2002.t01-1-01423
- [12]. Sato J, Asakura K, Yokoyama Y, Satoh M: Solitary fibrous tumor of the parotid gland extending to the parapharyngeal space. *Eur Arch Otorhinolaryngol* 255 : 18–21,1998.
- [13]. Ali SZ,Hoon V, Hoda S, Heelan R, Zakowski MF. Solitary fibrous tumor: a cytologic-histologic study with clinical, radiologic and immunohistochemical correlations. *Cancer Cytopathology* 1997; 81: 116-121.
- [14]. Enzinger FM, Smith BH. Hemangiopericytoma: an analysis of 106 cases. *Hum Pathol.* 1976;7:61-82. doi:10.1016/S0046-8177(76)80006-8
- [15]. Guillou L, Fletcher JA, Fletcher CDM, Mandahl N: Extrapleural solitary fibrous tumour and hemangiopericytoma. In: Fletcher CDM, Unni KK, Mertens F, eds. *World Health Organization classification of tumours: pathology and genetics of tumours of soft tissue and bone.* 86-90, Lyon, France: IARC Press, 2002.
- [16]. Al Saanna G, Bovée J, Hornick J, Lazar A. A Review of the WHO Classification of Tumours of Soft Tissue and Bone. 4<sup>th</sup> ed. WHO: 2013. <http://sarcomahep.org/reviews/who-classification-sarcomas.html> Date of access: 3/10/2016.
- [17]. Flint A, Weiss SW. CD-34 and keratin expression distinguishes solitary fibrous tumor (fibrous mesothelioma) of the pleura from desmoplastic mesothelioma. *Hum Pathol.* 1995;26:428-431. doi:10.1016/0046-8177(95)90145-0
- [18]. Jordan RCK, Regezi JA. Oral spindle cell neoplasms: a review of 307 cases. *Oral Surg Oral Med Oral Pathol Oral Radiol Endod.* 2003;95(6):717–724.
- [19]. Langman G. Solitary fibrous tumor: A pathological enigma and clinical dilemma. *J Thorac Dis.* 2011;3(2):86–87. doi: 10.3978/j.issn.2072-1439.2011.03.04

**Captions to illustrations**

**Figure1: OPG: osseous lesion of the left angle**

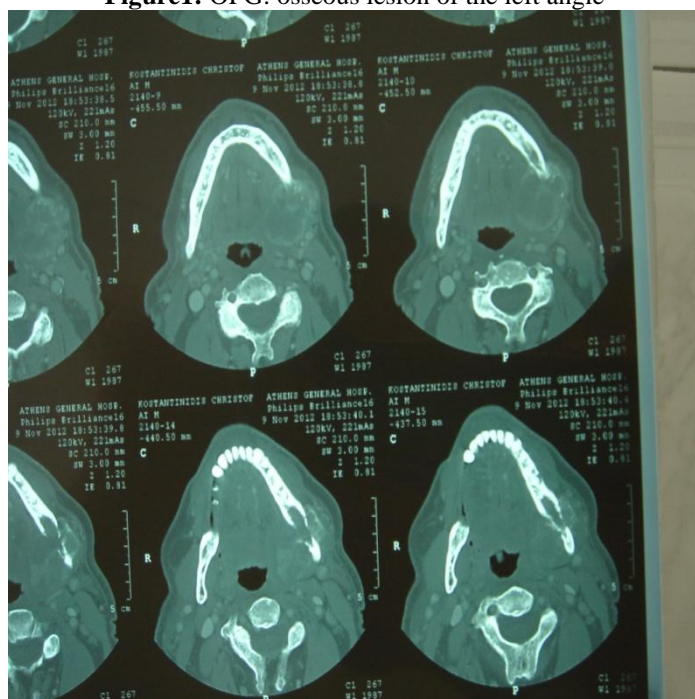


Figure 2: Preoperative CT scan, coronal section

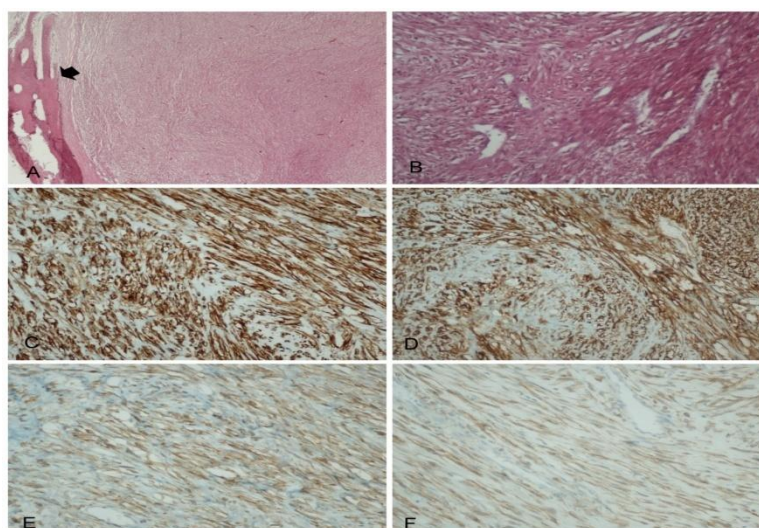
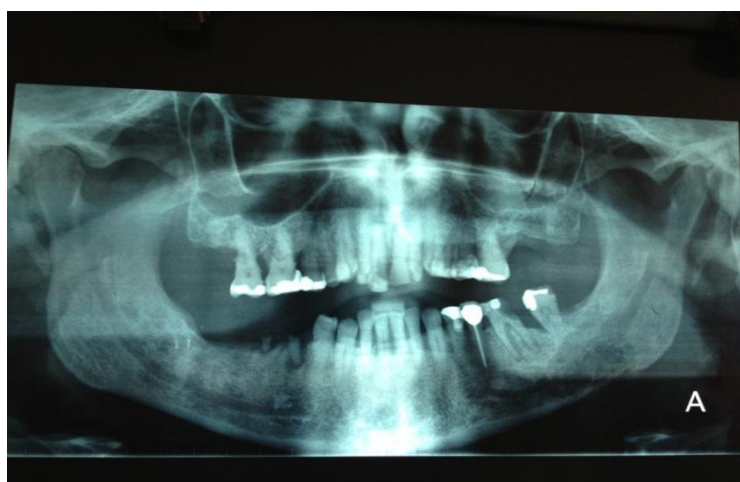
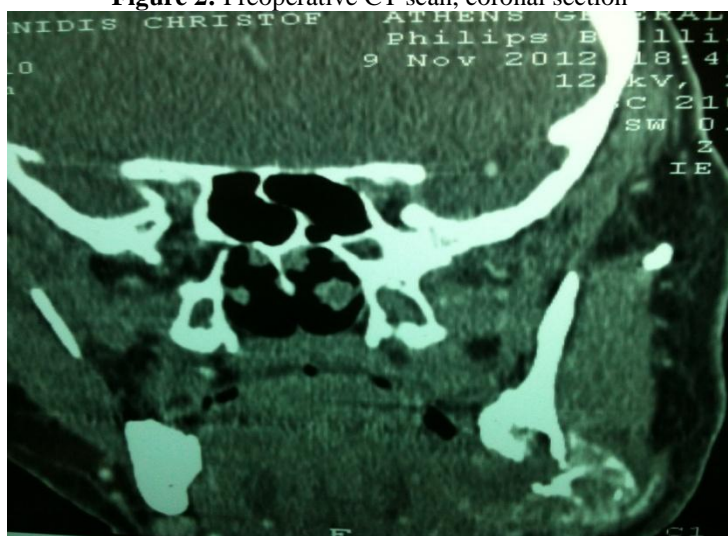


Figure 3: Representative figures, E/H 100X and 200X magnification respectively, immunohistochemistry 200X magnification.

A, hypercellular neoplasm with spindle morphology arranged in fascicular pattern arising within the bone (arrowhead). B, hemangipericytomatoid morphology, moderate nuclear atypia  
C,D,E,F, strong positivity against Vimentin, CD34, CD99, Bcl-2 respectively