

## Advances In The Management of Thyroid Eye Diseases -An Overview

Dr. Rashmi kumara<sup>1</sup>, Dr Bhawesh chandra saha<sup>2</sup>

<sup>1</sup>Chief And Corresponding Contributor Senior Resident, Regional Institute Of Ophthalmology, IGIMS ,PATNA

<sup>2</sup>Senior Resident, AIIMS ,PATNA

**Abstract:** Thyroid eye disease (TED) remains a notorious ailment for both patients and the treating ophthalmologists. Recent years have witnessed considerable research in the immunopathogenic mechanism of TED that has resulted in an expansion and modification of the available management options. Purpose of this review is to summarize the advances in the management of thyroid ophthalmopathy after thorough literature search of the past ten years. Recent VISA classification and new Serum markers seems to have potential to give diagnostic as well as therapeutic guidance ,gauge treatment response and even identify risk for disease progression. Majority of TED patients can be managed conservatively due to its self limiting nature but if indicated, still steroids are the preferable medical therapy, however there is an increasing consensus towards the use of parenteral form as compared to the oral one on account of greater efficacy with lesser side effects. Steroid-sparing medications, for example, rituximab, Infliximab, Etanercept, Adalimumab, Teprotumumab, tocilizumab, tanshinone, and others, are showing encouraging results and forms an area of active research. Radiation therapy remains as an adjunctive modality in active disease as a nonmedical treatment for TED with some promising data. Surgical intervention may be required in vision threatening conditions or to counteract the sequel of inflammatory phase. Advances in surgical techniques like stereotactic image guided balanced orbital decompression with endoscopic approach ensures meticulous dissection with minimal trauma.

**Keywords:** Thyroid ophthalmopathy, Thyroid eye disease, VISA

### I. Introduction

Thyroid eye disease or Grave's orbitopathy is an autoimmune disease characterised by enlargement of the extraocular muscles and increase in fatty or connective tissue volume.<sup>1,2</sup> Although most commonly associated with hyperthyroidism (90%), 6% of the patients are euthyroid , 1% have hypothyroidism and 3% may have Hashimoto's thyroiditis at the time of diagnosis.<sup>3</sup> Approximately 25–50% of patients with Graves' hyperthyroidism have TED. which can be sight-threatening due to dysthyroid optic neuropathy or severe exposure keratopathy in 3–5% of patients.<sup>4</sup> Management of these patients is a virtual challenge for the ophthalmologists as there is no definite treatment algorithm. Recent advances in the immunopathogenic mechanisms are expected to change a bit our existing insights regarding the management of these difficult cases and also has inflated the present treatment options. This review briefly summarizes the recent advances in this field in the past decade .

### Clinical evaluation and Disease quantification

The diagnosis of TED is done clinically with the characteristic clinical picture, restrictive nature of the disease and associated systemic thyroid disease but proper management of TED rests on proper clinical evaluation and staging of the disease on the basis of activity and severity. To evaluate the same many classifications have been proposed the first being the NOSPECS classification proposed by Werner using characteristic ocular signs and symptoms.<sup>5</sup> .With time the classification of TRO evolved to include more objective criteria and guidelines for therapeutic management, notably the clinical activity score (CAS) used by Mourits et al. <sup>6</sup>. For each item in the Table 1, one point is given and the sum of these points is the CAS. It is of high specificity and high positive predictive value and has been found to be of value in predicting the outcome of immunotherapy .Studies have shown that with CAS  $\geq 4$  were more responsive to treatment as compared to patients with CAS  $< 4$  . Discriminating between active and inactive disease is a crucial step in treatment decision making. Activity is the impression of the degree to which the body is reacting to autoantigen .Qualitatively, the disease can be considered inactive, moderately active and severely active. Quantitatively CAS  $> 3/7$  denotes clinically active disease. Severity on the other hand is the physical consequences of activity that persists despite control of activity. The European group on graves orbitopathy (EUGOGO) recommended the following classification of patients with TED/ GO (Graves' Orbitopathy)<sup>7</sup>.

**1.Sight-threatening TED:** Patients with dysthyroid optic neuropathy (DON),subluxation of eyeball,choroidal folds or corneal ulceration. This category warrants immediate intervention.

**2.Moderate to severe TED:** Patients without sight-threatening GO in whom impact of eye disease is severe enough to justify the risks of immunosuppression (if active) or surgical intervention (if inactive). Patients with moderate to severe GO usually have any one or more of the following: lid retraction  $\geq 2$  mm, moderate or severe soft tissue involvement, exophthalmos  $\geq 3$  mm above normal for race and gender, intermittent or constant diplopia.

**3. Mild TED:** Patients whose features of GO have only a minor impact on daily life insufficient to justify immunosuppressive or surgical treatment. They usually only have one or more of the following: minor lid retraction ( $< 3$  mm above normal for race and gender), transient or no diplopia, corneal exposure responsive to lubricants

More recently, Dolman and Rootman have proposed their VISA classification, which classifies TRO by combining the four disease end points: Vision, inflammation, strabismus, and appearance [Table 2] .It allows simultaneous monitoring of disease activity, grading of severity, and appropriate treatment selection.Progression of any VISA parameters indicates active disease.<sup>8</sup>

## II. Investigations

### 1.Blood investigations –serum markers

In addition to the routinely tested serum markers, free T4, T3, and TSH, recent research has focused the pathogenic role of several additional variables that correlate with the disease like autoantibodies against thyrotropin receptor (TRAb) ,Thyroglobulin (TgAb) , thyroid peroxidase (TPOAb) ,thyrotropin receptor (TRAb) ,thyroid stimulating hormone stimulating antibodies (TSHAb) and thyrotropin binding inhibitory immunoglobulins(TBII) . Many newer studies justifies a positive correlation between the prevalence of TED and levels of TSI as stated previously<sup>9</sup>.On the other hand TPOAb and TgAb are negative predictors of chronic lid retraction, lidswelling, proptosis, and extraocular myopathy (Goh et al., in Graves' disease<sup>10,11</sup> . Simultaneous presence of TBII and TSAb is significantly associated with higher activity and severity of disease than the sole presence of TBII without measurable TSAb.<sup>11</sup>

### 2) Imaging modalities

a) Ultrasonography: Can be useful or screening purpose .It demonstrates an increase in thickness of the extraocular muscles.

b) CT scan and MRI:Not indicated routinely but recommended in presence of atypical features<sup>12</sup>

- Unilateral disease
- Strabismus affecting the lateral rectus
- Non-axial globe proptosis,
- Suspected optic neuropathy
- No previous or present evidence of thyroid dysfunction
- Absence of upper eyelid retraction
- Diplopia as sole manifestation/ History of diplopia worsening towards the end of the day.
- Routinely prior to orbital decompression .It demonstrates enlargement of the bellies and sparing of the tendons which helps in assessing the relationship between the optic nerve and muscles at the apex which helps in planning for the surgical intervention if needed.

c) MRI: It again demonstrates fusiform rectus enlargement and orbital fat expansion. It assesses water content in the muscles which correlates with the active inflammation<sup>13,14</sup>

### Management (Fig 1)

**Mild TED:** Patients should be well informed about the self limiting but prolonged course of the disease and kept under observation.<sup>15</sup> Follow up depends upon disease activity during which visual field test and colour vision testing may help in early detection of visual loss.Lubricating drops and ointments or punctal plugs are prescribed for mild ocular surface disorders.Sleeping with head elevation at night reduces morning lid edema. Though not established , normalisation of thyroid levels can be done but cessation of smoking is the strongest modifiable risk factor to prevent congestive orbitopathy and must be recommended.<sup>16</sup>

Recent studies have shown that serum selenoprotein P, an index of the oxidative state is reduced in TED patients hence oral selenium can retard the progression of TED as it an essential component of antioxidant enzymes countereacting the free radical damage in Thyroid orbtopathy. Marcocci et al compared placebo and oral selenite (oral sodium selenite 100 mg twice daily) and found significant improvement in the quality of life, reduced ocular disease, and less risk of disease progression in the treatment group at 6 months.<sup>17</sup>

Inspite of early treatment,15%-25% of the mild cases of TED still shows progression.<sup>18</sup>

## **Moderate to severe TED**

### **Medical management**

#### **1.Corticosteroids**

Mainstay of treatment in moderately active TED is medical mainly corticosteroids either oral,local/intravenous, to diminish and shorten the acute inflammatory phase, rarely it requires surgical treatment.. Till date there is no uniform guideline regarding the optimum dose, dosing intervals or duration of treatment of steroids in TED. In general 500 mg of IV methylprednisolone is given weekly for 6 weeks followed by 250 mg of IV methylprednisolone weekly for 6 more weeks but the total dose of should not exceed eight grams because of significantly increased risk of hepatic failure.<sup>19</sup> Alternatively, oral GC therapy, in the form of prednisone, can be given at 1 mg/kg/day, followed by a prolonged taper of 10 mg/week until a dose of 20 mg/day is reached, then decreased 5 mg every week. Bisphosphonates are recommended especially if duration of GC therapy exceeds 3 months or an average daily dose greater than 5 mg of prednisone is consumed as prolonged oral GC usage causing an increased risk of osteoporosis. Hepatic, cardiovascular or renal morbidity, uncontrolled hypertension, and diabetes are relative contraindications for parenteral steroids otherwise current studies are in favour of i.v steroids as compared to oral owing to the prolonged treatment duration of the later increasing its cumulative side effects lesser efficacy,60% in contrast to 80% with high dose i.v pulse steroids.<sup>20</sup>

Steroid-sparing agents; (Azathioprine,Methotrexate,cyclosporine,Rituximab,Infliximab,Etanercept,Adalimumab, Teprotumumab,tocilizumab, tanshinone,interferon- $\gamma$ )

These are indicated in clinically active disease either alone or as an adjuvant to primary steroids or irradiation therapy.Studies suggests monotherapy with oral cyclosporine is less effective than oral steroids, but their combination is more effective in patient refractory to either drugs as monotherapy. Rituximab ,newer member in this group,is a chimeric mouse monoclonal anti-human CD20 antibody that blocks B-cell proliferation and maturation with established role in treatment of Rheumatoid arthritis and lymphoma.<sup>21</sup> A non-randomised cohort study by Salvi et al, have shown greater improvement in clinical activity after treatment with parenteral Rituximab (1000mg intravenous infusion, twice at two-week interval) with fewer side effects, than those treated with a standard i.v pulse steroids.<sup>22</sup> Another clinical trial compared treatment with two infusions of rituximab infusions with two saline infusions, given 2 weeks apart, in 21 patients with TED and found that there was no significant difference in the improvement of the CAS score or in their secondary endpoints( exophthalmos, lagophthalmos, diplopia, or interpalpebral fissure) in the rituximab group, suggesting no benefit of this treatment.<sup>23</sup> Incidence of progressive multifocal leukoencephalopathy with chronic Rituximab therapy and extremely high cost are other the limiting factors for its liberal use in TED patients<sup>24</sup>

Association of high serum TNF- $\alpha$  levels with severity of TED have paved the use of anti monoclonal antibodies against TNF- $\alpha$  ,Infliximab and Etanercept <sup>25</sup>.Studies shows their rapid action on subsidence of orbital inflammation and improvement in visual function with relatively few side effects.<sup>26,27</sup>

Newer member, Adalimumab which is FDA approved for rheumatoid arthritis, psoriatic arthritis, ankylosing spondylitis, inflammatory bowel disease, in a retrospective review showed significant improvement in the inflammatory composite score.Teprotumumab, an antiIGF-1 receptor human monoclonal antibody approved as an anticancer treatment is under phase 2 clinical trials in patients with active TED. In a recent study fibrocytes of TED patients treated with Teprotumumab were found to have lower levels of expression of IGF-1 receptor and TSH receptor which are generally overexpressed in un treated TED suggesting the possible ability of Teprotumumab in reducing or even preventing TED.A prospective study used Tocilizumab, an antibody targeted against the interleukin (IL)-6 receptor, in patients with active TED resistant to prior i.v. corticosteroid therapy and significant improvement in proptosis and extraocular motility.Tanshinone(Tan IIA), is another molecule isolated from the Chinese plant *Salvia miltiorrhiza*, which is undergoing research and trials to explore its anti-inflammatory and antioxidative properties on orbital fibroblasts. The results showed that it can reduce the expression of IL-6 and IL-8 in orbital fibroblasts as well as degree of adipogenesis.<sup>31</sup>

#### **Irradiation therapy**

The role of radiotherapy as adjunctive to i.v steroids in the treatment of TED is a well established but as monotherapy is yet to be known. It is indicated for moderate to severe active disease or with confirmed disease progression. The standard regimen is 20 Gy/orbit in ten fractions over two weeks studies say lower doses may be as effective<sup>32</sup>.Documented risk of worsening retinal microvascular functions and secondary malignancy warrants its use in diabetes and young patients.<sup>33,34</sup>

#### **Surgical Treatment**

Surgical treatment in Thyroid ophthalmopathy has bimodal application.It is either used as urgent intervention as orbital decompression in vision threatening conditions like dysthyroid optic neuropathy to

relieve pressure on the orbital apex, reduce orbital congestion, improve vascular perfusion and axonal flow within the optic nerve or as a rehabilitative surgery in inactive disease to counteract the sequelae of initial inflammation mostly along with squint correction and lid repair in chronological order.

### **Orbital Decompression**

Most common indications are- Compressive optic neuropathy

- Excessive proptosis causing globe subluxation,
- corneal ulceration, and cosmetic disfigurement.

### **Principle ; Basically to create more space by**

- Fat decompression-reducing intraorbital fat contents ( intraconal and extraconal )

-Bone decompression-removing bony orbital walls but preserving the orbital rim to its maximum to secure eyelid and canthal tendon positions. A retrospective review suggests significant reduction of exophthalmos by 4.2 mm in 21 patients by orbital fat removal alone (average 4.0 ml) although total reduction depends on volume of fat removed, as well as age, sex, and the presence of preoperative diplopia and the technique of fat decompression. Of the many types of orbital decompression described, medial wall removal (especially posteriorly) is most effective in relieving orbital apex pressure. Recent novel endonasal endoscopic approach for orbital floor decompression preserved the inferomedial bony orbital strut in 100% cases in contrast to the traditional transconjunctival approach with a 71% strut preservation rate<sup>36</sup>. To reduce the risk of postoperative diplopia simultaneous medial and lateral wall decompressions or Balanced orbital decompression with preservation of the inferomedial orbital strut is done. In a retrospective study of 59 eyes, 56 showed statistically significant improvement in vision as well as reduction in average intraocular pressure.<sup>37</sup>

In Patients with compressive optic neuropathy refractory to three-wall decompressions, addition of transcranial orbital roof decompression showed improved visual acuity to at least 20/20 in all eyes, increased visual field mean deviation and reduction of proptosis by 4 mm, with no change in diplopia after 5 years of follow-up. Stereotactic image guidance assisted endoscopic decompression makes the surgery more meticulous and is thought to decrease injury to orbital tissue while simultaneously ensuring a more thorough decompression. It can be a useful adjunct to orbital decompression surgery.<sup>39</sup>

### **Squint surgery**

Restricted extraocular muscles result in the motility imbalance causing diplopia which fluctuates as the disease progresses from acute inflammatory phase to later fibrotic phases of the disease. Therefore it is advisable to wait or manage diplopia with Fresnel prism or occlusion therapy for at least for 6 months and 4-6 weeks after the decompression surgery to get stable measurements. The main aim of strabismus surgery is to achieve single binocular vision in primary and downgaze positions that is achieved most commonly by recession of the medial rectus or inferior rectus muscle occasionally combined with adjustable suture to prevent large over or undercorrection.<sup>40</sup>

### **Lid surgery**

Lid retractions, though most common sign of TED, are not only cosmetically unacceptable but can cause sight-threatening exposure keratopathy of varying degrees as well as corneal ulceration and hence warrants urgent attention. Different lid lowering options are-

- Classical Retractor recessions (Levator recession)
- Graded Muller muscle resection
- Hyaluronic acid injection into the levator plane
- Upper eyelid weights

LPS recession, either by conjunctiva approach, or skin crease approach requires extensive release of the central aponeurosis, lateral horn and Muller's muscle from the tarsus and conjunctiva.<sup>41</sup> Graded Muller muscle resection in a study of 23 eyelids showed a statistically significant decrease in margin-reflex distance 1 (MRD1) from 5.7 to 4 mm while a prospective study of eight patients with hyaluronic acid injection showed an MRD1 decrease from 5.6 to 5 mm at 15 months.<sup>42,43</sup> Another study in 13-eyelids with upper eyelid weights, 77% of patients achieved normal eyelid position.<sup>44</sup> There is no evidence recommending Botulinum toxin in patients of TED probably due to delayed action and associated poor Bell's phenomena.

## **III. Conclusion**

Thyroid eye disease remains a therapeutic challenge for an ophthalmologist as till date there is no definite treatment algorithm and treatment is offered on tailor made approach depending upon the stage and

severity of the disease. New serum markers have improved the classification of TED that may assist in explaining the diagnosis, prognosis and expected response to therapy. Corticosteroids still is the mainstay of treatment for moderate to severe disease however there is increasing consensus towards the use of parenteral form as compared to the oral one on account of greater efficacy with lesser side effects. Recent advances revealing the underlying immunopathogenic mechanisms has paved the way for several newer steroid sparing agents with increased interest. Modified surgical techniques like balanced decompression, stereotactic image guidance, graded muller muscle resection, upper eyelid weights are showing promising results. Expanded treatment options in the form of steroid sparing agents needs further studies with critical analysis before establishing their definitive role.

**Source of support ;none....Conflict of interest ;nil**

### References

- [1]. Scott, I.U., Siatkowski, M.R., 1999. Thyroid eye disease. *Semin. Ophthalmol.* 14 (2), 52–61.
- [2]. Wiersinga, W.M., Bartalena, L., 2002. Epidemiology and prevention of Graves' ophthalmopathy. *Thyroid* 12 (10), 855–860.
- [3]. Bartley, G.B. et al., 1996. Clinical features of Graves' ophthalmopathy in an incidence cohort. *Am. J. Ophthalmol.* 121 (3), 284–290.
- [4]. Bartalena, L., Pinchera, A., Marcocci, C., 2000. Management of Graves' ophthalmopathy: reality and perspectives. *Endocr. Rev.* 21 (2), 168–199.
- [5]. Werner SC. Classification of the eye changes of Graves' disease. *Am J Ophthalmol.* 1969;68:646–8.
- [6]. Mourits MP, Koornneef L, Wiersinga WM, Prummel MF, Berghout A, van der Gaag R. Clinical criteria for the assessment of disease activity in Graves' ophthalmopathy: A novel approach. *Br J Ophthalmol.* 1989;73:639–44
- [7]. Luigi Bartalena, Lelio Baldeschi, Alison J. Dickinson, Consensus Statement of the European Group on Graves' Orbitopathy (EUGOGO) on Management of Graves' Orbitopathy. *Thyroid* Volume 18, Number 3, 2008
- [8]. Dolman PJ, Rootman J. VISA classification for graves orbitopathy. *Ophthal Plast Reconstr Surg.* 2006;22:319–24
- [9]. Stiebel-Kalish, H., Robenshtok, E., Gatton, D.D., 2010. Pathophysiology of Graves' ophthalmopathy. *Pediatr. Endocrinol. Rev.* 7 (Suppl. 2), 178–181.
- [10]. Noh, J.Y. et al., 2000. Thyroid-stimulating antibody is related to Graves' ophthalmopathy, but thyrotropin-binding inhibitor immunoglobulin is related to hyperthyroidism in patients with Graves' disease. *Thyroid* 10 (9), 809–813.
- [11]. Goh, S.Y. et al., 2004. Thyroid autoantibody profiles in ophthalmic dominant and thyroid dominant Graves' disease differ and suggest ophthalmopathy is a multiantigenic disease. *Clin. Endocrinol. (Oxf.)* 60 (5), 600–607.
- [12]. Boboridis K, Perros P General management plan. In: Weirsinga WM, Kahaly GJ, eds. *Graves' Ophthalmopathy: A multidisciplinary approach.* Basel: Karger 2008:88-95.
- [13]. Dodds NI, Atcha AW, Birchall D, Jackson A. Use of high-resolution MRI of the optic nerve in Graves' ophthalmopathy. *Br J Radiol.* 2009 Jul. 82(979):541-4.
- [14]. Regensburg NI, Wiersinga WM, Berendschot TT, Saeed P, Mourits MP. Densities of orbital fat and extraocular muscles in graves orbitopathy patients and controls. *Ophthal Plast Reconstr Surg.* 2011 Jul-Aug. 27(4):236-40.
- [15]. Krassas KE, Dumas A, Pontikides N, et al. Somatostatin receptor scintigraphy and octreotide treatment in patients with thyroid eye disease. *Clin Endocrinol (oxf)* 1995;42:571-80
- [16]. Bartalena L, Smoking and Graves' disease. *J Endocrinol Invest* 2002;25:42.
- [17]. Marcocci C, Kahaly GJ, Krassas GE, Bartalena L, Prummel M, Stahl M et al. European Group on Graves' Orbitopathy. Selenium and the course of mild Graves' orbitopathy. *N Engl J Med* 2011; 364: 1920– 1931
- [18]. Terwee CB, Prummel MF, Gerding MN, Kahaly GJ, Dekker FW, Wiersinga WM. Measuring disease activity to predict therapeutic outcome in Graves' ophthalmopathy. *Clin Endocrinol (Oxf)* 2005; 62: 145–155.
- [19]. Kahaly GJ, Pitz S, Hommel G, Dittmar M. Randomized, single blind trial of intravenous versus oral steroid monotherapy in Graves' orbitopathy. *J Clin Endocrinol Metab.* 2005;90:5234–40.
- [20]. Zang S, Ponto KA, Kahaly GJ. Clinical review: Intravenous glucocorticoids for Graves' orbitopathy: Efficacy and morbidity. *J Clin Endocrinol Metab.* 2011;96:320–32.
- [21]. Silkiss RZ, Reier A, Coleman M, Lauer SA. Rituximab for thyroid eye disease. *Ophthal Plast Reconstr Surg.* 2010;26:310–4.
- [22]. Salvi M, Vannucchi G, Campi I, Beck-Peccoz P. Rituximab in the treatment of thyroid eye disease: Science fiction? *Orbit.* 2009;28:251–5.
- [23]. Khanna D, Chong KK, Afifiyan NF, Hwang CJ, Lee DK, Garneau HC, et al. Rituximab treatment of patients with severe, corticosteroid-resistant thyroid-associated ophthalmopathy. *Ophthalmology.* 2010;117:133–139.e2.
- [24]. Salvi M, Vannucchi G, Campi I, Rossi S, Bonara P, Sbrozzi F, et al. Efficacy of rituximab treatment for thyroid-associated ophthalmopathy as a result of intraorbital B-cell depletion in one patient unresponsive to steroid immunosuppression. *Eur J Endocrinol.* 2006;154:511–7.]
- [25]. Stan MN, Garrity JA, Carranza Leon BG, et al. Randomized controlled trial of rituximab in patients with Graves' orbitopathy. *J Clin Endocrinol Metab* 2015; 100:432–441.
- [26]. Salvi M, Vannucchi G, Campi I, Curro` N, Beck-Peccoz P. New immunomodulators in the treatment of Graves' ophthalmopathy. *Ann Endocrinol (Paris)* 2008; 69: 153–156.
- [27]. Komorowski J, Jankiewicz-Wika J, Siejka A, Lawnicka H, Klysiak A, Gos R et al. Monoclonal anti-TNF $\alpha$  antibody (infliximab) in the treatment of patient with thyroid associated ophthalmopathy. *Klin Oczna* 2007; 109: 457–460.
- [28]. Ayabe R, Rootman DB, Hwang CJ, et al. Adalimumab as steroid-sparing treatment of inflammatory-stage thyroid eye disease. *Ophthal Plast Reconstr Surg* 2014; 30:415–419.
- [29]. Chen H, Mester T, Raychaudhuri N, et al. Teprotumumab, an IGF-1R blocking monoclonal antibody inhibits TSH and IGF-1 action in fibrocytes. *J Clin Endocrinol Metab* 2014; 99:E1635–E1640.
- [30]. Pérez-Moreiras JV, Alvarez-López A, Gómez EC. Treatment of active corticosteroid-resistant graves' orbitopathy. *Ophthal Plast Reconstr Surg* 2014; 30:162–167.
- [31]. Rhiu S, Chae MK, Lee EJ, et al. Effect of tanshinone IIA in an in vitro model of Graves' orbitopathy. *Invest Ophthalmol Vis Sci* 2014; 55:5900–5910.

- [32]. Bartalena L, Marcocci C, Tanda ML, Rocchi R, Mazzi B, Barbesino G, et al. Orbital radiotherapy for Graves' ophthalmopathy. *Thyroid*. 2002;12:245–50.
- [33]. Viebahn M, Barricks ME, Osterloh MD. Synergism between diabetic and radiation retinopathy: Case report and review. *Br J Ophthalmol*. 1991;75:629–32.
- [34]. Robertson DM, Buettner H, Gorman CA, Garrity JA, Fatourechi V, Bahn RS, et al. Retinal microvascular abnormalities in patients treated with external radiation for graves ophthalmopathy. *Arch Ophthalmol*. 2003;121:652–7.
- [35]. Wu CH, Chang TC, Liao SL. Results and predictability of fat-removal orbital decompression for disfiguring Graves' exophthalmos in an Asian patient population. *Am J Ophthalmol* 2008; 145:755–759.
- [36]. Bleier BS, Lefebvre DR, Freitag SK. Endoscopic orbital floor decompression with preservation of the inferomedial strut. *Int Forum Allergy Rhinol* 2014; 4:82–84
- [37]. Baril C, Pouliot D, Molgat Y. Optic neuropathy in thyroid eye disease: results of the balanced decompression technique. *Can J Ophthalmol* 2014; 49:162–166.
- [38]. Bingham CM, Harris Ma, Vidor Ia, et al. Transcranial orbital decompression for progressive compressive optic neuropathy after 3-wall decompression in severe Graves' orbitopathy. *Ophthal Plast Reconstr Surg* 2014; 30:215–218.
- [39]. Servat JJ, Elia MD, Gong D, et al. Electromagnetic image-guided orbital decompression: technique, principles, and preliminary experience with 6 consecutive cases. *Orbit* 2014; 33:433–436.
- [40]. Garrity JA, Saggau DD, Gorman CA, et al: Torsional diplopia after transantral orbital decompression and extraocular muscle surgery associated with Graves' orbitopathy. *Am J Ophthalmol* 1992;113:363–373
- [41]. Mills MD, Coats DK, Donahue SP, Wheeler DT: Strabismus surgery for adults: a report by the American Academy of Ophthalmology. *Ophthalmology* 2004;111:1255–1262.
- [42]. Ribeiro SFT, Garcia DM, Leal V, et al. Graded Müllerectomy for correction of Graves' upper eyelid retraction. *Ophthal Plast Reconstr Surg* 2014; 30:384–387.
- [43]. Kohn JC, Rootman DB, Liu W, et al. Hyaluronic acid gel injection for upper eyelid retraction in thyroid eye disease. *Ophthal Plast Reconstr Surg* 2014; 30:400–404.
- [44]. Elshafei AMK, Abdelrahman RM. Gold weight implants for management of thyroid-related upper eyelid retraction. *Ophthal Plast Reconstr Surg* 2014; 30:427–430.

Pain	1. Painful, oppressive feeling on or behind the globe, during the last 4 weeks
	2. Pain on attempted up, side or down gaze during the last 4 weeks
Redness	3. Redness of the eyelid(s)
	4. Diffuse redness of the conjunctiva, covering at least one quadrant
Swelling	5. Swelling of the eyelid(s)
	6. Chemosis
	7. Swollen caruncle
	8. Increase of proptosis of $P \geq 2$ mm during a period of 1–3 months
Impaired function	9. Decrease of eye movement in any direction $P \geq 5^\circ$ during a period of 1–3 months
	10. Decrease of visual acuity(with pin hole) of $P \geq 1$ line(s) on the Snellen chart during a period of 1–3 months

Fig 1. Clinical Activity Score

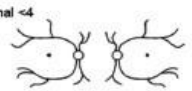


<b>VISA CLASSIFICATION:</b>		Date:		Visit #:	Patient Label:	
<b>ORBITOPATHY</b> Time since onset: Progress: Tempo: Symptoms:		<b>THYROID</b> Time since onset: Progress: Status: Symptoms:		<b>GENERAL</b> Smoking: Family Hx: Medical Hx: Allergies: Meds:		
Therapy:		Anti-thyroid meds:		Radioactive iodine:		
SUBJECTIVE		OBJECTIVE	OD	OS		
<b>VISION</b>					<b>Refractions</b> Wearing _____ + _____ X _____ + _____ X Manifest _____ + _____ X _____ + _____ X Normal -4 	
Vision: n / abn	Central vision: sc / cc / ph	20/___	20/___			
	with manifest	20/___	20/___			
Color vis: n / abn	Color vision errors (AO)	y / n	y / n			
	Pupils (afferent defect)	y / n	y / n			
Fundus	Optic nerve: Edema	y / n	y / n			
	Pallor	y / n	y / n			
Progress: s / b / w						
<b>INFLAMMATORY</b>				<b>Inflammatory index (worst eye/eyelid)</b> Chemosis (0-2): Conjunctival injection (0-1): Lid injection (0-1): Lid edema (0-2): Retrobulbar ache (0-2): <b>Total (8):</b>		
Retrobulbar ache	Chemosis (0-2)					
At rest (0-1)	Conjunctival injection (0-1)					
With gaze (0-1)	Lid injection (0-1)					
Lid swelling AM: y / n	Lid edema Upper (0-2)					
	Lower (0-2)					
Progress: s / b / w						
<b>STRABISMUS/ MOTILITY</b>				<b>Prism Measure:</b> 		
Diplopia:	Ductions (degrees):	+	+			
None (0)	Restriction > 45°	0	0			
With gaze (1)	30-45°	1	1			
Intermittent (2)	15-30°	2	2			
Constant (3)	< 15°	3	3			
Head turn: y / n						
Progress: s / b / w						
<b>APPEARANCE/ EXPOSURE</b>				<b>Palp proptosis and eyelid position:</b> 		
Lid retraction y / n	Lid retraction (upper): MRD-4	mm	mm			
	(lower scleral show):	mm	mm			
	Levator function	mm	mm			
	Lagophthalmos	mm	mm			
Proptosis y / n	Exophthalmometry (Hertel)	mm	mm			
Tearing y / n	Corneal erosions	y / n	y / n			
FB Sensation y / n	Corneal ulcers	y / n	y / n			
Progress: s / b / w	IOP -straight	mmHg	mmHg			
	-up	mmHg	mmHg			
<b>DISEASE GRADING</b>		Grade	Progress / Response			
V (optic neuropathy)	y / n	y / n	s / b / w			
I (inflammation) 0-8	/ 8	/ 8	s / b / w			
S (strabismus) 0-3	/ 3	/ 3	s / b / w			
(restriction) 0-3	/ 3	/ 3	s / b / w			
A (appearance/exposure)	mild / mod / severe		s / b / w			
<b>MANAGEMENT</b>				<b>FOLLOW-UP INTERVAL:</b>		

Fig 2 VISA Classification

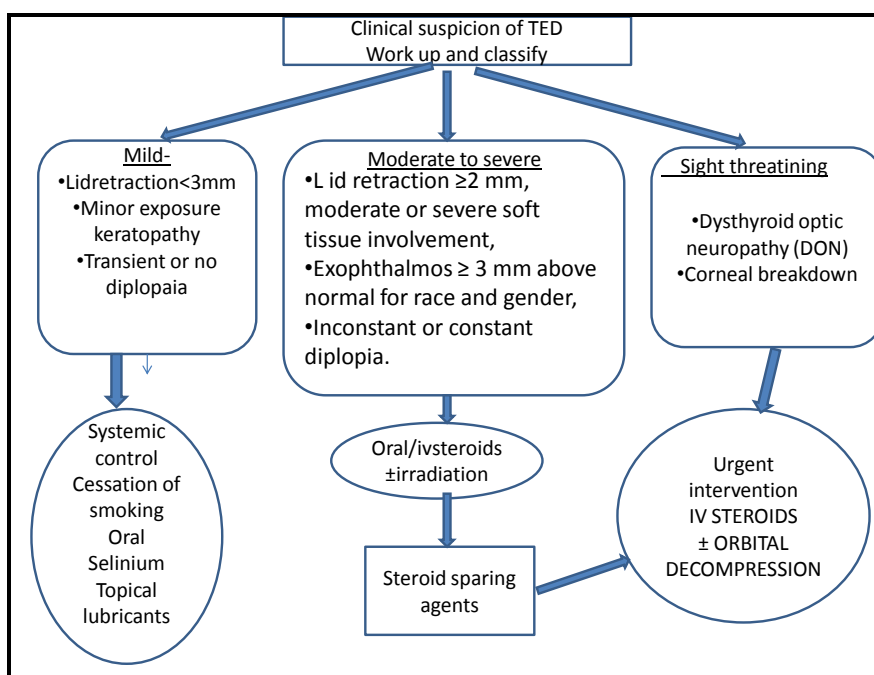


Fig.3.Flow chart of the management of TED