

## Venous Leg Ulcer - Management Experience In A Tertiary Healthcare Center In Eastern India

Dr Vivek Bhasker, Dr R.S.Sharma, Dr Brajesh Kumar, Dr Bikram Kumar,  
Dr. Sandeep Kumar, Dr. M.D.Kerketta,  
<sup>1</sup>senior Resident, Rims, Ranchi, <sup>2</sup>associate Professor, Rims, Ranchi  
<sup>3,4</sup>2<sup>nd</sup> Year PGT, Rims, Ranchi, <sup>5</sup>associate Professor, Rims, Ranchi  
<sup>6</sup>associate Professor, Rims, Ranchi

---

### Abstract:

**Introduction:** venous ulcer is most common type of chronic leg ulcer. In this study we have tried to summarize the experience of venous ulcer treatment in RIMS, Ranchi; a tertiary healthcare center in eastern India.

**Material and methods:** This is a prospective study done over a period of 2 years. Patients of venous ulcer were treated with conservative approach and followed up. In case of no response or poor response to conservative treatment, surgical treatment was done

**Result:** 92.9% patients were male and 7.1% were female. Mean ulcer size at presentation was 37.5 cm<sup>2</sup>. 85.7% ulcers healed completely on conservative treatment at 3 month follow up, another 9.5% healed at 5 months followup and in 4.7% cases surgical treatment was required

**Conclusion:** in our institute good healing rate is achieved in treatment of venous ulcer with conservative management

**Keywords:** leg ulcer, varicose vein, chronic venous insufficiency, compression stocking, sclerotherapy

---

### I. Introduction

Three main types of chronic leg ulcers are- venous, arterial, and neuropathic. Venous ulcers are most common (75%) of all chronic leg ulcers.<sup>1</sup> Venous ulcers develop due to chronic venous insufficiency (CVI).<sup>2, 4, 5</sup> Causes of chronic venous insufficiency are:

- A) Primary varicose veins
- B) Secondary varicose veins which develop most commonly after deep vein thrombosis.
- C) Failure of the valves and
- D) Predisposing factors like old age, obesity, and prolonged dependent posture.

Chronic venous insufficiency leads to inflammatory reactions in interstitial tissue ultimately resulting in development of venous ulcer. For confirmation of diagnosis Duplex scan with color flow is the investigation of choice.<sup>14</sup> Plethysmography<sup>15</sup> and Ascending & descending venography<sup>16</sup> may occasionally be required.

### Treatment Options For Venous Ulcer Are-

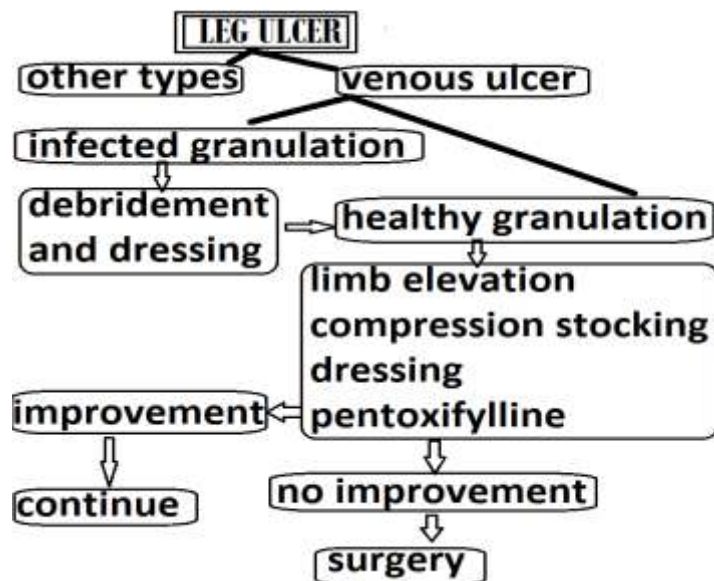
- A) Leg elevation above the level of heart reduces edema, improves venous drainage and microcirculation.<sup>17</sup>
- B) Elastic Compression stocking therapy- reduces edema and pain, improves venous circulation and enhances ulcer healing. Lifelong maintenance of compression therapy after ulcer healing reduces the rate of recurrence.<sup>18</sup>
- C) Medications- Pentoxifylline has additive beneficial effect to compression.<sup>19,20,29</sup> Aspirin<sup>21</sup>, Intravenously administered iloprost<sup>20</sup> and prostaglandin E1 analogue<sup>22</sup> can also be used.
- D) Mechanical Negative pressure wound therapy, hyperbaric oxygen therapy - data are insufficient to support their use in venous ulcers.<sup>23, 24</sup>
- E) Debridement if required and different types of dressing materials like hydrocolloids, foams, hydrogels, pastes and simple non-adherent dressings.<sup>25</sup>
- F) Surgical management is indicated for ulcers that are large, of prolonged duration<sup>26</sup> or not responsive to conservative measures.<sup>27</sup> Split-thickness skin grafts, local flaps and microvascular flaps, any of the above can be used.

### II. Material And Method

This is a prospective longitudinal study of patients with venous leg ulcers treated in the department of general surgery, RIMS, Ranchi; from January 2015 to December 2016. The study was approved by the departmental research ethics committee.

Patients of leg ulcer coming to surgery OPD were examined and those having venous ulcer (diagnosed by clinical examination and Doppler study) were included in the study. Venous leg ulcers were defined as any ulcer located below the knee with one or more of the following manifestations: edema, hyperpigmentation (stasis dermatitis), eczema, lipodermatosclerosis, and varicose veins. The exclusion criteria were leg ulcers of any other etiology and venous ulcers associated with peripheral artery disease. Size of the ulcer in each case was measured by tracing its borders onto clear paper and measuring it. Treatment offered- If the venous ulcer was infected and was covered with necrotic/infected granulation tissue, it was first treated by regular debridement and dressing. In patients having venous ulcer covered with healthy red granulation tissue treatment advised consisted combination of - lower limb elevation + regular and continuous use of graduated pressure stockings + regular dressing of the wound with amorphous hydrogel with colloidal silver ointment + tab. Pentoxifylline 400 mg TDS.

Ulcer size measurements were taken weekly for three months (some cases needed longer follow-up). Most patients showed good response with above treatment protocol. In those patients who didn't show signs of improvement even after 3 months with above treatment protocol, surgical treatment was considered for further management. Surgeries performed in such patients in our institution were-surgical treatment of primary venous pathology (flush ligation of great saphenous vein at saphenofemoral junction and/or foam sclerotherapy) + partial thickness skin grafting/local advancement & rotation flaps to cover the ulcer.



**Picture:** management protocol used in study

Data containing details of each patient and treatment received were entered in data collection sheet. All statistical analysis was carried out using SPSS software version 23.

### III. Result

A total of 42 cases of venous ulcer were included in this study. Out of that 39(92.9%) were male and 3(7.1%) were female. Mean age of patient population was 47years with SD=7.25years (range-33 to 59 years). In all cases ulcer was located in medial aspect of lower leg near medial malleolus. Mean ulcer size at presentation was 37.57cm<sup>2</sup> with SD =26.20cm<sup>2</sup> (range 7 to 110cm<sup>2</sup>).

With the conservative treatment provided in this study, most ulcers showed good healing response. At three months follow up- in 36(85.7%)cases ulcers were completely healed , in 4(9.5%) patients ulcers were reduced to <25% of its initial size and in only 2(4.7%) cases no significant improvement was seen. In these 2 cases with no improvement after 3 months of conservative treatment; surgical treatment was done. Surgery done was- flush ligation of great saphenous vein at saphenofemoral junction +stripping and foam sclerotherapy for smaller varicosities. This was followed by split thickness skin grafting at ulcer site done 1 week after stripping. These 2 cases were completely cured at 5<sup>th</sup> months of treatment.

#### IV. Discussion

Venous ulceration is the outcome of chronic venous insufficiency in the leg.<sup>2, 4, 5</sup>

In this study we have tried to summarize our experience about treating venous ulcer in RIMS, Ranchi; a medical college in eastern India. This study was done over a period of 2 years. According to this study males are affected with venous ulcer more commonly than females and this difference is statistically significant. All the venous ulcers were located in medial lower leg. Treatment offered to such patients in our institute is a modified version of bisgaard's regimen. At three months follow-up 85.7% cases were completely cured while 9.5% cases needed same treatment for 2 more months. In only 4.7% cases surgical treatment was required. Good response with conservative management in treatment of venous ulcer is also seen in study done by William A. Marston et al.<sup>30</sup> Surgery performed in a particular patient depends on many factors and hence can vary from patient to patient.

#### V. Conclusion

Venous ulcers are the most common of all leg ulcers<sup>1</sup>. Diagnosis is possible in most cases on clinical examination. Duplex scan with color flow is the investigation of choice to confirm the diagnosis. In most cases conservative management with leg elevation, compression therapy, regular dressing and oral pentoxifylline is sufficient to cure the ulcer. Choice of dressing material is guided by local availability, cost-effectiveness and personal preference. Ulcers not healing on conservative management need surgery. Surgical therapy can vary from patient to patient depending upon the primary pathology. Aim of the surgery is to treat the primary disease and to cover the ulcer with skin graft/tissue flaps. Treatment standardization needs further study with larger study population and much longer follow-up.

#### References

- [1]. Collins R, Seraj S. Diagnosis and treatment of venous ulcers. *Am Fam Physician*. 2010;81:989–96.
- [2]. Fowkes FG, Evans CJ, Lee AJ. Prevalence and risk factors of chronic venous insufficiency. *Angiology*. 2001;52:S5-15.
- [3]. Valencia IC, Falabella A, Kirsner RS, Eaglstein WH. Chronic venous insufficiency and venous leg ulceration. *J Am Acad Dermatol*. 2001;44:401-21
- [4]. Gross EA, Wood CR, Lazarus GS, Margolis DJ. Venous leg ulcers: an analysis of underlying venous disease. *Br J Dermatol*. 1993;129:270-4.
- [5]. Zimmet SE. Venous leg ulcers: modern evaluation and management. *Dermatol Surg*. 1999;25:236-41.
- [6]. Valencia IC, Falabella A, Kirsner RS, Eaglstein WH. Chronic venous insufficiency and venous leg ulceration. *J Am Acad Dermatol*. 2001;44:401–21.
- [7]. Etufugh CN, Phillips TJ. Venous ulcers. *Clin Dermatol*. 2007;25:121–30.
- [8]. Michiels C, Arnould T, Thibaut-Vercruyssen R, Bouaziz N, Janssens D, Remacle J. Perfused human saphenous veins for the study of the origin of varicose veins: Role of the endothelium and of hypoxia. *Int Angiol*. 1997;16:134–41.
- [9]. Ascher E, Jacob T, Hingorani A, Tsemekhin B, Gunduz Y. Expression of molecular mediators of apoptosis and their role in the pathogenesis of lower-extremity varicose veins. *J Vasc Surg*. 2001;33:1080–6.
- [10]. Haardt B. A comparison of the histochemical enzyme pattern in normal and varicose veins. *Phlebology*. 1987;2:135–58.
- [11]. Barber DA, Wang X, Gloviczki P, Miller VM. Characterization of endothelin receptors in human varicose veins. *J Vasc Surg*. 1997;26:61–9.
- [12]. Lowell RC, Gloviczki P, Miller VM. In vitro evaluation of endothelial and smooth muscle function of primary varicose veins. *J Vasc Surg*. 1992;16:679–86.
- [13]. Clarke GH, Vasdekis SN, Hobbs JT, Nicolaidis AN. Venous wall function in the pathogenesis of varicose veins. *Surgery*. 1992;111:402–8.
- [14]. Perrin MJ. Surgery for deep venous reflux in lower limb (article in French) *J MalVasc*. 2004;29:73–87.
- [15]. Holm J, Nilsson NJ, Scheersten T, Sivertsson R. Elective surgery for varicose veins. A simple method for evaluation of the patients. *J Cardiovasc Surg (Torino)* 1974;15:565–72.
- [16]. Raju S, Fredericks R. Venous obstruction: An analysis of one hundred thirty-seven cases with hemodynamic, venographic and clinical correlations. *J Vasc Surg*. 1991;14:305–13.
- [17]. Abu-Own A, Scurr JH, Coleridge Smith PD. Effect of leg elevation on the skin microcirculation in chronic venous insufficiency. *J Vasc Surg*. 1994;20:705–10.
- [18]. Ruckley CV. Socioeconomic impact of chronic venous insufficiency and leg ulcers. *Angiology*. 1997;48:67–9.
- [19]. Jull A, Waters J, Arroll B. Pentoxifylline for treatment of venous leg ulcers: A systematic review. *Lancet*. 2002;359:1550–4.
- [20]. Robson MC, Cooper DM, Aslam R, Gould LJ, Harding KG, Margolis DJ, et al. Guidelines for the treatment of venous ulcers. *Wound Repair Regen*. 2006;14:649–62.
- [21]. Layton AM, Ibbotson SH, Davies JA, Goodfield MJ. Randomised trial of oral aspirin for chronic venous leg ulcers. *Lancet*. 1994;344:164–5.
- [22]. Patel NM, Labropoulos N, Pappas PJ. Current management of venous Ulceration. *Plastic and Reconstructive Surgery*. 2006;117(Suppl. issue 7S):254S–260S.
- [23]. Vuerstaek JD, Vainas T, Wuite J, Nelemans P, Neumann MH, Veraart JC. State-of-the-art treatment of chronic leg ulcers: A randomized controlled trial comparing vacuumassisted closure (V.A.C.) with modern wound dressings. *J Vasc Surg*. 2006;44:1029–37.
- [24]. Kranke P, Bennett M, Roedel-Wiedmann I, Debus S. Hyperbaric oxygen therapy for chronic wounds. *Cochrane Database Syst Rev*. 2004;(2):CD004123.
- [25]. Palfreyman S, Nelson EA, Michaels JA. Dressings for venous leg ulcers: Systematic review and meta-analysis. [published correction appears in *BMJ* 2007;335(7617):0. *BMJ*. 2007;335:244–8.

- [26]. Nelson EA, Bell-Syer SE, Cullum NA. Compression for preventing recurrence of venous ulcers. *Cochrane Database Syst Rev.* 2000;(4):CD002303.
- [27]. Tallman P, Muscare E, Carson P, Eaglstein WH, Falanga V. Initial rate of healing predicts complete healing of venous ulcers. *Arch Dermatol.* 1997;133:1231-4.
- [28]. Goldman MP, Fronek A. Anatomy and pathophysiology of varicose veins. *J Dermatol Surg Oncol.* 1989;15:138-45.
- [29]. Hossien Parsa, MD; Amir Abdollah Zangivand, MD; Liela Hajimagsoudi, The Effect of Pentoxifylline on Chronic Venous Ulcers. *Wounds.* 2012;24(7):190-194.
- [30]. William A. Marston, Robert E. Carlin, Marc A. Passman, Mark A. Farber, Blair A. Keagy, Healing rates and cost efficacy of outpatient compression treatment for leg ulcers associated with venous insufficiency [http://doi.org/10.1016/S0741-5214\(99\)70076-5](http://doi.org/10.1016/S0741-5214(99)70076-5)