

Porcelain Laminate Veneers

Dr. Bhumika Tahiliani, Dr. Vidhi Shah, Dr. Nameeta Hankare

(Post Graduate Student, Dept. Of Prosthodontics, D.Y. Patil School Of Dentistry)

(Bachelor Of Dental Surgery, G.D. Pol Foundation, Ymt Dental College, Kharghar, Navi Mumbai)

(Bachelor Of Dental Surgery, Terna Dental College And Hospital, Nerul, Navi Mumbai)

Abstract: Laminate veneer restorations have a unique position in today's dental practice, they are used to optimize tooth form and position, close diastema, replace discoloured or unaesthetic composite resin restorations. These are conservative restorations a factor which is essentially important. This case report presented describes a minimal invasive treatment of four maxillary anteriors with gurels technique. A step-by-step protocol is proposed for diagnostic evaluation, mock-up fabrication and trial, teeth preparation and impression, and adhesive cementation.

Keywords: Adhesive, Esthetics, Laminates, Porcelain, Veneers

I. Introduction

The art of veneering teeth has progressed over 30 years to the current generation of concepts and materials, which can be divided into two categories: (1) directly fabricated composite resin veneers (i.e., free-hand placed), and (2) indirectly fabricated veneers, such as preformed laminates or laboratory fabricated acrylic resin, microfill resin, or porcelain veneers.

Basic Chemistry

The porcelain-bonded restoration consists of four components:-

1. An internally etched porcelain veneer
2. An acid etched enamel surface
3. A silane-coupled agent
4. A composite resin luting cement

Porcelain

Dental porcelains are composed of natural feldspar (both potassium and sodium alumino-silicate glasses). Early porcelain-laminate veneers utilized the same porcelains used in all-porcelain restorations. In recent years, high strength porcelains specifically designed for bonded restorations have been introduced. These materials are stronger than conventional porcelains and composite resin and have a hardness comparable with that of enamel. Some manufactures claim that high-strength porcelains have sufficient strength for use as all-porcelain bridges.

Acid Etching

Retention of the acid-etch retained porcelain restoration is accomplished by the creation of microporosities in both the porcelain and enamel. Porcelain porosities are derived from treating the internal surface of the restoration with a 10% acid solution, such as hydrofluoric acid (HFA). Studies show that etching with or without the use of a silane coupling agent greatly increases bond shear strength, which can even surpass resin-enamel bond strength. Salivary contamination of the etched porcelain can significantly reduce bond strength, even after cleaning with acetone. Application of 37% phosphoric acid for 15 seconds has been shown to restore the etched surface. The etched surface is stable over extended periods. One study demonstrated that a 7-day delay between etching and silane application/ veneer cementation did not reduce bond strength when the laminate veneers were kept in a dry environment (e.g. a simple plastic box).

Silane Coupling Agents

The function of a coupling agent is to alert the surface of a solid to facilitate either a chemical or physical process. Numerous silane coupling agents exist and are used in dentistry to increase the shear strength of the porcelain-to-composite resin bond. These agents are believed to be capable of chemically bonding to silica in both the porcelain laminate veneer and the composite resin matrix. Scanning electron micrographs reveal that silane and etching eliminate the polymerization contraction gap, which forms in both etched, non-silanated and unetched, silanated restoration by allowing the resin to better wet the surface. An in vitro study using two different types of feldspathic porcelain concluded that silane combined with the action of hydrofluoric acid gel is the most effective surface treatment for ceramics. Another in vitro study found that a single

reapplication of silane maintained the bond strength of resin to porcelain where final cementation was preceded by a 5-minute, non-activated resin try-in procedure and a 3-minute acetone cleaning.

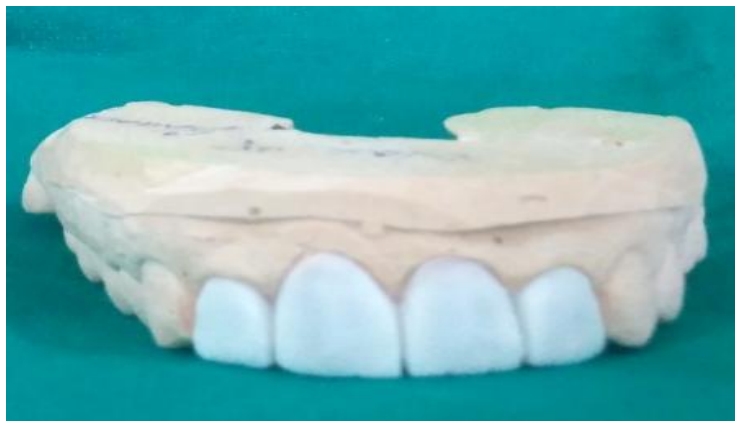Composite Resin Luting Cements

Initially, laminate veneers were retained with auto-curing composite resins. Light-activated composite resin luting cements provided increased working time. Most resin cements are thinned versions of previously available restorative resins. Numerous viscosities are available, with medium viscosity being the most popular. Different shades and opacities allow for color modification of the restoration. Light-activated resins are ideally suited for most laminate veneers. However, they require sufficient light from a curing light to initiate curing. Therefore they should not be used when the light must travel through a thickness of porcelain that exceeds the manufacturer's recommendations. Factors affecting this maximum depth include the specific light source, the age of the bulb, the shade and opacity of the laminate, and the shade and opacity of the composite resin cement.

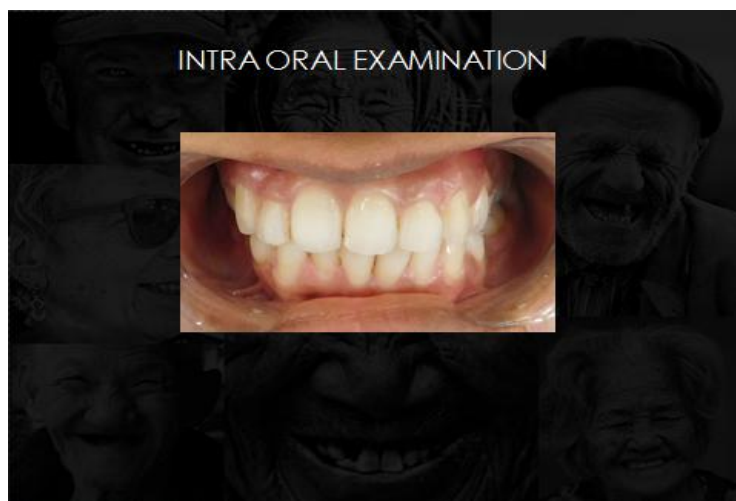
This is particularly problematic in the gingival floor and axial wall areas of the interproximal box of porcelain inlays or onlays. The light source cannot be positioned perpendicular to the interproximal surface because of the approximating tooth; therefore light rays entering this region at an angle may be required to penetrate 4 to 8 mm of porcelain. In both these case, a dual-cured composite resin luting system should be used. Laser light sources may penetrate deeper than conventional light sources, but their use may raise issues concerning the rapidity of the composite resin cure.

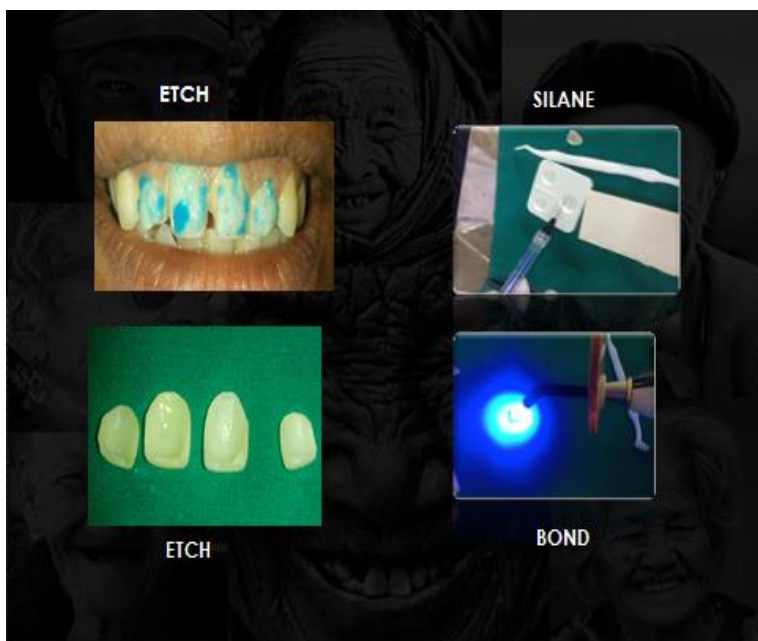
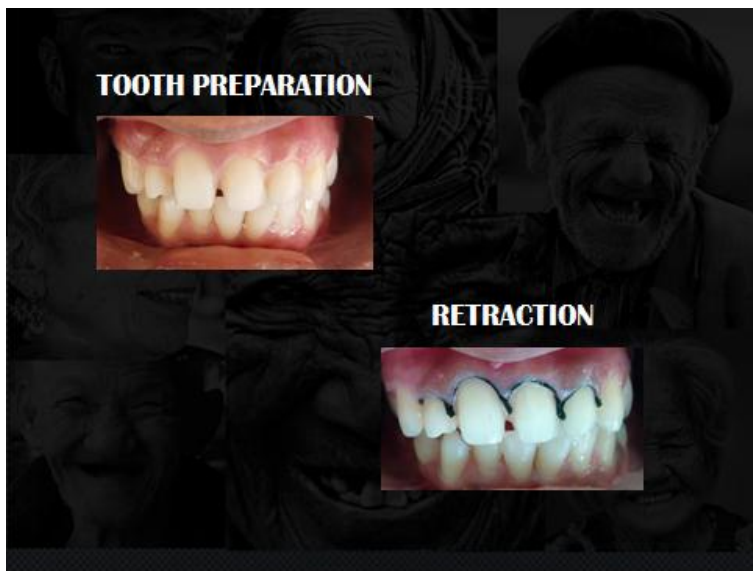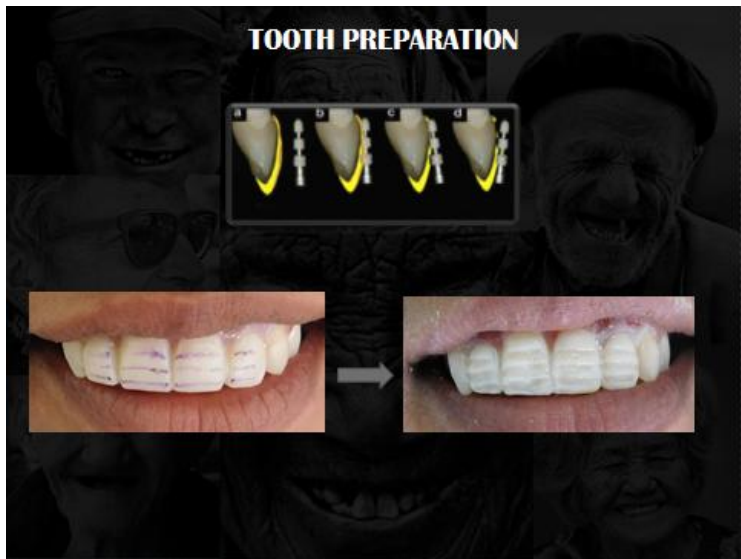II. Case Report

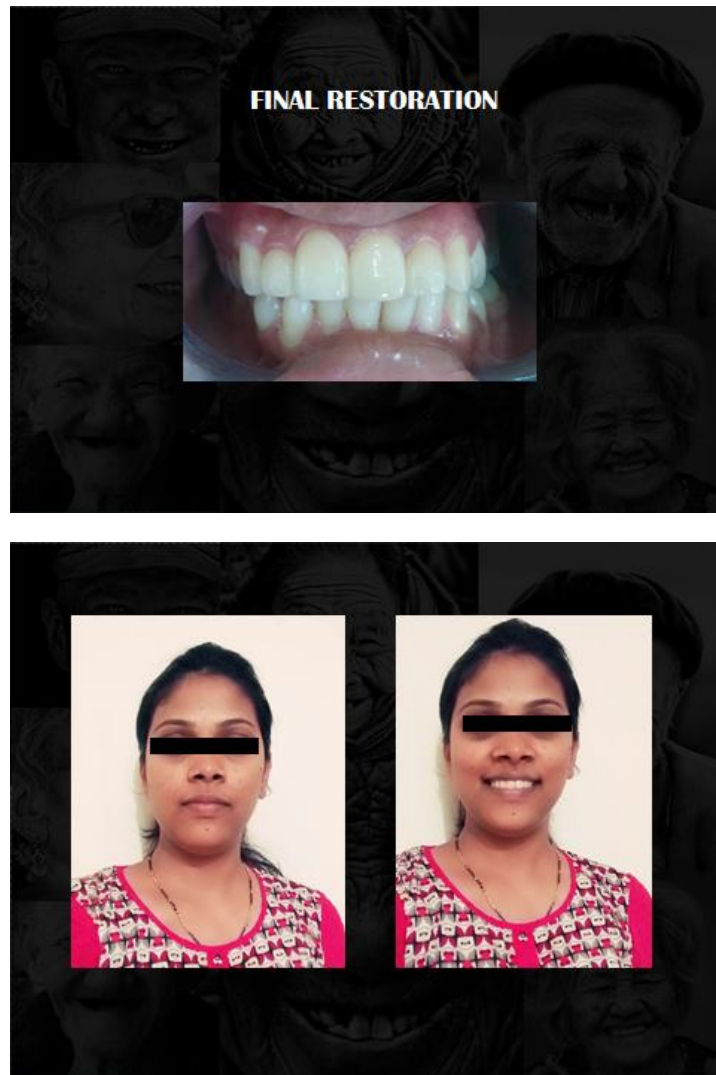
A 25 year old female patient came to the department of prosthodontics with a chief complaint of overlapping teeth in the upper front region. On Intra oral examination it was found that 21 was overlapping the 11 slightly. With the help of radiographs, photographs, pre operative casts, a wax up was done for 11,12,21,22.



A treatment plan was formulated and discussed with the patient Porcelain laminate veneers were suggested in 11,12,21,22. Gurels technique for laminate preparation was followed using the APT technique- Aesthetic pre evaluative temporaries.







Advantages Of Bonded Porcelain Restorations

The main advantages of bonded porcelain restorations are the following:-

1. **Excellent esthetics:** Porcelain offers unsurpassed esthetics and inherent color control. In addition, unlike direct laminate veneers, the porcelain laminate veneers depend less on the esthetic skill of the dentist.
2. **Excellent long-term durability:** Porcelain is both abrasion resistant and color stable. In addition, porcelain has excellent resistance to fluid absorption.
3. **Inherent porcelain strength:** Porcelain exhibits excellent compressive, tensile, and shear strengths when bonded to enamel.
4. **Marginal integrity:** Porcelain restorations bonded to enamel exhibit exceptional marginal integrity.
5. **Soft tissue compatibility:** Properly polished porcelain is highly biocompatible with gingival tissue.
6. **Minimal tooth reduction:** Anterior porcelain laminate veneers are considerably more conserving of tooth structure than porcelain-fused-to-metal and all-porcelain full coverage restorations.

Disadvantages Of Bonded Porcelain Restorations

The primary disadvantages of bonded porcelain restorations are the following:-

1. **Time:** Multiple visits are required.
2. **Cost:** Laboratory involvement and additional chair time are required when compared with direct restorations, resulting in higher costs to the patient.
3. **Fragility:** Although strong when bonded to the tooth, bonded porcelain restorations are extremely fragile during the try-in and cementation stages.
4. **Lack of reparability:** Porcelain restorations are difficult, if not impossible, to repair.
5. **Difficulty in color matching:** Although porcelain restorations are colorstable, precise matching of a desired shade tab or an adjacent tooth can be difficult. In addition, shade alteration is impossible after cementation.

6. Irreversibility: Tooth reduction, although often minimal, is required.

7. Inability to trial cement the restoration: Unlike traditional indirect restorations, bonded porcelain restorations cannot be temporarily retained with a provisional cement for valuation purposes.

III. Discussions

Indications

Porcelain laminate veneers may be indicated in areas traditionally restored with single crowns or composite resin veneers for the following:

1. Correcting diastema
2. Masking discolored or stained teeth
3. Masking enamel defects
4. Correcting malaligned or malformed teeth.

Porcelain inlays and onlays may be indicated in areas traditionally restored with amalgams, single-unit cast restorations and composite resins.

1. For the esthetic restoration of large posterior teeth with adequate tooth structure.
2. As a conservative esthetic alternative to full coverage restorations in teeth requiring onlaying of cusps.
3. As a more durable alternative to posterior composite resin restorations.
4. As a less periodontally invasive alternative to full and partial coverage restoration with subgingival margins.
5. In “amalgam phobic” patients.

Contraindications

Porcelain laminate veneers may be contraindicated for the following:-

1. Patients who exhibit tooth wear as a result of bruxism.
2. Short teeth.
3. Teeth with insufficient or inadequate enamel for sufficient retention (e.g., severe abrasion).
4. Existing large restorations or endodontically treated teeth with little remaining tooth structure.
5. Patients with oral habits causing excessive stress on the restoration (e.g. nail biting, pencil biting).

Porcelain inlays and onlays may be contraindicated for the following:-

1. Patients who exhibit bruxism.
2. Short teeth.
3. Insufficient or inadequate enamel for sufficient retention.
4. Exceedingly thin buccal or lingual walls.
5. Endodontically treated teeth with little remaining tooth structure.
6. Patients with oral habits causing excessive stress on the restoration (e.g. nail biting, pencil biting).

IV. Conclusion

Marginal discrepancies immediately after cementation of indirect restorations are to some degree, inevitable.

Post-cementation intraoral finishing of both porcelain and resin at the tooth restoration interface can be accomplished with rotary instruments. Scanning electron microscope and spectrographic refractance analyses reveal that adjusted porcelain can attain a surface smoothness that is superior to that of glazed porcelain if a specific protocol is followed. This protocol is outlined below and involves the use of progressively finer abrasives. Finishing and polishing instruments include diamond burs, a 30-fluted carbide bur and a 2µm to 5µm particle size diamond polishing paste on a webbed rubber prophylaxis cup.

References

- [1]. GalipGürel, Science and Art of Porcelain Laminate Veneers Author
- [2]. Smile Design Integrating Esthetics and Function 1st Edition
- [3]. Jonathan Levine, Brian Millar,Essentials in Esthetic Dentistry.
- [4]. George E Kirtley,The art of a beautiful smile
- [5]. Mauro Fradeani, Esthetic rehabilitation in fixed prosthodontics
- [6]. GiullianaPanfiglio(Soares1* ThiagoAssunção Valentino2* DéboraAlvesNunesLeite Lima2* Luis AlexandreMaffeiSartini Paulillo3* Frederico Augusto Peixoto Silva4 José Roberto Lovadino3*Braz J Oral Sci. April-June 2007 - Vol. 6 - Number 21)Esthetic analysis of the smile