

## The Interhemispheric Transcallosal Approach in the Treatment of Cavernous Malformation of the Third Ventricle Case Report and Literature Review

Benmamar.T<sup>1</sup>, Bouaita.K<sup>1</sup>, Shabay.Z<sup>1</sup>  
<sup>1</sup>(Neurosurgery, Ehs Ali Ait Idir, Algiers, Algeria)

**Abstract:** Intracerebral cavernomas represent 5-10% of all vascular malformations of the central nervous system. Their location in the third ventricle is very rare. Only about a hundred cases have been reported in the literature so far. We present for the first time a case of third ventricular cavernoma encountered in a 39-year-old patient admitted in our department, while detailing the various difficulties encountered in the management of this rare entity.

**Keywords:** cavernoma – third ventricle – transcallosal approach

### I. Introduction

Intracerebral cavernomas represent 5-10% of all vascular malformations of the central nervous system. Their intraventricular location is rare; estimated at 2.5 to 10.8%, even more rare in the third and fourth ventricles. Nearly 100 cases have been reported in the literature. The median age is 43.5 years, with a female predominance. Surgery is indicated whenever the lesion is accessible. This is a case of third ventricle cavernoma which has been operated in our institution.

### II. Material And Methods

This is a 39-year-old patient with unremarkable past medical history, who presented with an intracranial hypertension syndrome for 5 months, followed by a rapid deterioration in consciousness with a tendency of drowsiness. The brain CT-scan revealed a polylobed, well-limited, spontaneously hyperdense, heterogeneous diencephalic process, intensely and heterogeneously enhanced after injection of contrast media suggestive of old hemorrhagic episodes accompanied by active hydrocephalus. The cerebral MRI done subsequently showed an expansive lesion filling the third ventricle from its anterior part and raising the floor of the latter, surrounded by a peripheral ring, filling the opto-chiasmatic cisterns, appearing in hypersignal T1 and T2 and weighted images and heterogeneous after injection of Gadolinium; a probable haemorrhagic aspect.

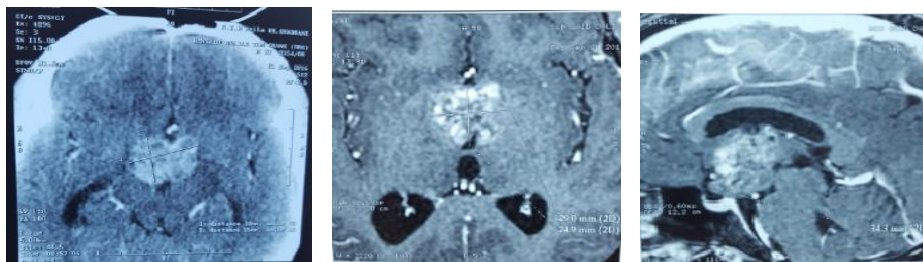


Fig1: Brain ct- scan before and after injection of contrast material showing the hypervascularized brain tumor process originating from the third ventricle

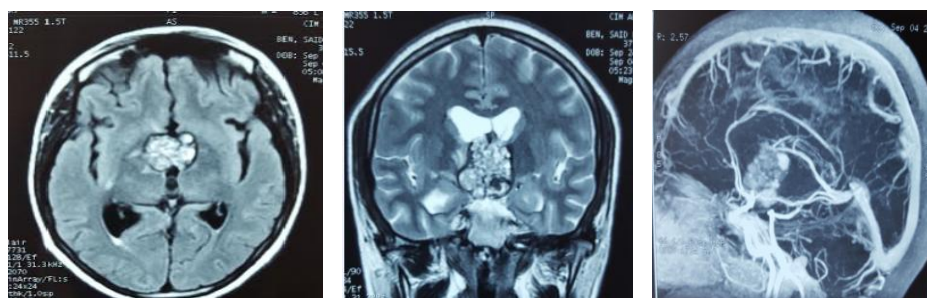
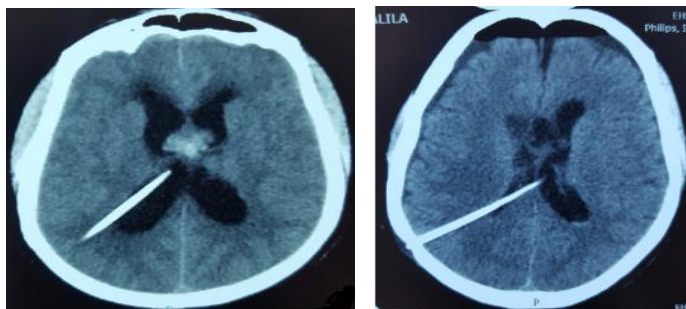


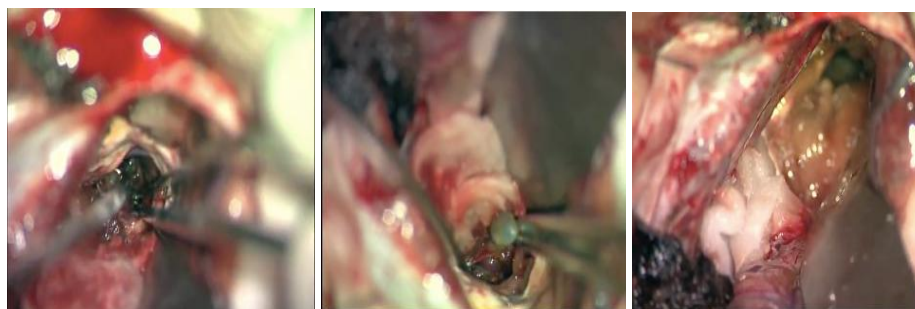
Fig2: Brain MRI in T1 and T2 weighted sequence and in angiographic sequence showing the same tumor process that fills the third ventricle, encapsulated and heterogeneous signal due to intratumoral haemorrhages

### III. Results

The patient initially benefited from an emergency ventriculo-peritoneal shunt. The patient was then operated for her lesion in a second sitting by anterior transcallosal interhemispheric approach. Subtotal reddish black tumor excision was done in view of its intimate adhesion to the floor of the third ventricle. The histopathological study revealed a cavernoma. The post-surgical outcome was marked by the persistence of a state of drowsiness. Postoperative brain CT-scan showed the presence of a tumor residue adjacent to the floor of the third ventricle. The hormonal imbalance detected an imbalance of the thyroid and corticotropic axes which were subsequently supplemented.



**Fig3:** Brain ct- scan after placement of the ventriculo-peritoneal shunt and after tumor excision.



**Fig4:** Visualization of the caverns at the end of tumor excision with preservation of the integrity of the floor of the third ventricle

### IV. Discussion

Intraventricular cavernomas represent about 2.5% of all endocranial cavernomas, Houtteville in 1985, found 6 cases in the third ventricle [1]. The median age is 43.5 years, with a female predominance of 2: 1. Due to their location, they may manifest by intracranial hypertension [3], subarachnoid or intraventricular haemorrhage. However, intraparenchymal haemorrhage even from intraventricular location is not excluded. In the literature, only 14% of published cases of intraventricular cavernomas presented with intraventricular hemorrhage [9]. Generally, resection of intraventricular cavernomas does not significantly pose a risk for permanent neurological deficit [4]. Of the 89 published cases of intraventricular cavernomas, only one patient died during surgery for cavernoma resection due to rebleeding in the temporal horn of the lateral ventricle with massive intra-ventricular hemorrhage and intracerebral hematoma [2]. Brain MRI often leads to its diagnosis. On the T1 and T2 weighted sequences, the center appears as a heterogeneous signal, while the periphery appears hyposignal which suggests a circle of hemosiderin proving repeated bleeding of the lesion. The T1-weighted sequence with gadolinium injection makes it possible to obtain a contrast of this process, which can vary from high enhancement to the absence of contrast enhancement. The gradient echo-weighted MRI sequence is the master sequence in the diagnosis of cavernomas [8, 10]. One can also appreciate the presence of mass effect, of an overlying hydrocephalus, and sometimes of little perilesional edema. Surgery is always indicated whenever the lesion is accessible and the CSF circulation must be restored. Transcallosal interhemispheric approach avoids trauma of the brain parenchyma, although the prognosis of these lesions is difficult to predict because some of them are strongly attached to the floor of the third ventricle, particularly the hypothalamus [5, 6], but also to their tendency for rapid growth due to intra-lesional haemorrhage, this phenomenon being probably explained by the absence of great resistance at the periphery of the lesion. For this reason, it is essential, as far as possible, to perform the most complete resection, even if it is necessary to re-operate in case of partial excision [7]. This is shown in the literature which shows a high number of deaths among patients who have undergone partial resection [10]

## V. Conclusion

Despite their rarity, cavernomas of the third ventricle are lesions that should be suspected when a tumor is detected near the third ventricle, their total excision is essential for cure.

## References

- [1]. Mohana Rao Patibandla, Amit Kumar Thotakura & Manas Kumar Panigrahi, Third ventricular cavernous malformation, an unusual lesion, *British Journal of Neurosurgery*, Aug 2013
- [2]. Faropoulos K, Panagiotopoulos V, Partheni M, Tzortzidis F, Konstantinou D J, Therapeutic management of intraventricular cavernoma: case series and review of the literature, *Neurol Surg*, 2015 May
- [3]. Z. Milenkovic Z. Milenkovic, *Neurosurgical Clinic, Medical Faculty of Nis*, Postural intermittent headaches as the initial symptom of a cavernoma in the third ventricle, *Acta Neurochirurgica*, 30 September 2004
- [4]. A. Alves de Sousa Hôpital Santa Casa, hôpital Lifecenter, Belo Horizonte, Brésil, Cavernomes profonds (corps calleux, intraventriculaires, ganglions de la base, insulaires) et du tronc cérébral, expérience d'une série brésilienne, *j.neuchi* 2007.03.008
- [5]. Hiroaki Nagashima Kazuhiro Tanaka, Takashi Sasayama, Yusuke Okamura, Masaaki Taniguchi, Kyoko Otani, Takashi Yamasaki, Tomoo Itoh, Eiji Kohmura, A large cavernous malformation of the third ventricle floor: A case report Department of Neurosurgery, Kobe University Graduate School of Medicine, Kusunoki cho, Chuoku, Kobe, Japan, 2015.08.004
- [6]. Nikolay L. Martirosyan, MD, M. Yashar S. Kalani, MD, PhD, Peter Nakaji, MD, and Robert F. Spetzler, MD, The anterior interhemispheric approach to a third ventricular cavernous malformation Department of Neurosurgery, Barrow Neurological Institute and St. Joseph's Hospital and Medical Center, Phoenix, Arizona, October 14, 2015
- [7]. O.Vernet B.Rilliet, Cavernomes du troisième ventricule chez un enfant de 18 mois, service de neurochirurgie, centre hospitalier universitaire Vaudois (CHUV), Lausanne Suisse 2007
- [8]. Kivelev J, Niemelä M, Kivisaari R, et al. Intraventricular cerebral cavernomas: a series of 12 patients and review of the literature. *J Neurosurg*. 2010;112(1):140-9
- [9]. Itoh J, Usui K. Cavernous angioma in the fourth ventricular floor--case report. *Neurol Med Chir (Tokyo)*. 1991;31(2):100- 3
- [10]. Kendall B, Reider-Grosswasser I, Valentine A. Diagnosis of masses presenting within the ventricles on computed tomography. *Neuroradiology*. 1983;25(1):11- 22