

Ultrasound in The Assessment of Acute Scrotum

Nipun Gumber¹, Anand Prakash Verma², Hemant Kumar Mishra³,
M.C.Baberwal⁴, Sunil Kumar Agrawal⁵, Brijeshkumarsharma⁶

Abstract

Background: The acute scrotum is a medical emergency. The acute scrotum is defined as scrotal pain, swelling, and redness of acute onset. Scrotal abnormalities can be divided into three groups, which are extra-testicular lesion, intra-testicular lesion and trauma. This is a prospective analysis of 34 ultrasound (US) examination performed in patient arriving in the emergency room for scrotal pain. The objective of this article is to familiarize the reader with the US features of the most common and some of the least common scrotal lesions.

Methods: Between October 2016 and December 2016, 34 patients aged few month and older with scrotal symptoms, who underwent scrotal ultrasonography (US), were prospectively reviewed. The clinical presentation, outcome, and Ultrasound results were analyzed. The presenting symptoms including scrotal pain, painless scrotal mass or swelling, and trauma.

Results- Of the 34 patients, 19 (55.8%) presented with scrotal pain, 11 (32.3%) had painless scrotal mass or swelling and 4 (11.7%) had trauma. Of the 19 patients with scrotal pain, 8 had infection, 1 had testicular torsion, 1 had varicocele, 1 had atrophic testes, 1 had cryptorchidism, and 7 had unremarkable results. In the 4 patients who had history of scrotal trauma, US detected atrophy of testes in 1 patient, 1 had testicular abscess, 1 had torsion and 1 had unremarkable results.

Of the 11 patients who presented with painless scrotal mass or swelling, 10 had extra-testicular lesions and 1 had intra-testicular lesions. All the extra-testicular lesions were benign comprising of 4 hydrocele, 2 pyocele and 1 spermatocele, 2 inguinal hernia and 1 multiple epididymal cyst. Of the 1 intra-testicular lesion, was testicular infarction as a sequelae to epididymo-orchitis.

Conclusions: US provides excellent anatomic detail; when color Doppler and Power Doppler imaging are added, testicular perfusion can be assessed.

I. Background

The acute scrotum is a medical emergency defined as scrotal pain, swelling, and redness of acute onset⁽¹⁾. The differential diagnosis includes torsion, infection, trauma, tumour, and other rarer causes. The diagnostic evaluation begins with history-taking. Causes of scrotal pain include inflammation (epididymitis, epididymo-orchitis, abscess), testicular torsion, testicular trauma, and testicular cancer. Prompt diagnosis is required to differentiate surgically correctable lesions from abnormalities that can be adequately treated by medical therapy alone. Clinical symptoms and physical examination are often not enough for definite diagnosis due to pain and swelling that limit an accurate palpation of the scrotal contents. For patients presenting with a scrotal mass, it is critical to determine whether the mass is intra- or extra-testicular. This is important because the majority of intra-testicular lesions are malignant, while extra-testicular lesions are usually benign. US provides excellent anatomic detail; when color Doppler and power Doppler imaging are added, testicular perfusion can be assessed. The objective of this article is to familiarize the reader with the US features of the most common and some of the least common scrotal lesions.

II. Methods

The clinical presentation, outcome, and Ultrasound results were analyzed. The presentation symptoms including scrotal pain, painless scrotal mass or swelling, and trauma. The patients have performed an ultrasound examination positioned supine with proper support to the scrotum. The penis is displaced superiorly or superolaterally with a towel draped over it. Scanning is performed with a high frequency (8–15-MHz) transducer in sequential sagittal and transverse planes. Scanning of both testes is performed in sagittal and transverse planes with size measurements. Transverse side-by-side images of both testes should be obtained for comparison of echo texture, skin thickness, and color Doppler flow pattern. The epididymis should be imaged on the long and short axis. Color and power Doppler imaging are used to detect flow within the scrotal structures and to confirm symmetric or abnormal flow patterns.

III. Results And Discussion

Of the 34 patients, 19 (55.8%) presented with scrotal pain, 11 (32.3%) had painless scrotal mass or swelling and 4 (11.7%) had trauma. Of the 19 patients with scrotal pain, 8 had infection, 1 had testicular torsion,

1 had varicocele, 1 had atrophic testes, 1 had cryptorchidism, and 7 had unremarkable results. In the 4 patients who had history of scrotal trauma, US detected atrophy of testes in 1 patient, 1 had testicular abscess, 1 had torsion and 1 had unremarkable results. Of the 11 patients who presented with painless scrotal mass or swelling, 10 had extra-testicular lesions and 1 had intra-testicular lesions. All the extra-testicular lesions were benign comprising of 4 hydrocele, 2 pyocele and 1 spermatocele, 2 inguinal hernia and 1 multiple epididymal cyst. Of the 1 intra-testicular lesion, was testicular infarction as a sequelae to epididymo-orchitis. The acute scrotum is a medical emergency. The acute scrotum is defined as scrotal pain, swelling, and redness of acute onset. The differential diagnosis includes torsion, infection, trauma, tumour, and rarer causes. The diagnostic evaluation begins with history-taking. The patient should be asked about the exact course of events, the intensity of the pain, and, in particular, when the pain began and in the trauma what is the traumatic mechanism (blunt, penetrating, degloving, and electrical burn injuries to scrotal contents). Trauma often may result in hematoma, hydrocele, haematocele, torsion, testicular fracture, or testicular rupture.

Scrotal abnormalities can be divided into three groups, which are extra-testicular lesion, intra-testicular lesion and trauma. Causes of scrotal pain include inflammation (epididymitis, epididymo-orchitis, abscess), testicular torsion, testicular trauma, and testicular cancer. Prompt diagnosis is required to differentiate surgically correctable lesions from abnormalities that can be adequately treated by medical therapy alone⁽³⁾. Clinical symptoms and physical examination are often not enough for definite diagnosis due to pain and swelling that limit an accurate palpation of the scrotal contents⁽⁶⁾. For patients presenting with a scrotal mass, it is critical to determine whether the mass is intra- or extra-testicular. This is important because the majority of intra-testicular lesions are malignant, while extra-testicular lesions are usually benign. High resolution ultrasonography (US) combined with Colour Doppler ultrasonography (CDUS) has become the imaging modality of choice for evaluating scrotal diseases⁽¹⁾. US is helpful in differentiating extra- from intratesticular lesions⁽⁶⁾. Ultrasonography (US) is commonly performed for the assessment of scrotal abnormalities. It is ideal for the assessment of scrotal trauma, as it can be used for non-invasive evaluation of the scrotal contents, testicular integrity, and blood flow, as well as to visualize hematomas, other fluid collections, and foreign bodies.

Epididymitis And Epididymo-Orchitis

We found 8 cases of epididymo-orchitis mean age 40.6. The most common cause of scrotal pain is infection, which was mostly found in middle-aged men. Epididymitis and orchitis are either viral or bacterial infections of the epididymis and testis. Bacterial infections are very rare in children, unlike in adults. The infection usually originates in the bladder or prostate gland, spreads through the vas deferens and the lymphatics of the spermatic cord to the epididymis, and finally reaches the testis, causing epididymo-orchitis. Isolated orchitis is very rare. Bacterial epididymitis or epididymo-orchitis are the most common causes of scrotal pain in adults while torsion is more common in a younger age group⁽⁷⁾. Gray-scale US findings of these lesions, including enlarged epididymis and/or testis with heterogeneous echogenicity, are overlapping but color Doppler ultrasound findings are different. The inflamed epididymis and testis have increased blood flow (figure 1) whereas testicular torsion has decreased blood flow. The epididymal head is the most affected region, and reactive hydrocele and wall thickening are frequently present. Increased size and, depending on the time of evolution, decreased, increased, or heterogeneous echogenicity of the affected organ are usually observed. The inflammation produces increased blood flow within the epididymis, testis, or both.

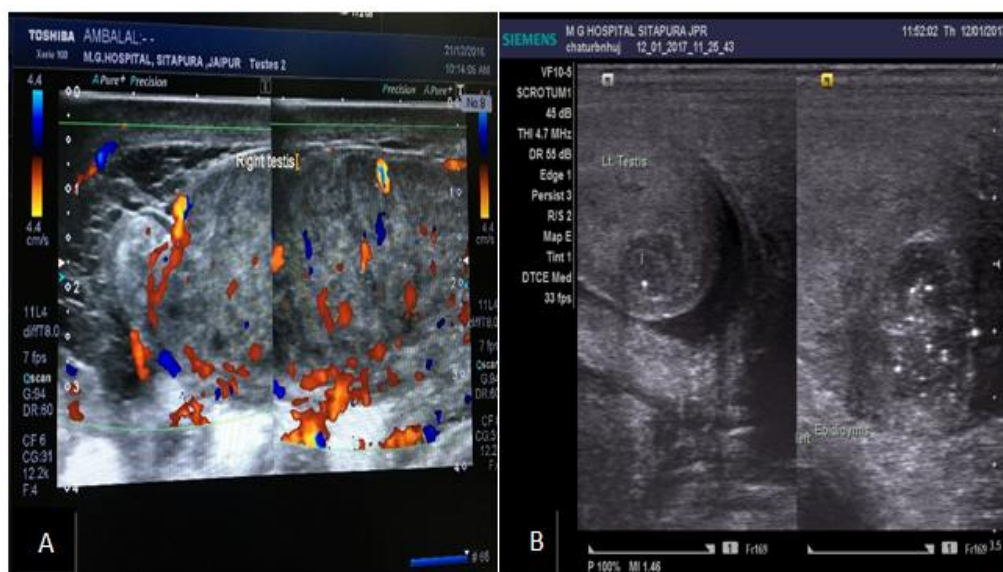

Figure1:(a)

Epididymo-Orchitis: longitudinal color Doppler scan shows increased vascularity and shows heterogeneous echo texture. (b) Longitudinal scan shows altered echo texture of testis and epididymis and increased vascularity was noted on color flow.

Testicular Torsion

We found 2 patient with testicular torsion with mean age of 18.5 years. One of these patients presented early between 1-4 hours after the onset of pain. US gave correct diagnosis leading to prompt surgical correction and the testes were salvaged. The other came late, between 3 and 6 days after their symptoms appeared. Orchiectomy was performed after diagnosis of missed torsion. Testicular torsion is a suddenly occurring rotation of a testis about its axis, resulting in twisting of the spermatic cord. Because the testicular parenchyma cannot tolerate ischemia for more than a short time, testicular torsion must be ruled out rapidly as the cause. Gray-scale USG along with color Doppler plays a pivotal role in differentiating testicular torsion from acute epididymo-orchitis and helps in avoiding unnecessary surgery. Both these conditions present with similar clinical features and there is a false positive rate of 50% for the diagnosis of testicular torsion based on clinical findings alone.

Two Types Of Testicular Torsion Are Described:

Intravaginal and extravaginal. Extravaginal torsion occurs exclusively in neonates⁽³⁾. Intravaginal torsion occurs within the tunica vaginalis and is due to the presence of a long and narrow mesentery or because of a bell-clapper deformity, which causes the testis to freely swing and rotate within the tunica vaginalis, much like a clapper inside a bell. Testicular salvage is possible if treatment is initiated within 4–6 h of torsion. Depending on the extent of twisting (which may range from 180 to 720°) and the duration of the torsion, a wide spectrum of findings may be seen in these cases. Differentiation between testicular torsion and epididymo-orchitis is a clinical challenge, since scrotal pain, swelling, and redness or tenderness are clinical symptoms common to these two entities. The usual teaching is that pain in testicular torsion has a sudden onset, whereas in orchitis it is more gradual. In the early phases of torsion (1–3 hours), testicular echogenicity appears normal. With progression, enlargement of the affected testis and increased or heterogeneous echogenicity are common findings. Sonographic evaluation of the spermatic cord is an essential part of the examination. The point of cord twisting can be identified at the external inguinal orifice. The intra-scrotal portion of the edematous cord appears as a round, ovoid, or curled echogenic extra-testicular mass, with the epididymal head wrapped around it. The orientation of the testis, epididymis, and cord may be inverted⁽⁴⁾. A definitive diagnosis of complete testicular torsion is made when blood flow is visualized on the normal side but is absent on the affected

Side.(Figure 2)

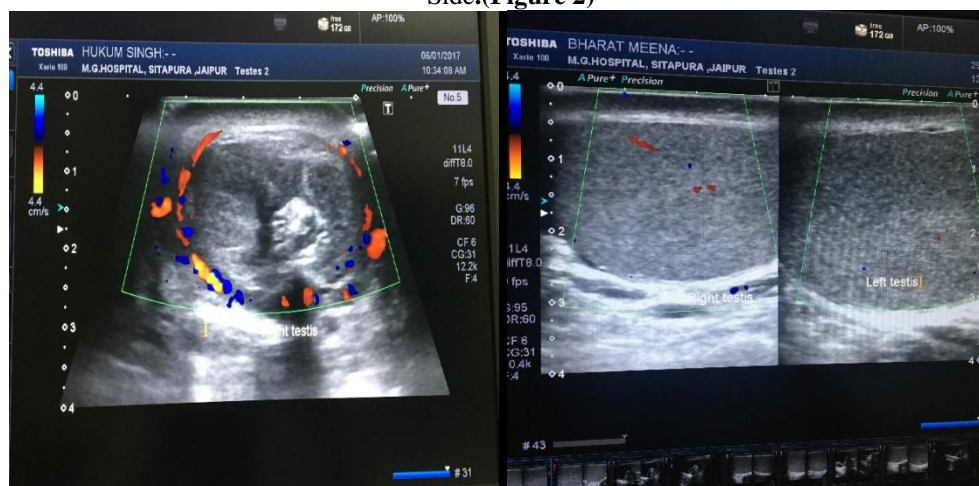


Figure 2:

Torsion- (A) **Subacute Torsion**(3 Days Of Pain)-Transverse Color Doppler Scan Shows Absent Flow Within The Testis With Surrounding Hyperaemia. (B) Color Doppler Shows Hypo Echoic And Enlarged Left Testis Showing Absence Of Color Flow With Normal Color Flow And Echo Pattern In The Right Testis.

Undescended Testes

We found one patient with undescended testes (age 2 year). Failure of the intra-abdominal testes to descend into the scrotal sac is known as cryptorchidism. The cryptorchid testis may be located at any point along the descent route. The prevalence of this condition is 9.2%–30% in premature infants and 3.4%–5.8% in

full-term infants⁽⁸⁾. The testes originate within the retro-peritoneum and migrate downward through the internal inguinal ring, inguinal canal, and external inguinal ring to the scrotum. Sonography is useful only for identifying testes in the inguinal canal (the most frequent location) or the pre-scrotal region just beyond the external inguinal ring and should be the initial imaging procedure.(figure3) The cryptorchid testis is usually smaller and isoechoic or hypo echoic relative to the normally located testis.

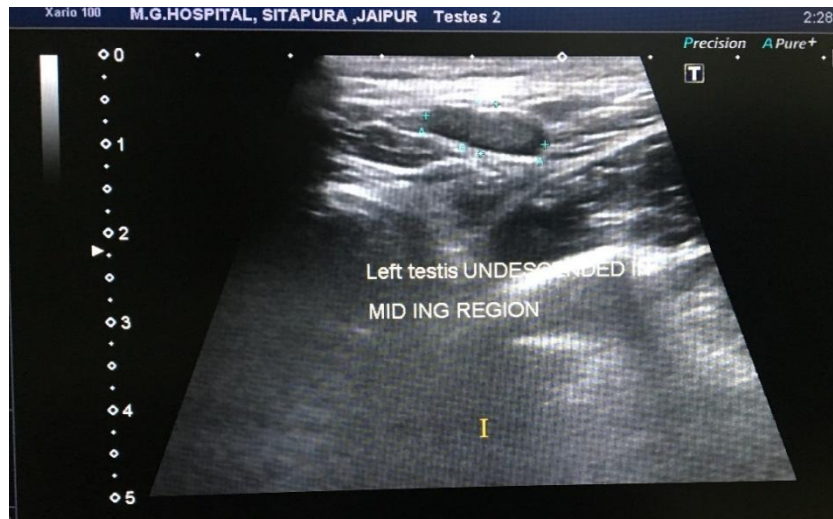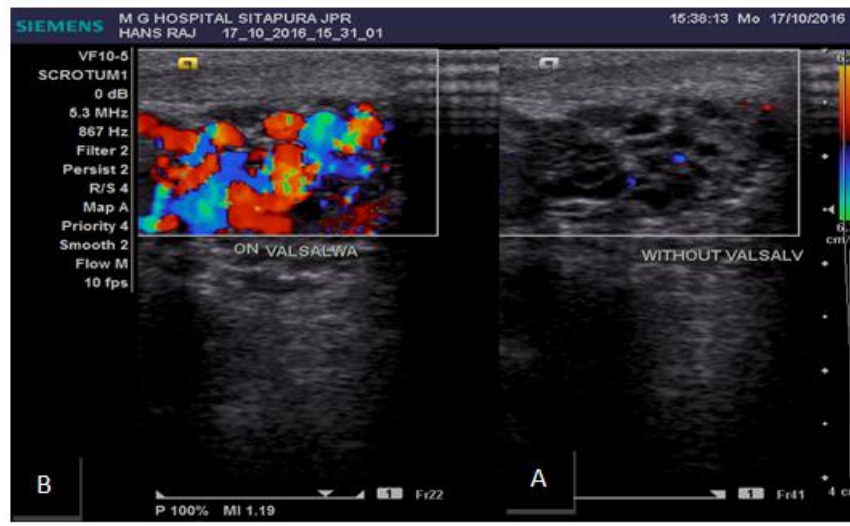


Figure 3

Testes In Inguinal Canal-longitudinal scan shows an elongated, ovoid, undescended testis.

Varicocele

We found in our analysis 1 patient with varicocele (age 30).Varicocele involves abnormal dilatation of veins(more than 2 mm in diameter) in the pampiniform plexus of the spermatic cord and is relatively common. The normal diameter of the veins of the pampiniform plexus ranges from 0.5 to 1.5 mm. Most cases are idiopathic; varicoceles are found mainly in adolescents and young adults and are more frequent on the left side because of the longer course of the left testicular vein, which joins the left renal vein at a right angle and, in some cases, because of the compression of the left renal vein by the left testicular artery⁽⁵⁾.At sonography, the dilated veins appear as tortuous, anechoic, tubular structures along the spermatic cord. On color and pulsed-wave Doppler images, venous flow is better demonstrated during the Valsalvamanuever. (figure4)



Varicocele- longitudinal and color Doppler images show serpentine, hypoechoic, dilated veins posterior to the testis. The blood flow in a varicocele is slow and detectd with low flow Doppler settings or the valsalva maneuver.

Hydrocele And Pyocele

We found 4 patients with hydrocele (mean age 30.25) and 2 patients with pyocele (mean age 57.5). Hydrocele, an abnormal collection of fluid between the visceral and parietal layers of the tunica vaginalis and/or along the spermatic cord, is the most common cause of painless scrotal swelling in children. In the normal scrotum, 1–2 mL of serous fluid may be observed in the potential tunica vaginalis cavity and should not be mistaken for hydrocele. Virtually all hydroceles are congenital in neonates and infants and associated with a patent processus vaginalis, which allows peritoneal fluid to enter the scrotal sac⁽⁹⁾. Up to 50% of acquired hydroceles are due to trauma⁽¹⁰⁾, and hydroceles may occur in up to 25% of patients with major trauma⁽¹¹⁾. Pyocele results from rupture of an abscess into an existing hydrocele or directly into the space between the layers of the tunica vaginalis. It contains internal echoes, septations and loculations. Thickening of the scrotal skin and calcifications may be seen in chronic cases. (figure 5)

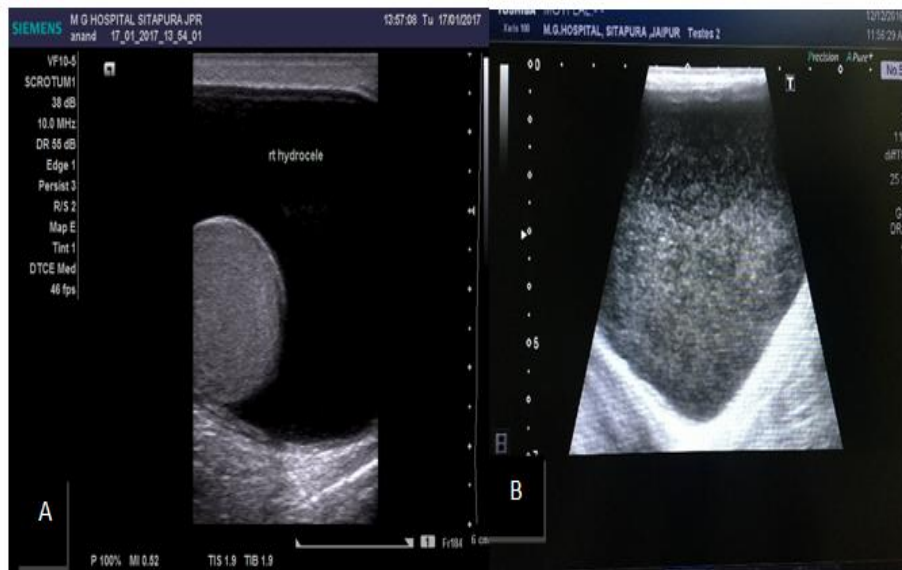

Figure 5:

Hydrocele-(a) Transverse scan shows hydrocele anterolaterally with attachment of testis to tunica vaginalis posteriorly. (b)

Pyocele- Transverse scan shows fluid collection with internal echoes

Inguinal Hernia

We found 2 inguinal hernia (mean age 55). Inguinal-scrotal hernia is defined as the passage of intestinal loops and/or omentum into the scrotal cavity. Physical examination is sufficient to enable diagnosis in most cases. Nevertheless, US examination (which has replaced plain radiography) is indicated in patients with inconclusive physical findings, in patients with acute scrotum, and to investigate contralateral involvement in patients in whom only a unilateral hernia is clinically evident⁽¹²⁾. At gray-scale US, the scrotum is partially occupied by one or more round structures containing air bubbles or fluid. The diagnosis of hernia is achieved by visualization of air bubble movement and/or intestinal peristalsis during the real-time examination. The herniated omentum is seen as a highly echogenic structure. We routinely use color or power Doppler imaging in inguinal-scrotal hernia to investigate intestinal and testicular perfusion.

Spermatocele And Epididymal Cysts

We found 1 case of spermatocele and 1 case of epididymal cyst. Spermatoceles are more common than epididymal cysts. Both are thought to result from dilatation of the epididymal tubules, but the contents of these masses differ⁽¹³⁾. Cysts contain clear serous fluid, whereas spermatoceles are filled with spermatozoa and sediment containing lymphocytes, fat globules, and cellular debris, giving the fluid a thick, milky appearance⁽¹⁶⁾. Both lesions may result from prior episodes of epididymitis or trauma. Spermatoceles and epididymal cysts appear identical on sonography: anechoic, circumscribed masses with no or few internal echoes; loculations and septations are often seen. Rarely a spermatocele may be hyper-echoic. Differentiation between a spermatocele and epididymal cyst is rarely important clinically. Spermatoceles almost always occur in the head of the epididymis, whereas epididymal cysts arise throughout the length of the epididymis. (figure 6)

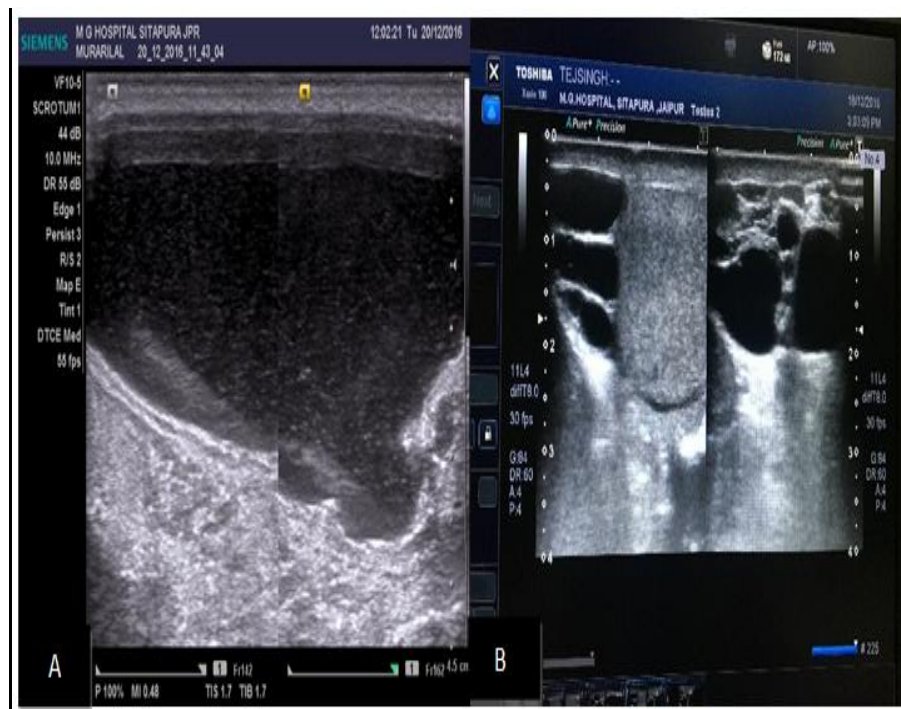


Figure-6:(a)

Spermatocele- longitudinal scan shows a large cyst containing internal echoes in the head of the epididymis. (b)
Epididymal Cyst- longitudinal scan shows multiple cyst in the head and body of epididymis.

Trauma

In the our study we analyzed 4 patients with scrotal trauma , US detected atrophy of testes in 1 patient, 1 had testicular abscess as a sequelae to epididymo-orchitis,1 had torsion and 1 had unremarkable result.All 4 patients presented with blunt injuries ie. Sporting activities and motocyclist trauma. Blunt injuries are noninvasive injuries from high energy transferred during contact with a solid object (e.g., from a kick to the groin). The main mechanism of injury in blunt trauma is crushing of the testis against the symphysis pubis or between the thighs. Hematoceles is similar to hydroceles, hematoceles are complex collections that separate the visceral and parietal layers of the tunica vaginalis. Like hematomas, they are acutely echogenic and become more complex and more hypoechoic with age. The lesions are usually focal, may be multiple, and may be hyperechoic (in acute bleeding) or hypoechoic (as the hemorrhage ages) and lack vascularity. The fluid in a complex hematoma may be heterogeneous. Hematomas of the scrotal wall may appear as focal thickening of the wall or as fluid collections within the wall.

A testicular fracture appears as a linear hypoechoic band that extends across the testicular parenchyma and represents a break in the normal testicular architecture. The overall contour remains smooth, as the testicular shape and the tunica albuginea are maintained. Doppler imaging is used to determine vascular integrity.In testicular rupture, there is hemorrhage and extrusion of testicular contents into the scrotal sac⁽¹⁵⁾. Discontinuity of the echogenic tunica albuginea is indicative of testicular rupture and necessitates emergent surgery. In this type of injury, US images also demonstrate poorly defined testicular margins and heterogeneous echo texture, with focal hyperechoic or hypoechoic areas in the testicular parenchyma corresponding to areas of hemorrhage or infarction. Associated findings may include scrotal wall thickening and hematocele.

Color and duplex Doppler images may show decreased flow or no flow.Testicular abscess are usually a complication of epididymo-orchitis, they may also result from an undiagnosed testicular torsion or a primary pyogenic orchitis. Infectious causes of abscess formation are mumps, small pox, scarlet fever, influenza, typhoid, sinusitis, osteomyelitis, and appendicitis.(figure7)

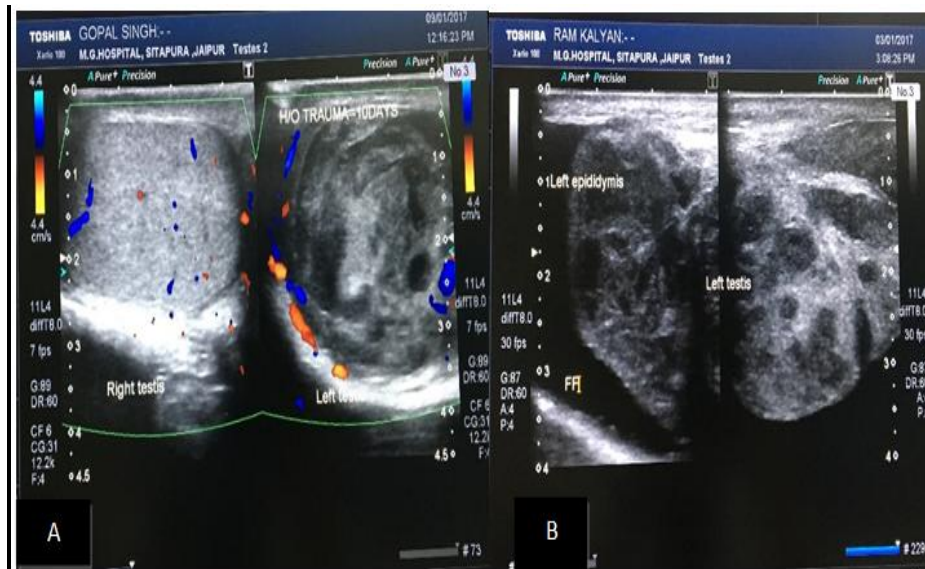


Figure 7:

Testicular Trauma: Spectrum of appearances-(a)patient had trauma 10 days back. Longitudnal scan showing areas of altered echogenicity, corresponding to areas of infarction. Only peripheral vascularity is noted.(b) Testicular abscess formation post epididymo-orchitis.

IV. Conclusions

Gray-scale USG is an accurate, fast and useful imaging modality for the imaging of scrotal lesions. Gray-scale USG can distinguish between intratesticular or extra testicular lesions and also aid in the characterization of various lesions. Color Doppler enhances the visualization of varicoceles. Color Doppler USG is the modality of choice to differentiate testicular torsion from inflammatory conditions and can thus help in avoiding unnecessary surgical explorations.

References

- [1]. McAndrew HF, Pemberton R, Kikiros CS, Gollow I: The incidence and investigation of acute scrotal problems in children. *PediatrSurgInt* 2002, 18:435-437.
- [2]. Dogra VS, Gottlieb RH, Oka M, et al: Sonography of the scrotum. *Radiology* 2003, 227(1):18-36.
- [3]. Pinto A, Caranci F, Romano L, Carrafiello G, Fonio P, Brunese L: Learning from errors in radiology: a comprehensive review. *Semin Ultrasound CT MR* 2012, 33(4):379-382.
- [4]. Deurdulian C, Mittelstaedt CA, Chong WK, Fielding JR: US of acute scrotal trauma: optimal technique, imaging findings, and management. *Radiographics* 2007, 27(2):357-369.
- [5]. Niedzielski J, Paduch D, Raczynski P: Assessment of adolescent varicocele. *Pediatr Surg Int* 1997, 12:410-413.
- [6]. Blaivas M, Brannam L: Testicular ultrasound. *Emerg Med Clin North Am* 2004, 22(3):723-748, ix.
- [7]. Dogra V, Bhatt S: Acute painful scrotum. *RadiolClin North Am* 2004, 42(2):349-63.
- [8]. Nguyen HT, Coakley F, Hricak H: Cryptorchidism: strategies in detection. *Eur Radiol* 1999, 9:336-343.
- [9]. Martin LC, Share JC, Peters C, Atala A: Hydrocele of the spermatic cord: embryology and ultrasonographic appearance. *Pediatr Radiol* 1996, 26:528-530.
- [10]. Baud C, Veyrac C, Couture A, Ferran JL: Spiral twist of the spermatic cord: a reliable sign of testicular torsion. *Pediatr Radiol* 1998, 28:950-954.
- [11]. Rubin JM, Bude RO, Carson PL, Bree RL, Adler RS: Power Doppler US: a potentially useful alternative to mean frequency-based color Doppler US. *Radiology* 1994, 190:853-856.
- [12]. Chou TY, Chu CC, Diau GY, Wu CJ, Gueng MK: Inguinal hernia in children: US versus exploratory surgery and intraoperative contralateral laparoscopy. *Radiology* 1996, 201:385-388.
- [13]. Middleton WD, Thorne DA, Melson GL: Color Doppler ultrasound of the normal testis. *AJR Am J Roentgenol* 1989; 152:293-297.
- [14]. Siegel MJ: The acute scrotum. *Radiol Clin North Am* 1997, 35(4):959-976.
- [15]. Jeffrey RB, Laing FC, Hricak H, McAninch JW: Sonography of testicular trauma. *AJR Am J Roentgenol* 1983, 141:993-995.
- [16]. Krone KD, Carroll BA: Scrotal ultrasound. *Radiol Clin North Am* 1985; 23:121-139.
- [17]. D'Andrea et al.: US in the assessment of acute scrotum. *Critical Ultrasound Journal* 2013 5(Suppl 1):S8.
- [18]. Bhardwaj Patiala: Role of Color Doppler in Scrotal Lesions. *Indian J Radiol Imaging* August 2009, 19(3):187-190.