

## A Prospective Clinical Case Study to Evaluate the Effect of Topical 0.05% Cyclosporine in Treatment of Non-Necrotizing Herpes Stromal Keratitis Unresponsive To Topical 1% Prednisolone

Manpreet Kaur<sup>1</sup>, Harsimran Singh<sup>2</sup>, Heena Rajput<sup>3</sup>, Ishwar Singh<sup>4</sup>,  
Monika Kharbanda<sup>5</sup>

<sup>1</sup>(Junior Resident, Department of Ophthalmology, Rajindra Hospital, Patiala, Punjab, India) 9914248221

<sup>2</sup>(Assistant Professor, Department of Ophthalmology, Rajindra Hospital, Patiala, Punjab, India) 9915271946

<sup>3</sup>(Junior Resident, Department of Ophthalmology, Rajindra Hospital, Patiala, Punjab, India) 9646875563

<sup>4</sup>(Assistant Professor, Department of Ophthalmology, Rajindra Hospital, Patiala, Punjab, India) 9814210203

<sup>5</sup>(Senior Resident, Department of Ophthalmology, Rajindra Hospital, Patiala, Punjab, India) 9814849055

---

### Abstract :

**Purpose:** To evaluate the safety and efficacy of 0.05% Cyclosporine (Restasis by Allergan, Hydroeyes by Lupin) on the patients with herpes simplex virus nonnecrotizing stromal keratitis refractory to topical 1% prednisolone.

**Methods:** This prospective clinical case study with 0.05% Cyclosporine was conducted on 28 eyes of 28 patients diagnosed with herpes simplex virus nonnecrotizing stromal keratitis refractory to topical 1% prednisolone attending the ophthalmology OPD, Rajindra Hospital Patiala. Outcome criteria was defined as decrease in corneal haze and improvement of the visual acuity. Recurrence defined as the re-appearance of stromal infiltration after 3 months of the treatment.

**Results:** There was improvement in corneal haze in 24 out of 28 patients after 4 weeks along with improvement of at least 2 lines on Snellen's chart. There was no improvement in 4 eyes having already scarred cornea. 5 eyes experienced recurrence at 3 months and thereafter.

**Conclusion:** Herpes simplex virus stromal keratitis can be treated effectively with topical cyclosporine, particularly in cases refractory to topical prednisolone and was not associated with any adverse effects.

**Keywords:** cyclosporine 0.05% eye drops, herpes stromal keratitis, prednisolone 1% eye drops

---

### I. Introduction

Herpes simplex virus, despite years of investigation, has remained a formidable opponent for the ophthalmologist and affected patient. It is known for causing myriad of corneal manifestations from classic dendritic epithelial disease to fulminant necrotizing stromal keratitis leading to corneal perforation.[1] With the global incidence of roughly 1.5 million, including 40,000 new cases of severe monocular visual impairment or blindness each year HSV keratitis is a leading cause of corneal opacification and an important indication for penetrating keratoplasty.[2,3] The virus is enveloped with a cuboidal capsule, has linear double-stranded DNA structure and is classified as an  $\alpha$ -member of the Herpesviridae family. Primary infection, without previous viral exposure, usually occurs in childhood and is spread by droplet transmission, or by direct inoculation. Mostly they are subclinical or cause only mild fever, malaise and upper respiratory tract symptoms. Blepharitis and follicular conjunctivitis may develop but are usually mild and self-limited.[4]

After primary infection the virus is carried to the sensory ganglion establishing latent infection. Latent virus is incorporated in host DNA and cause periodical Subclinical reactivation, during which HSV is shed and patients are contagious.[4] A variety of stressors such as fever, hormonal change, ultraviolet radiation, trauma, or trigeminal injury may cause clinical reactivation, when the virus replicates and is transported in the sensory axons to the periphery. The pattern of disease depends on the site of reactivation, which may be remote from the site of primary disease. Hundreds of reactivations can occur during a lifetime.[4]

A normal cornea is densely innervated, but lacks blood vessels. The chronic viral reactivations can lead to neurotrophic keratitis, a degenerative condition. Subsequent episodes not only damage nerves, leading to decreased corneal sensation (corneal hypoesthesia), but also lead to angiogenesis, and neovascularization.[5,6] Decreased corneal sensation leads to loss of the corneal blink reflex.[5] This immunomediated reaction occurs as a result of cytokines released by CD4<sup>+</sup> T cells.[7,8,9]

SK on physical examination appears opaque or whitened, due to stromal infiltration.[10,11] The pattern of stromal infiltration may be central or peripheral, focal or multifocal, superficial or full thickness. Wessely-

type immune rings, if present, support the diagnosis.<sup>[12]</sup> Keratitis has also been shown to cause dryness in patients with stromal infection.[5] HSK lesions, which are immunoinflammatory in nature, can recur throughout life and often cause progressive corneal scarring resulting in visual impairment.[13] Current treatment involves broad local immunosuppression with topical steroids along with antiviral coverage.[13] While recurrent episodes of HSK can lead to stromal opacification, long-term use of antiviral drugs to prevent future episodes can increase the risk of resistance and toxicity.[14,15,16] Corticosteroids have significant side effects, and antivirals are only beneficial if replicating virus is present.[3] Acyclovir is not effective against the inflammatory stage of SK, as there is little virus to be found during peak inflammation. Since stromal response is immunomediated, steroids can help decrease recurrence, but they do not eliminate the virus.[17,18] Immune regulatory drugs, such as cyclosporine A, present attractive alternatives to managing HSV stromal keratitis, given the immune-mediated pathogenesis of stromal disease.[3]

Cyclosporin is a lipophilic cyclic polypeptide which produces calcium-dependent, specific, reversible inhibition of transcription of interleukin-2 and several other cytokines, most notably in T helper lymphocytes. This reduces the production of a range of cytokines, inhibiting the activation and/or maturation of various cell types, including those involved in cell-mediated immunity.[19] Thus, cyclosporin has immunosuppressive properties and has been used successfully as a systemic immunomodulator for more than two decades, and numerous studies have investigated its mechanisms of action. In 2003 an ophthalmic formulation, cyclosporine 0.05% ophthalmic emulsion, was approved by the FDA to treat dry eye disease. Topical cyclosporine emulsion has also been investigated for treatment of other ocular surface disorders that may have an immune-based inflammatory component. In these trials, cyclosporine 0.05% ophthalmic emulsion has shown efficacy for management of posterior blepharitis, ocular rosacea, post-LASIK dry eye, contact lens intolerance, atopic keratoconjunctivitis, graft-versus-host disease, and herpetic stromal keratitis. As these disorders are often refractory to other available treatments, ophthalmic cyclosporine is a welcome nontoxic adjunct or replacement to potentially toxic topical or systemic immunosuppressive therapies.[20] In this study we evaluated the effect of 0.05% Cyclosporine (Restasis by Allergan, Hydroeyes by Lupin) on the patients with herpes simplex virus nonnecrotizing stromal keratitis unresponsive to topical 1% prednisolone.

## **II. Material & Methods**

This prospective case study clinical trial was conducted on 28 eyes of 28 patients attending the ophthalmology OPD of Rajindra hospital, Patiala from March 2016 to March 2017 who had herpes simplex virus non-necrotizing stromal keratitis and were unresponsive to topical 1% prednisolone treatment being given to them for at least 6 weeks. Written informed consent was obtained from all patients and they were explained about the possible consequences. We interviewed the patient before hand to obtain information like personal data, contact number, any medical or ocular history, any history of drug allergy.

### **Inclusion Criteria**

1. Patients unresponsive to topical 1% Prednisolone (a minimum of 6 weeks treatment)

### **Exclusion Criteria**

1. Patients having corneal epithelial defect
2. Pregnant & Lactating mothers
3. Patients with Allergy to Cyclosporine

Age, Gender, affected eye were noted down. Best corrected visual acuity (BCVA) by Snellen's chart, Corneal sensation testing, IOP (measured by applanation tonometry) and detailed biomicroscopic anterior segment examinations were all done prior to the treatment. All patients were treated with topical 0.05% Cyclosporine as follows: 2 times a day of topical 0.05% Cyclosporine, in addition to the topical 1% Prednisolone (rapid tapering in 2 weeks) they were using for 15 days, and then 2 times a day of topical Cyclosporine 0.05% after topical 1% Prednisolone was discontinued. Visual acuity and slit-lamp appearance were evaluated every two weeks for at least three months. Intraocular pressure and corneal sensitivity were also examined routinely. 28 eyes of 28 patients were included in the study, of these 16 (57%) were male and 12 (43%) were female. The average age of patients was  $27.39 \pm 5.78$  years. Corneal haze was in right eye in 18 patients whereas 10 patients had it in their left eye. The average duration of topical 1% Prednisolone therapy was 1.6 months.

BCVA (Best Corrected Visual Acuity) was assessed on Snellen's chart every 2 weeks

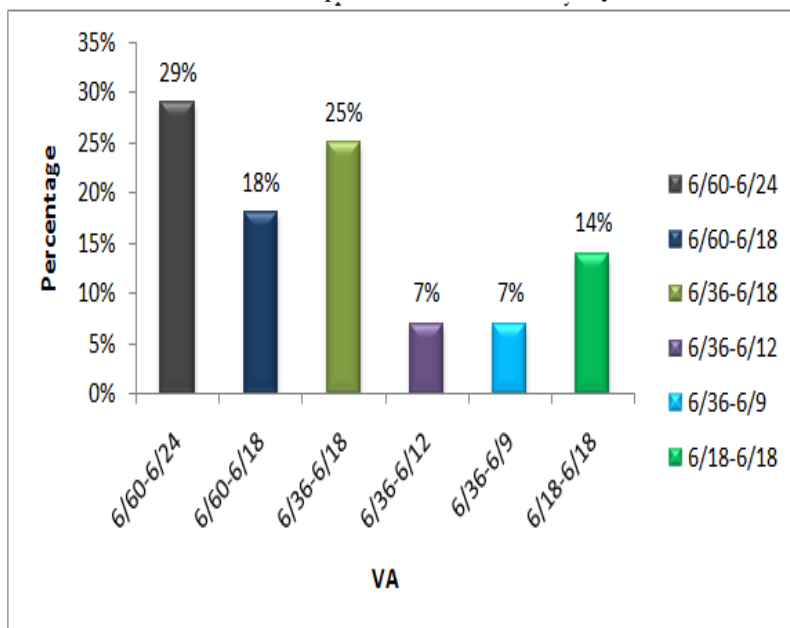
**Corneal haze was graded as follows:-**

1. Grade I- Pupil and iris details visible.
2. Grade II- Iris details partially obscured.
3. Grade III- Iris details completely obscured.

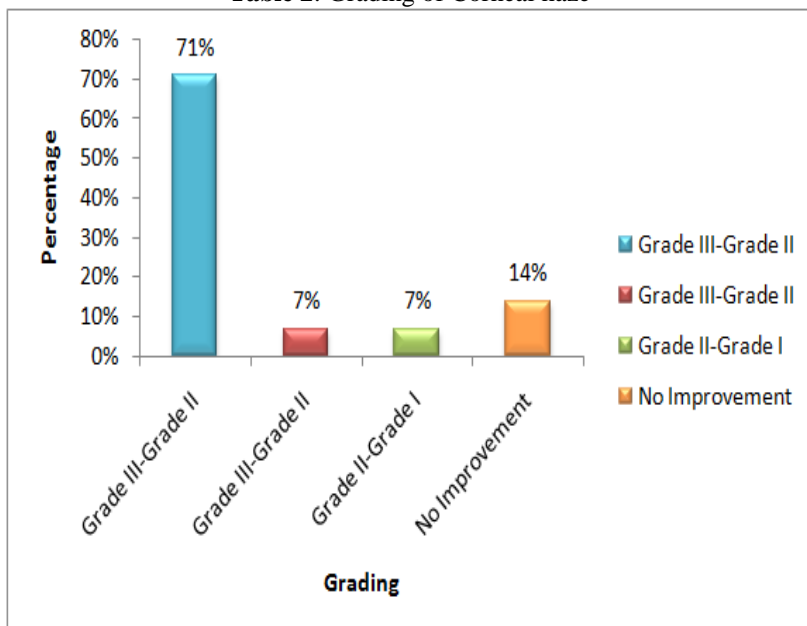
IOP was measured at time of initiating the Cyclosporine drops, after 4 weeks and after 3 months of treatment. Corneal sensitivity was checked before initiating the Cyclosporine treatment and after 3 months of it.

**II. Indentations and equations**

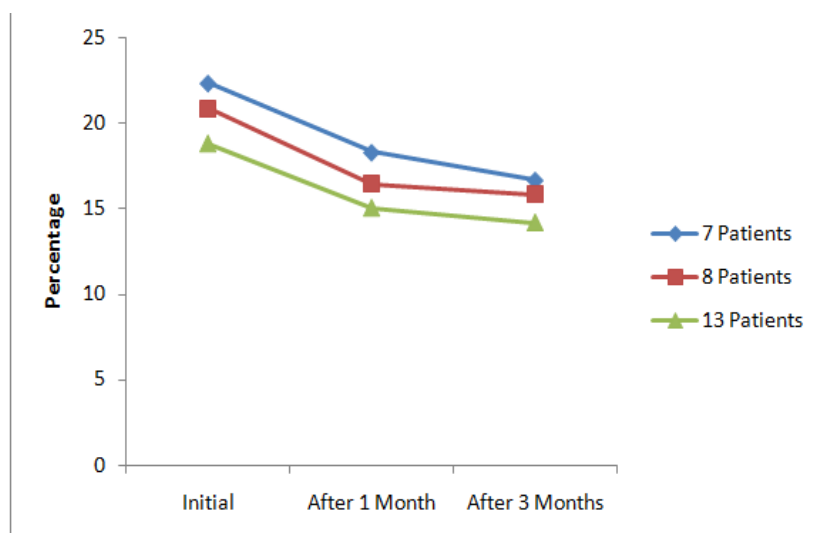
**Table 1: Improvement in Visual acuity**



**Table 2: Grading of Corneal haze**



**Table 3: IOP**



| Difference               | P value    |            |             |
|--------------------------|------------|------------|-------------|
|                          | 7 Patients | 8 Patients | 13 Patients |
| Initial & After 1 Month  | 0.05       | 0.03       | 0.03        |
| Initial & After 3 Months | 0.01       | 0.02       | 0.01        |

IOP value was significantly lowered in cases in which it had risen during treatment by prednisolone 1% eyedrops. It remained stable for next treatment period and no separate pressure lowering drug was required. No major adverse effect was noted except complaint of severe burning by 5 patients but it did not lead to discontinuation of the Cyclosporine eyedrops. Corneal sensitivity also improved after 3 months of cyclosporine therapy. Out of the 28 patients 4 had recurrence after 3 months of stopping the cyclosporine therapy, which was given for a period of 4-6 months.

### III. Discussion

A study was conducted by Sanjay N. Rao, MD, University of Chicago, Chicago, Illinois and was presented at the American Academy of Ophthalmology Meeting, October 2004, in New Orleans, Louisiana to assess the efficacy of topical cyclosporine 0.05% (Restasis) in patients with herpes simplex virus nonnecrotizing stromal keratitis unresponsive to topical prednisolone. This series suggests that herpes simplex virus stromal keratitis can be treated effectively with topical cyclosporine, particularly in cases that are not responsive to topical prednisolone. [21]

Another study titled Topical cyclosporin as an adjunct to topical acyclovir treatment in herpetic stromal keratitis conducted by Gündüz K. · Özdemir O. concluded that topical cyclosporin can be a valuable adjunct to acyclovir treatment in herpetic stromal keratitis. [22] A study titled Treatment of HSV-1 stromal keratitis with topical cyclosporin A: a pilot study. Heiligenhaus A, Steuhl KP suggests that HSV stromal keratitis can be treated successfully with CsA eyedrops, especially in non-necrotizing disease. CsA may be particularly helpful in the presence of steroid glaucoma, herpetic corneal ulcers, and to taper off topical corticosteroids. [23] Another study by Guang-Yong Qin, Li Liu, Xiang Wu of Huangshi Aier Eye Hospital, Huangshi 435002, Hubei Province, China from January 2011 to January 2012 concluded that For herpes simplex virus keratitis patients, using cyclosporin A eye drops can be safe and effective, but the cure time is long. [24]

An article titled Topical Ophthalmic Cyclosporine: Pharmacology And Clinical Uses by Dr. Eric Donnenfeld stated that Topical cyclosporine emulsion has also been investigated for treatment of other ocular surface disorders that may have an immune-based inflammatory component. In these trials, cyclosporine 0.05% ophthalmic emulsion has shown efficacy for management of various diseases including herpetic stromal keratitis. And also ophthalmic cyclosporine is a welcome nontoxic adjunct or replacement to potentially toxic topical or systemic immunosuppressive therapies. [25]

### IV. Conclusion

By this series it can be suggested that herpes simplex virus stromal keratitis can be treated effectively with topical cyclosporine, particularly in cases refractory to topical prednisolone. and was not associated with any adverse effects. The small number of patients was the short coming of the study.

## References

- [1]. Krachmer > Volume 1 - Fundamentals And Medical Aspects Of Cornea And External Disease > Part Vii - Diseases Of The Cornea > Section 4 - Corneal Infections > Chapter 79 - Herpes Simplex Keratitis
- [2]. [Http://Www.Sciencedirect.Com/Science/Article/Pii/S0039625713000301](http://www.sciencedirect.com/science/article/pii/S0039625713000301)
- [3]. Survey Of Ophthalmology, Volume 58, Issue 3, May–June 2013
- [4]. Management Of Herpes Simplex Virus Stromal Keratitis: An Evidence-Based Review
- [5]. [Https://Doi.Org/10.1016/J.Survophthal.2008.12.004](https://doi.org/10.1016/j.survophthal.2008.12.004)
- [6]. Kanski 8th Edition>Cornea>Herpes Simplex Keratitis,Pg.184
- [7]. Gallar J, Tervo Tm, Neira W. Selective Changes In Human Corneal Sensation Associated With Herpes Simplex Virus Keratitis. Invest Ophthalmol Vis Sci. 2010;51(9):4516–4522. [PubMed]
- [8]. Hamrah P, Cruzat A, DastjerdiMh, Et Al. Corneal Sensation And Subbasal Nerve Alterations In Patients With Herpes Simplex Keratitis: An In Vivo Confocal Microscopy Study. Ophthalmology. 2010;117(10):1930–1936. [Pmc Free Article] [PubMed]
- [9]. Al-DujailiLj, Clerkin Pp, Clement C, Et Al. Ocular Herpes Simplex Virus: How Are Latency, Reactivation, Recurrent Disease And Therapy Interrelated? Future Microbiol. 2011;6(8):877–907. [Pmc Free Article] [PubMed]
- [10]. Tang Q, Chen W, Hendricks Rl. Proinflammatory Functions Of Il-2 In Herpes Simplex Virus Corneal Infection. J Immunol. 1997;158(3):1275–1283. [PubMed]
- [11]. Tang Q, Hendricks Rl. Interferon  $\Gamma$  Regulates Platelet Endothelial Cell Adhesion Molecule 1 Expression And Neutrophil Infiltration Into Herpes Simplex Virus-Infected Mouse Corneas. J Exp Med. 1996;184(4):1435–1447. [Pmc Free Article] [PubMed]
- [12]. ReidyJj. 2011–2012 Basic And Clinical Science Course – Section 8: External Disease And Cornea. San Francisco: American Academy Of Ophthalmology; 2011.
- [13]. Kaye S, Choudhary A. Herpes Simplex Keratitis. ProgRetin Eye Res. 2006;25(4):355–380. [PubMed]
- [14]. Meyers R: Immunology Of Herpes Simplex Virus Infection. IntOphthalmolClin 1975; 15:37. [Https://Doi.Org/10.1016/J.Preteyeres.2012.08.002](https://doi.org/10.1016/j.preteyeres.2012.08.002)
- [15]. Farooq Av, Shukla D. Herpes Simplex Epithelial And Stromal Keratitis: An Epidemiologic Update. SurvOphthalmol. 2012;57(5):448–462. [Pmc Free Article] [PubMed]
- [16]. Lairson Dr, Begley Ce, Reynolds Tf, Wilhelmus Kr. Prevention Of Herpes Simplex Virus Eye Disease: A Cost-Effectiveness Analysis. Arch Ophthalmol. 2003;121(1):108–112. [PubMed]
- [17]. LiesegangTj, Melton Lj, Daly Pj, Daly Pj, Ilstrup Dm. Epidemiology Of Ocular Herpes Simplex: Incidence In Rochester, Minn, 1950 Through 1982. Arch Ophthalmol. 1989;107(8):1155–1159. [PubMed]
- [18]. Tsatsos M, Macgregor C, Athanasiadis I, Moschos Mm, Hossain P, Anderson D. Herpes Simplex Virus Keratitis: An Update Of The Pathogenesis And Current Treatment With Oral And Topical Antiviral Agents. ClinExpOphthalmol. 2016 Jun 8; Epub. [PubMed]
- [19]. Wilhelmus Kr, Gee L, Hauck Ww, Et Al. Herpetic Eye Disease Study: A Controlled Trial Of Topical Corticosteroids For Herpes Simplex Stromal Keratitis. Ophthalmology. 1994;101(12):1883–1896. [PubMed]
- [20]. Cyclosporin. A Review Of Its Pharmacodynamic And Pharmacokinetic Properties, And Therapeutic Use In Immunoregulatory Disorders. Drugs-1993 Jun;45(6):953-1040. Doi: 10.2165/00003495-199345060-00007.
- [21]. [Https://Www.Ncbi.Nlm.Nih.Gov/Pubmed/7691501](https://www.ncbi.nlm.nih.gov/pubmed/7691501)
- [22]. [Https://Doi.Org/10.1016/J.Survophthal.2009.02.002](https://doi.org/10.1016/j.survophthal.2009.02.002)
- [23]. Treatment Of Herpes Simplex Virus Stromal Keratitis Unresponsive To Topical Prednisolone 1% With Topical Cyclosporine 0.05% Doi: [Http://Dx.Doi.Org/10.1016/J.Ajo.2005.11.042](http://dx.doi.org/10.1016/j.ajo.2005.11.042)
- [24]. Topical Cyclosporin As An Adjunct To Topical Acyclovir Treatment In Herpetic Stromal Keratitis [Https://Doi.Org/10.1159/000268041](https://doi.org/10.1159/000268041)
- [25]. Treatment Of Hsv-1 Stromal Keratitis With Topical Cyclosporin A: A Pilot Study. Graefes Arch ClinExpOphthalmol. 1999 May;237(5):435-8
- [26]. Curative Effect Of Cyclosporin A Eye Drops On Treatment Of Herpetic Stromal Keratitis
- [27]. Guang-Yong Qin,LiLiu,Xiang Wu HuangshiAier Eye Hospital,Huangshi 435002,Hubei Province,China
- [28]. Donnenfeld E Pflugfelder Sc TopicalOphthalmicCyclosporine:Pharmacology And Clinical Uses. Survphthalmol 2009 54 3 321 338