

## Primary Enterolithiasis as a Cause of Sub Acute Intestinal Obstruction

Manish Kumar Gupta<sup>1</sup>, Manika Khare<sup>2</sup>, U B sharma<sup>3</sup>, K M Garg<sup>4</sup>

<sup>1</sup>Asst Professor, Dept Of General Surgery, JNU IMSRC, Jaipur.

<sup>2</sup>Asst Professor, Dept Of Pathology, JNU IMSRC, Jaipur.

<sup>3</sup>Professor & HOD, Dept Of Pathology, JNU IMSRC, Jaipur.

<sup>4</sup>Professor & HOD, Dept Of General Surgery, JNU IMSRC, Jaipur

**Abstract:** Primary enterolithiasis is a rare surgical ailment. The underlying cause is intestinal stasis. A 45-year-old female patient admitted with 5 years history of intermittent abdominal colics of less severity and shorter duration. There was history of emergency abdominal surgery 20 years back. The patient underwent laparotomy revealing three strictures in the distal ileum two feet proximal to ICJ, in between strictures dilated ileal segments harbor enteroliths. Resection and anastomosis of small bowel containing enteroliths was carried out.

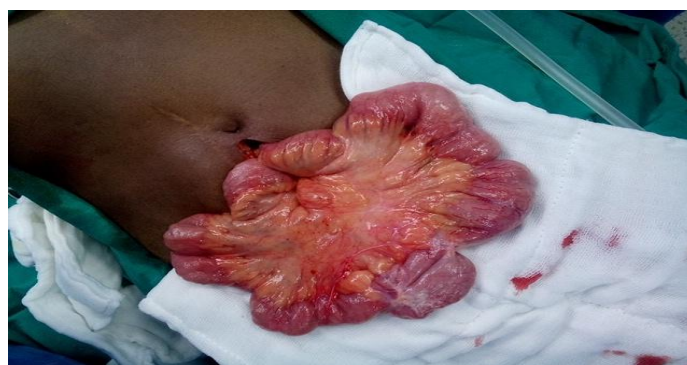**Keywords:** enterolithiasis, sub acute intestinal obstruction, laparotomy.

### I. Introduction

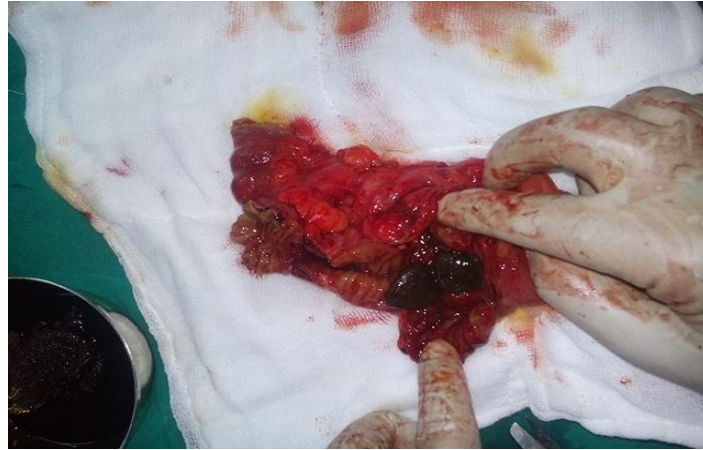Enterolithiasis or the presence of stone in the intestine is an uncommon clinical condition. Primary enteroliths arise due to the stasis of the intestinal contents, and the underlying pathologies include diverticular disease, blind pouches, intestinal stenosis, and strictures<sup>[1]</sup>. Intestinal stasis leads to the crystallization of food particles by calcium salt. The terminal ileum is the most common location in the small intestine because of its alkaline pH and high calcium concentration. There has been an increase in the incidence of enterolithiasis in recent times due to detection by the advancement in radiological imaging. Herein we report a case of enterolithiasis presented as sub acute intestinal obstruction.

### II. Case report

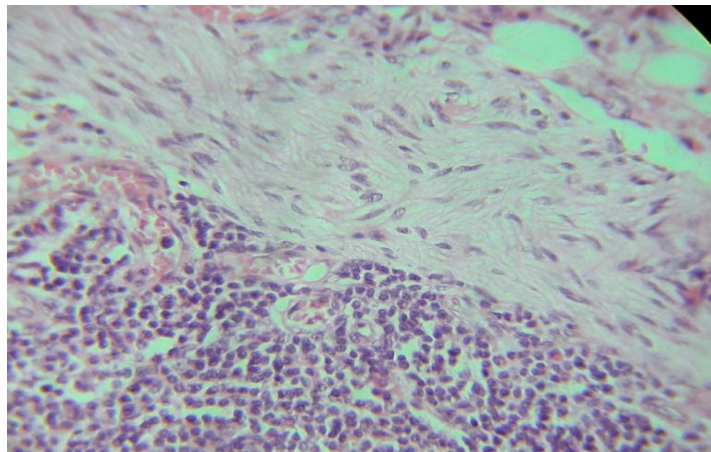
A 45 years old female was admitted with five days history of intermittent severe colicky central abdominal pain with bouts of vomiting. There was history of similar episodes of intermittent colicky abdominal pain in past five years, though pain used to be less severe in intensity and was of shorter duration. There was past history of emergency abdominal surgery 20 years back, details were not available. She also underwent URS for right mid-ureteric calculus nine months back. On examination there was slight central abdominal distension and bowel sounds were raised. Radiograph of abdomen was normal except faint radio-opaque shadows in right side of abdomen. Laparotomy revealed normal stomach, duodenum and gall bladder. There was a dilated ileal loop two feet proximal to ileo-caecal junction having three strictures (photo 1), an oblong hard structure was felt in this dilated loop. Resection and end to end anastomosis of affected bowel loop was done. On opening this affected ileal segment multiple black coloured hard stones were seen (photo 2) The histopathology of ileal loop revealed hypertrophy of muscularis propria with focal degeneration of muscle fibres along with chronic inflammatory infiltrate(photo 3)in the resected segment. Focal ulceration of mucosa was also seen (photo 4). There were no specific features present and in particular no evidence of crohn's disease, tuberculosis or an ischemic etiology was found. The patient is asymptomatic when last seen at 6 months follow up.



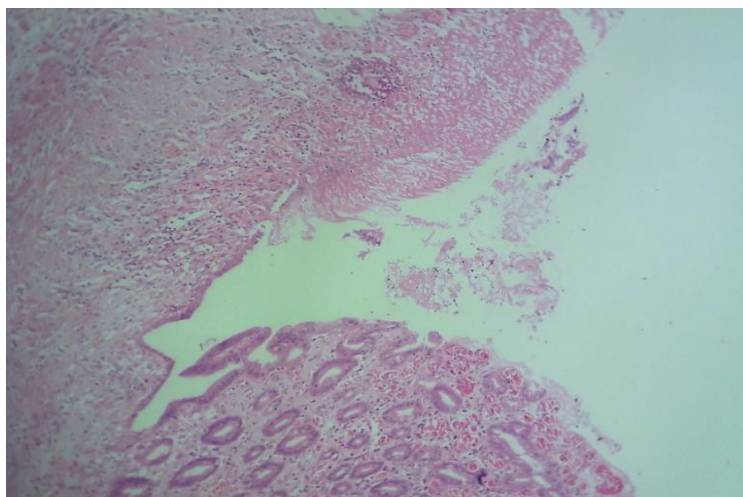
**Photo 1** - Showing three strictures with dilatation of intervening segments



**Photo 2** - Showing enteroliths in resected bowel loop



**Photo 3** - Hypertrophy of muscularis propria with focal degeneration of muscle fibres along with chronic inflammatory infiltrate



**Photo 5** - Focal ulceration of mucosa

### **III. Comments**

The exact incidence of enterolithiasis is not known because most cases are asymptomatic or they are not diagnosed or they remain underreported. The prevalence of enteroliths is reported to be 0.3% to 10% in various populations. The decreased motility or stasis of the bowel seems to be the crucial pathognomonic factor in the formation of enteroliths. The anatomic alterations of the gastrointestinal tract (e.g., diverticula, duplication cysts, or pathological conditions such as strictures due to bowel diseases like Crohn's disease or tuberculosis) may be associated with the stasis of the intestinal contents. The stasis of the contents in the intestine leads to

crystallization and subsequent formation of stone<sup>[3]</sup>. Bowel resection and anastomosis may also lead to blind loop formation and result in the continuous deposition of the intestinal contents. The examination of the stone mainly shows fecal material similar to a true primary enterolith<sup>[4]</sup>. The presence of an enterolith, even in the absence of intestinal obstruction, should warn us of the possibility of an intestinal stricture.

The most common factor involved in the development of an enterolith is stasis within the bowel as a result of altered endoluminal propagation and peristaltic functionality. Stasis occurs frequently at areas of intestinal diverticula, sites of intestinal anastomoses, Roux-en-Y sites, intestinal kinking (adhesions), incarcerated hernias, and at sites of intestinal strictures<sup>[1]</sup>. The microenvironment and luminal pH specific to each segment of the gut with varying digestive properties can result in crystallisation of different substances at different sites of the small intestine. Choleic acid aggregates and forms enteroliths at acidic pH whereas calcium enteroliths are formed at alkaline pH. Hence cholic acid enteroliths are seen in the proximal small intestine and calcium containing enteroliths are almost always seen in the distal ileum or colon. The presentation is usually non-specific with most enteroliths remaining asymptomatic. The enterolith tumbling through the bowel lumen can result in fluctuating subacute type of intestinal obstruction. They can also present as surgical emergencies like acute intestinal obstruction, hemorrhage, and bowel perforations. In the present case, the patient presented with features of sub acute intestinal obstruction due to the impacted faecal mass in the ileum that warranted a surgical management.

X-ray detection of enterolithiasis depends on the calcium content of the stone. The differential diagnosis includes gallstones, urolithiasis, calcified lymph nodes, and pancreatic calcifications. The most important radiological signs are typical dense rim with a pale core in oval, round, or rectangular shadows, “coin-end-on” appearance of the shadows, wide mobility of radio-opaque shadows in relation to the fixed structures in successive plain radiographs of the abdomen, and wide separation in one with closeting together in other radiographs. These stones may change their location on radiographs due to the peristaltic movements of the bowel. In summary, there is no evidence for the prophylactic treatment of asymptomatic enterolithiasis. Patients presenting with intestinal obstruction require laparotomy with stricturoplasty or segmental bowel resection. In the present case, the presence of a radio-opaque shadow that kept on changing its position posed a diagnostic dilemma, which was solved only after laparotomy.

#### **IV. Conclusion**

Enterolithiasis is a rare finding, but its incidence and prevalence has been on the rise in recent times. Stasis secondary to various underlying pathologies plays a significant role in the pathogenesis of this disease. Clinical diagnosis depends on the history and physical examination of the patient supported by radiological imaging. Most cases will require exploratory laparotomy because of multiple strictured bowel segments. Our patient was also having 3 strictures in the distal ileum. The possible pathophysiology behind the enterolithiasis is the stasis of digestive juices and food particles between the strictures. These food particles act as a nidus for stone formation, and crystallization occurs due to the inflammatory mechanism in the bowel because of chronic inflammation secondary to disease process.

#### **References**

- [1]. Gurvits G E, Lan G. Enterolithiasis .World J Gastroenterol. 2014;20:17819–17829.
- [2]. Tewari A, Weiden J, Johnson JO, et al.Small bowel obstruction associated with crohn’s enteroliths Emerg Radiol. 2013; 20:341–344. [PubMed]
- [3]. Sharma D, P Malhotra, P Goyal, and S S Minhas. Enterolith–presenting as acute intestinal obstruction. IOSR Journal of Dental and Medical Sciences (IOSR-JDMS). 2015; 1:38–40.
- [4]. Chaudhery B, Newman PA, Kelly MD. Small bowel obstruction and perforation secondary to primary enterolithiasis in a patient with jejunal diverticulosis. BMJ Case Rep. 2014;2014. doi: 10.1136/bcr-2014- 203833. PubMed PMID: 24626387; PubMed Central PMCID: PMC3962938.
- [5]. Singhal BM, Kaval S, Kumar P, Singh CP. Enterolithiasis: an unusual cause of small intestinal obstruction. Archives of International Surgery. 2013;3:137-141. doi:10.4103/2278-9596.122936
- [6]. Perathoner A, Kogler P, Denecke C, Pratschke J, Kafka-Ritsch R, Zitt M. Enterolithiasis associated ileus in Crohn’s disease. World J Gastroenterol. 2012; 18:6160-3. doi:10.3748/wjg.v18.i42.6160. PubMed PMID: 23155347