

Bednar tumor or Pigmented Variant of Dermatofibrosarcoma protuberans: A Rare Case Report.

Dr. Saurav Banerjee¹, Dr. Joy Mridha², Dr. Ramesh Kumar Shrivastava³,
Dr. Indrani Karmakar⁴

¹(Tutor, Department of Pathology, Rajendra Institute of Medical Sciences, Ranchi, Jharkhand, India)

²(Junior Resident, Department of Pathology, Rajendra Institute of Medical Sciences, Ranchi, Jharkhand, India)

³(Professor, Department of Pathology, Rajendra Institute of Medical Sciences, Ranchi, Jharkhand, India)

⁴(Junior Resident, Department of Pathology, Rajendra Institute of Medical Sciences, Ranchi, Jharkhand, India)

Abstract : Pigmented variant of dermatofibrosarcoma protuberans (DFSP) are one of the rarest tumor. It was first described by Bednar in 1957. The tumor consists only 1-5% of all dermatofibrosarcoma protuberans (DFSP). Here we present, a 55 year old male patient complaining of abdominal lump for more than 5 years. FNAC of the tumor goes in the favor of spindle cell tumor with occasional black pigment containing cell. Histologically, we appreciated storiform pattern of the tumor and honeycomb appearance, in some areas. Finally, immunohistochemistry confirms the diagnosis of Bednar tumor or pigmented variant of dermatofibrosarcoma protuberans (DFSP)

Keywords: Bednar tumor, cytopathology, histopathology, Immunohistochemistry

I. Introduction

Dermatofibrosarcoma protuberans (DFSP) has been regarded as a fibrous tumor of intermediate malignancy because it is best known for relentless growth and proneness to recur rather than metastasis. It is a tumor mostly seen in adults. These tumors mainly arise from the trunk and proximal extremities. It is now very clear that bednar tumor is a pigmented variant of dermatofibrosarcoma protuberans (DFSP), rather than storiform neurofibroma (in earlier nomenclature).

II. Case report

A 55 year old male came to our institution with complain of abdominal lump in right inguinal fossa region. On examination, the lump was found on the abdominal wall, which was fixed to the skin but not with the underlying structure and it was non-tender. No regional lymphadenopathy was noticed. FNAC of the lump was reported as 'spindle cell tumor with pigment containing cell impingement'. Wide local excision of the tumor had been done. The excised tumor was received for histopathology report. On gross examination, received tissue specimen was in two bits, of which larger bit was of size 11cm×7cm×2cm and smaller bit 5cm×5cm×1.5cm, yellowish-brown in color, firm to hard in consistency, black colored pigment was noticed in a scattered fashion within the tumor (fig-1).

Microscopically, the tumor predominantly showed a storiform pattern (fig-2). The tumor cells were dense aggregate of monotonous fibroblastic cells, that was spindle in shape with tapered nuclei and inconspicuous nucleoli. The spindle cells were infiltrating into the underlying dermis around skin appendages and into the subcutaneous tissue. The presence of occasional dendritic cell with various proportion of pigment was noticed (fig-3). The pigments were negative for iron staining. Occasionally the tumor cells were found to grow within the septa of the skin appendages giving them a honeycomb appearance. Few areas of hemorrhage and necrosis were also seen. Immunohistochemistry was done for CD-34, CD-10, S-100 for confirmation of the diagnosis. The tumor was CD-34 positive (fig-4a) and S-100 negative (fig-4b) which distinguished itself from benign fibrous histiocytoma (CD-34 negative) and neurofibroma (S-100 positive).

III. Discussion

Dermatofibrosarcoma protuberans is best regarded as a well differentiated primary fibrosarcoma of the skin. Pigmented variant of dermatofibrosarcoma protuberans are very rare^[1,2,3,4]. The genetic features of Bednar tumor are identical to those of ordinary dermatofibrosarcomas, and it is now clear that these represent simply morphologic variants of this tumor, rather than neural neoplasms^[5]. It is seen in young to middle-aged adults in the fourth decade with very occasional cases in the pediatric age group^[6,7].

The most common site of the bednar tumor is trunk and proximal extremities^[8,9,10]. These tumors are characterized by the relentless growth over the years. The growth pattern of the tumor in that case is multi lobular to nodular type, growing deep into the subcutaneous areolar tissue. Neuro-ectodermal differentiation or melanocytic colonization are the two proposed theories for histogenesis for the Bednar tumor. Pigment laden dendritic cell differentiate Bednar tumor from the conventional dermatofibrosarcoma protuberans. These pigment containing dendritic cells and extracellular pigment are diffusely located in the substance of the tumor. It has been suggested that this finding indicates that the tumor synthesizes melanin rather than phagocytosis, although others have suggested that the tumor is simply colonized by melanin-bearing cells^[11]. These cells differentiate the tumor from melanoma.

The number of melanocyte containing cells varies from case to case. Abundant pigmented dendritic cells can cause black discoloration of the tumor^[12]. CD34 has been considered to be the most useful marker for distinguishing DFSP from other fibrohistiocytic tumors such as dermatofibroma, malignant fibrous histiocytoma, and scar tissue^[14]. CD-34 positivity and CD-10 negativity supports the diagnosis of dermatofibrosarcoma protuberans and exclude benign fibrous histiocytoma, S-100 negativity exclude the diagnosis of pigmented variant of neurofibroma. But pigmented dendritic cells in many cases of bednar tumor are S-100 positive. Bednar tumor are prone to recur rather than metastasis^[13].

IV. Figures



Fig-1

Fig 1-Gross ;yellow brown color tumor with black color pigment and skin appendages.

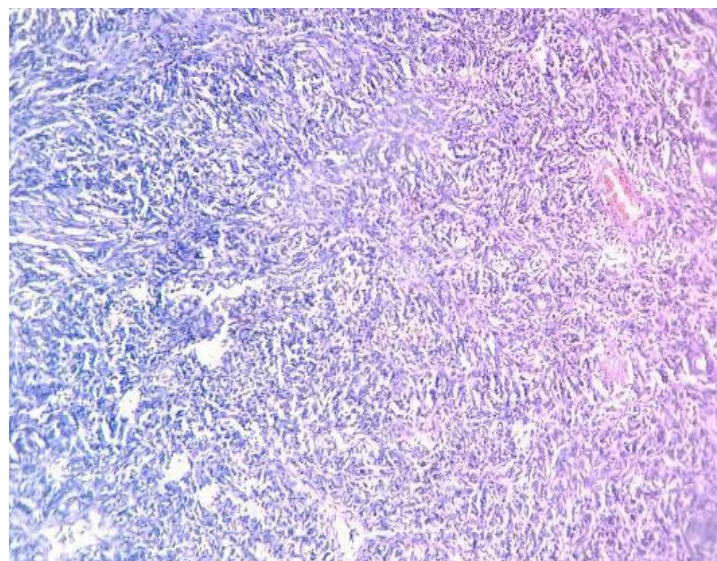


Fig-2

Fig-2 –Slender spindle cells arranged in a distinct storiform pattern characteristic of dermatofibrosarcoma

protuberans(H and E stain-5X)

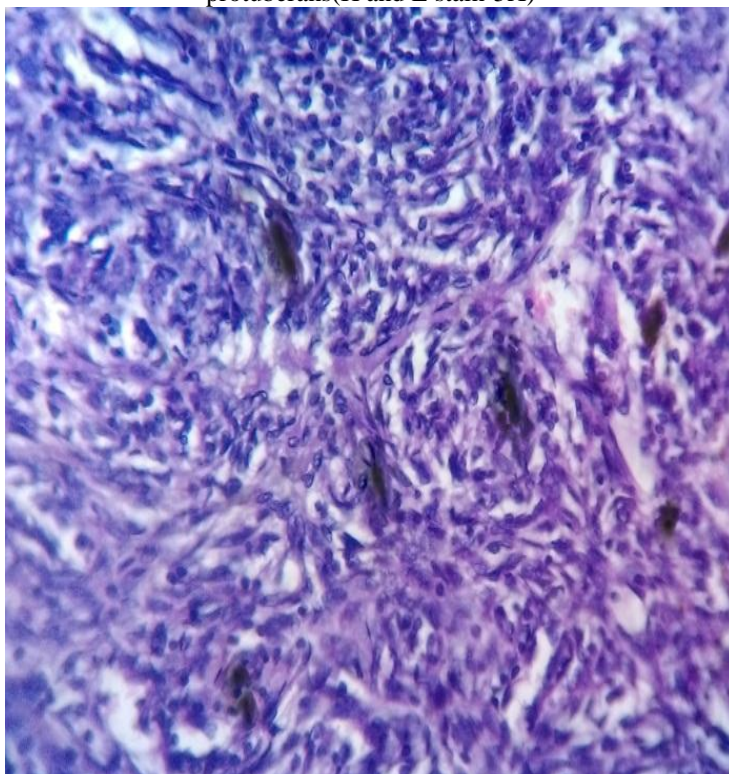


Fig-3

Fig-3 -Pigmented variant of dermatofibrosarcoma protuberans,black colour pigment present in dendritic cell (H and E stain-40X)

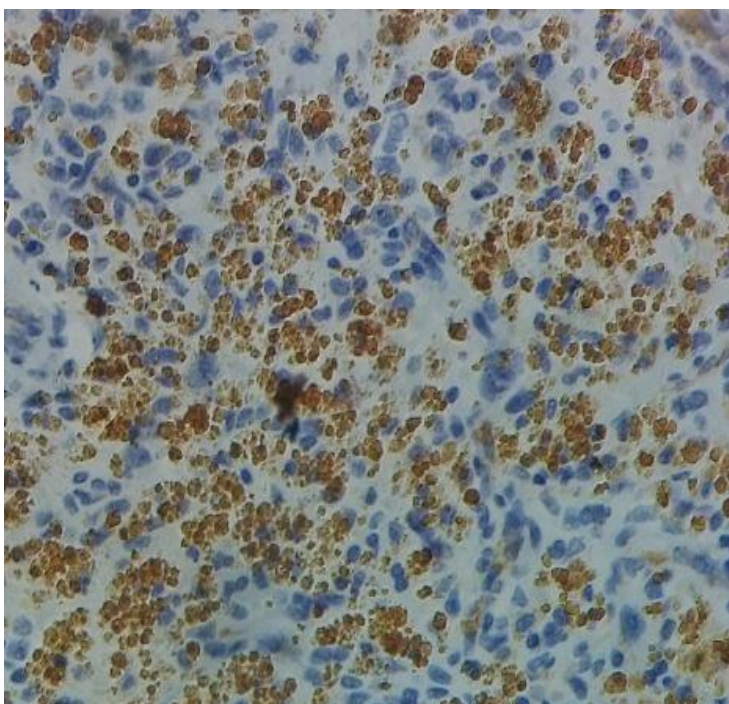


Fig-4a

Fig-4a IHC ; CD-34-positive

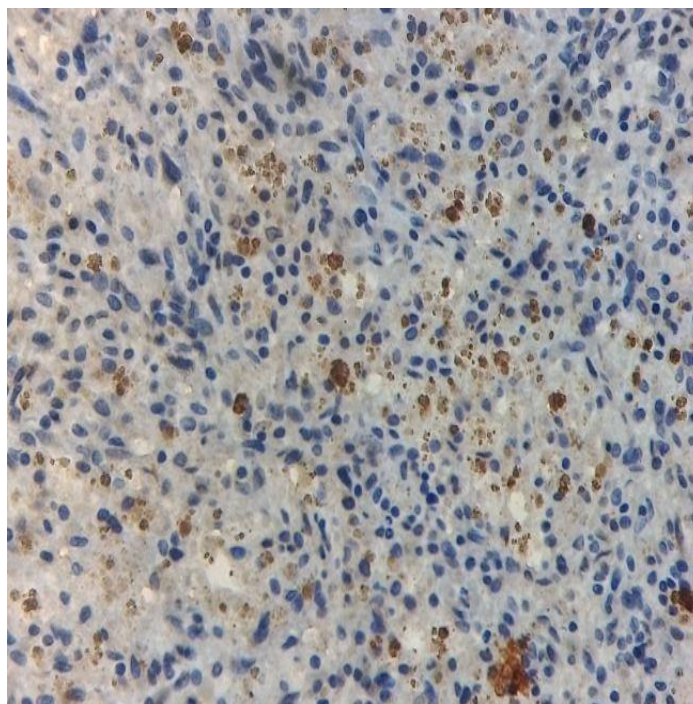


Fig-4b

.Fig-4b- IHC ; S-100-negative

V. Conclusion

Bednar tumor or pigmented variant of dermatofibrosarcoma protuberans is a very rare tumor with prominent storiform pattern and tumor is impinged with pigmented dendritic cells. The most useful marker for these tumors are CD-34, which is almost always positive and differentiates it from benign fibrous histiocytoma. They are S-100 negative, which differentiates it from neurofibroma. Complete extirpation with close follow-up care is indicated for this neoplasm although metastases are rare.

References

- [1]. Ding J, Hashimoto H, Enjoji M. Dermatofibrosarcoma protuberans with fibrosarcomatous areas. A clinicopathologic study of nine cases and a comparison with allied tumors. *Cancer [Comparative Study]* 1989;64(3):721–9.
- [2]. Ding JA, Hashimoto H, Sugimoto T, et al. Bednar tumor (pigmented dermatofibrosarcoma protuberans). An analysis of six cases. *Acta Pathol Jpn [Case Reports Research Support, Non-U.S. Gov't]* 1990;40(10):744–54.
- [3]. Dupree WB, Langloss JM, Weiss SW. Pigmented dermatofibrosarcoma protuberans (Bednar tumor). A pathologic, ultrastructural, and immunohistochemical study. *Am J Surg Pathol* 1985;9(9):630–9.
- [4]. Wang J, Hisaoka M, Shimajiri S, et al. Detection of COL1A1-PDGFB fusion transcripts in dermatofibrosarcoma protuberans by reverse transcription-polymerase chain reaction using archival formalin-fixed, paraffin-embedded tissues. *Diagn Mol Pathol* 1999;8(3):113–9.
- [5]. Onoda N, Tsutsumi Y, Kakudo K, et al. Pigmented dermatofibrosarcoma protuberans (Bednar tumor). An autopsy case with systemic metastasis. *Acta Pathol Jpn [Case Reports]* 1990;40(12):935–40.
- [6]. Reis-Filho JS, Milanezi F, Ferro J, Schmitt FC. Pediatric pigmented dermatofibrosarcoma protuberans (Bednar tumor): case report and review of the literature with emphasis on the differential diagnosis. *Pathol Res Pract.* 2002;198:621–626.
- [7]. Goncharuk V, Mulvaney M, Carlson JA. Bednar tumor associated with dermal melanocytosis: melanocytic colonization or neuroectodermal multidirectional differentiation? *J Cutan Pathol.* 2003;30:147–151.
- [8]. Suehara Y, Yazawa Y, Hitachi K. Metastatic Bednar tumor (pigmented dermatofibrosarcoma protuberans) with fibrosarcomatous change: a case report. *J Orthop Sci.* 2004;9:662–665.
- [9]. Vandeweyer E, Deraemaeker R, Somerhausen ND, Geledan L, Gebhart M. Bednar tumor of the foot: a case report. *Foot Ankle Int.* 2001;22:339–341.
- [10]. Kaul R, Kaur N, Dogra SS, Chander B. Variant of dermatofibrosarcoma protuberans: bednar tumor. *Indian J Dermatol.* 2015;60:107.
- [11]. Bisceglia M, Vairo M, Calonje E, et al. [Pigmented fibrosarcomatous dermatofibrosarcoma protuberans (Bednar tumor). 3 case reports, analogy with the “conventional” type and review of the literature]. *Pathologica [Case Reports Review]* 1997;89(3):264–73.
- [12]. Weiss SW, Goldblum JR (Pigmented dermatofibrosarcoma protuberans, Storiform Neurofibroma). *Fibrohistiocytic tumor of intermediate malignancy.* Weiss & Goldblum eds. *Enzinger and Weiss’s Soft Tissue Tumors*, 5th ed. 2008, Mosby, Inc. P371–402.
- [13]. Abdul-Karim FW, Evans HL, Silva EG. Giant cell fibroblastoma: a report of three cases. *Am J Clin Pathol [Case Reports]* 1985;83(2):165–70.
- [14]. Kobayashi T, Hasegawa Y, Konohana A, Nakamura N. A case of Bednar tumor: Immunohistochemical positivity for CD34. *Dermatology.* 1997;195:57–9.