

Coronectomy; A New Approach For Preservation of IAN Damage During Impacted M3rd Molarsurgery: A Case Report.

Dr.HemalKatwala*, Dr.AnilManagutti**, Dr.ShaileshMenat***,
Dr. Karan Makadia*

*Postgraduate student,dept. Of OMFS NPDCH, Visnagar;

** Prof and HOD, dept. of OMFS, NPDCH,Sankalchand Patel University Visnagar

*** Prof,dept. Of OMFS, NPDCH,Sankalchand Patel University Visnagar

Corresponding author: Dr.HemalKatwala

Abstract: Extraction of an impacted mandibular third molar has the potential risk of causing temporary or permanent neurologic disturbances of the inferior alveolar nerve (IAN). The risk of this complication depends mainly on the position of the impacted tooth in relation to the inferior alveolar canal before surgery. Coronectomy is procedure in which surgical removal of crown only and leaving root undisturbed. Injury to the IAN can occur from compression of the nerve, either indirectly by forces transmitted by the root during elevation or directly by elevators. The method aims to remove only the crown of an impacted mandibular third molar while leaving the root undisturbed, thereby avoiding direct or indirect damage to the IAN.

Keywords: Coronectomy, Impaction, IAN injury, M3rd molar surgery, Parasesthesia

I. Introduction

Commonly performed operations are mandibular third molar surgeries by oral and maxillofacial surgeons. There are many post-operative complications which include bleeding, dry socket, inferior alveolar nerve injury, delayed healing, periodontal pocket, and infection.^[1,2] The incidence of IAN injury reported in the literature ranges from 1.3% to 5.3%.^[3-7] The prevalence of nerve injury in the twenty-four prospective studies reviewed varies between a minimum of 0%^[8] and a maximum of 8.4%.^[9,10] Risk factors include advanced age and difficult operating conditions, but the most significant one is the proximity of the third molar to the mandibular canal. The need to prevent these kinds of injuries is especially important because, literature reveals that complete recovery is uncommon with all types of previously known modalities. Coronectomy is a new preventive method to decrease the prevalence of IAN injury compared with the conventional complete removal of the lower third molar.^[11] The crown of the impacted lower third molar is often responsible for the food impaction, dental caries, or pericoronitis that troubles the patient. By surgically removal of only coronal portion the subsequent risk of an IAN deficit is obviated.

Coronectomy is performed when contact between the mandibular third molar apex and the inferior alveolar nerve is suspected or root of mandibular 3rd molar is very close to inferior alveolar nerve.^[12] The success of coronectomy compared with conventional tooth extraction has been recognized in recent years. It is also proved that retained roots after coronectomy in the lower third molars produce no complications in terms of infection, pain, or the development of pathologies within the first 3 years. This case report shows, impacted lower third molar whose roots in an intimate relationship with the mandibular canal, were treated by intentional coronectomy. Postoperative outcomes were evaluated, including neurosensory deficit, postoperative infection, pain and effectiveness of surgical technique. The patient was followed up for a period of one and half years.

Case Report:

A 21-year-old female patient reported with occasional pressure pain of intermittent origin in relation to right and left posterior teeth region since 4 months. She consulted an oral and maxillofacial surgeon where various investigations were carried out to get to the base of this problem. The orthopantomogram revealed presence of impacted left and right mandibular third molars (Fig.1A). It confirmed the presence of both mandibular molars in mesio-angular position according to Winter's classification, class 2B according to Pell and Gregory's classification. The molars were deep seated and their roots were in close approximation to the inferior alveolar canal, hence patient was sent for further investigations. The CBCT was obtained which revealed the roots were in intimate contact with the IAN and the nerve was being compressed by the roots. (Fig.1B &1C).

The patient was warned that it could lead to bilateral paresthesia of the inferior alveolar nerve following surgical removal of third molars. The patient was given the treatment options and risks of observation, extractions with grafting, and Coronectomy. The patient chose to go for bilateral Coronectomy. The treatment plan was reviewed and her consent was obtained.

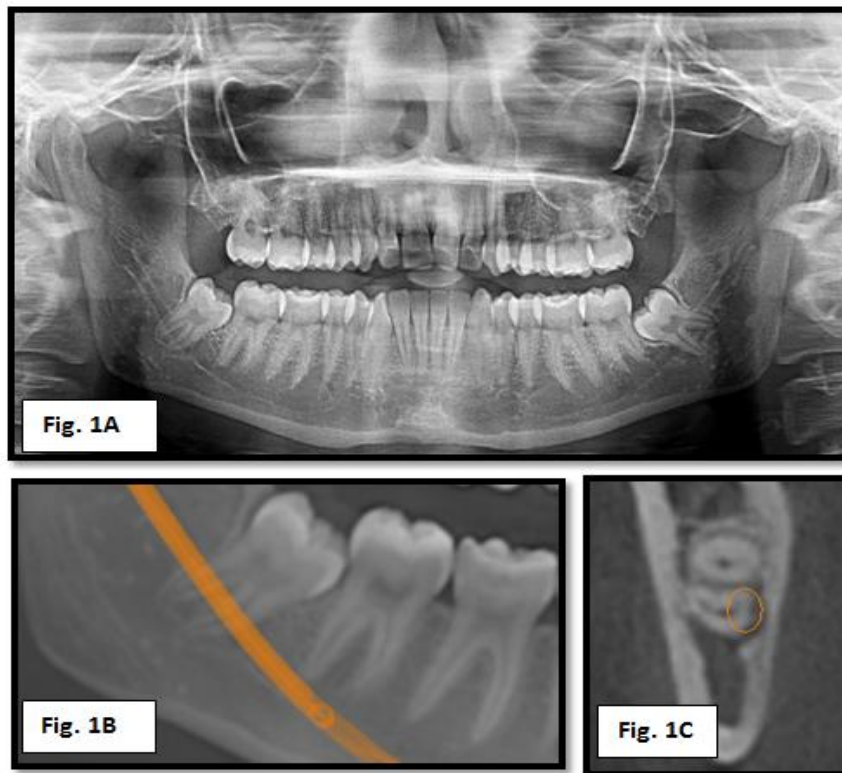


Fig.1A: Impacted left and right mandibular third molars.

Fig.1B & 1C: CBCT showing roots were in intimate contact with the IAN and the nerve was being compressed by the roots.

The surgery was carried out under local anesthesia. A standard ward incision was placed and the tooth was exposed. A buccal and distal osteotomy was carried out and horizontal cut was placed along the CEJ region about 1-2mm below the alveolar crest with #703 cross cut fissure carbide bur, to facilitate coronal fragment removal. The cut was completed at 3/4 of the tooth diameter to avoid cutting into the lingual wall. The coronal fragment was then fractured and removed (figure 2-5). The flap was given primary closure with 4-0 silk sutures (figure 6). Patient was prescribed antibiotics and analgesics for next 4 days.

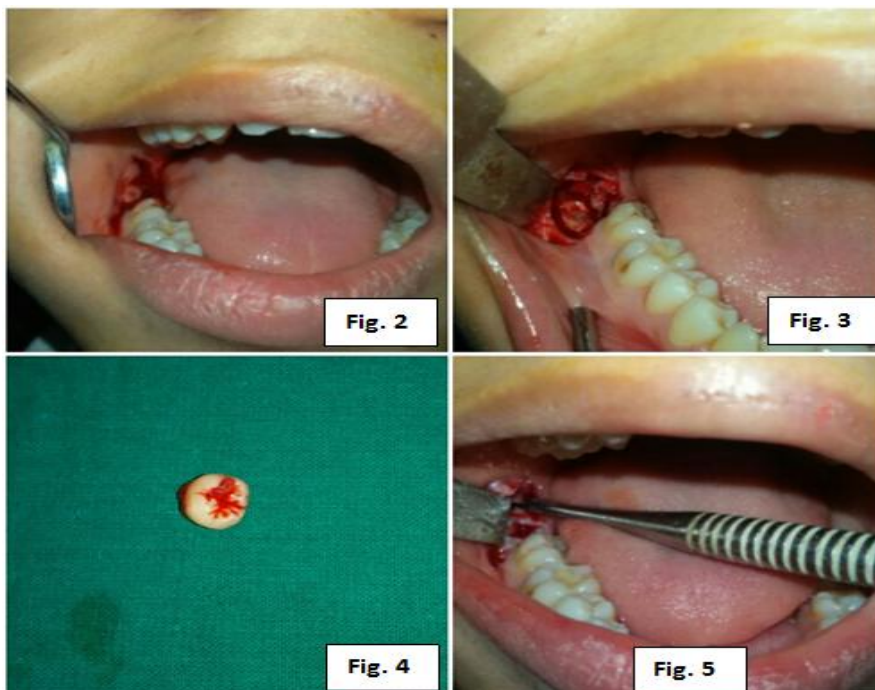

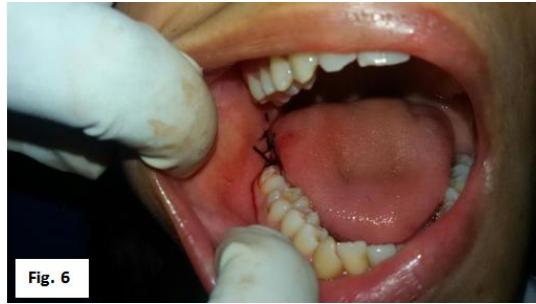


Fig.2-6: Surgical procedure and suturing

The patient was seen for a follow-up visit at seven days postoperatively and sutures were removed. The surgical sites appeared to have healed normally without any pain. The absence of paresthesia in the IAN and lingual nerve distribution was assessed by the patient's subjective response of normal sensation with sharp, blunt, and light touch. A follow-up panoramic radiograph was obtained showing the eruption of roots of third molars and away from the nerve which can be removed safely without damaging IAN (Fig. 7).

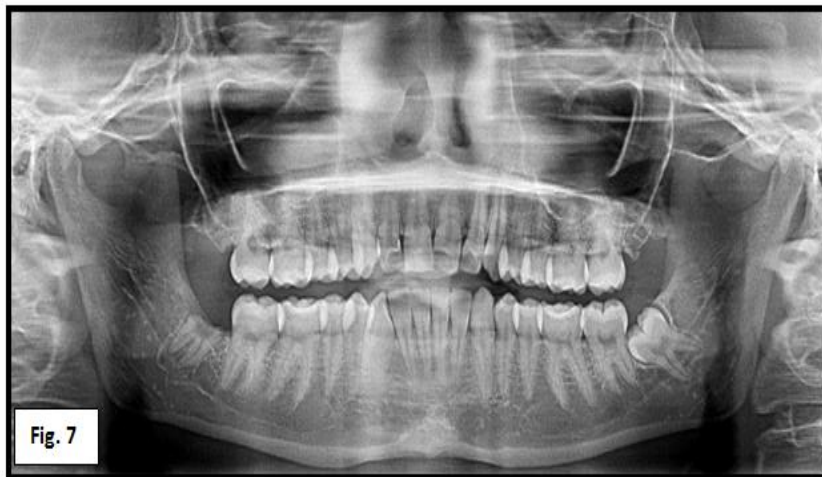

Fig 7: immediate post operative opg.

The patient was followed up at regular intervals of every 15 days for the first 2 months and then for every 1 month for up to 1 year. At the end of 1 year, it was observed that the roots had subsequently erupted from their previous position and acquired a new superficial position away from the IAN, which was now favorable for removal. The roots were removed, and no subjective signs of pain or paresthesia were observed in the follow-up visits (Fig. 8).

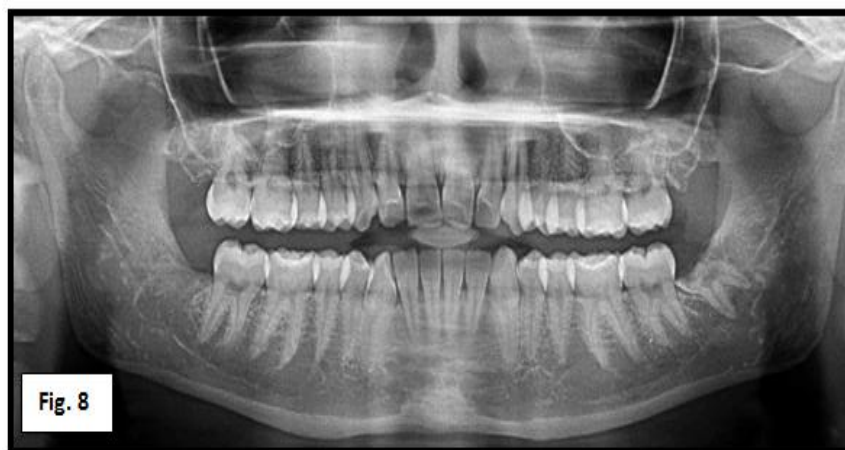

Fig.8: post Op OPG after one year

II. Discussion

In the 1970s, clinical, radiographic and histological experimental studies evaluated that the dental roots could be submerged within the soft tissues which was also known as "burial root" at the time, was believed that the maintenance of these roots in their alveoli preserved the height of the alveolar ridge, and consequently it could improve the adaptability and stability of conventional prostheses.^[13,14]

Certain radiographic indicators are used by which is predicted the increased risk of injury of the IAN. Those radiographic signs are: a) Deviation of a canal, b) Narrowing of a canal, c) Periapical radiolucent area, d) Narrowing of the root, e) Darkening of the root, f) Deflection of the root and g) Discontinuity of the lamina dura from the canal.^[15,16] However, by using a panoramic dental x-ray, the exact correlation between the dental roots and the IAN cannot be detected, as it is a two-dimensional imaging technique. Today, the cone beam computerized tomography scanning, as a highly sophisticated tri-dimensional radiography, is a standard in the evolution of the correlation of the IAN roots and the nerve, in order to determine an adequate therapeutic option.

Coronectomy was developed to reduce the incidence of iatrogenic injury to the inferior dental nerve during routine surgical removal of 3rd molar, but it is not widely accepted despite early studies that all showed positive results. Various studies have showed the success of the procedure of intentional partial odontectomy and this is emphatic in stating that it is a predictable and acceptable technique. Intentionally coronectomy presents itself as an alternative technique in surgically removal of third molars which have a close relationship with the inferior alveolar nerve canal, as reported in present case. Root migration can occur in a very small percentage of patients and may require reoperation to remove the root.^[17] The main disadvantage of procedure is that it requires second stage surgery to remove retained root from socket. Regarding the study of submerged roots with and without endodontic treatment, there is still no consensus in the literature because some studies report good results in roots with endodontic treatment, while others disagree.^[18-22] Reames et al. emphasizes that success in the roots with endodontic treatment has no predictability. The present case did not have its roots endodontically treated. The confirmation of relationship between root of 3rd molar and IAN by using the CBCT is gold standard. There are 7 criteria from orthopantomogram which shows that there is a risk of damaging the IAN while surgical removal of 3rd molar given by Howe, Poyton, Rood, and Shehab.^[16] But still OPG gives a 2 dimensional image and not cent percent surety that surgical removal will lead to damage to the IAN. We used CBCT in our case. In our case patient did not experience any temporary or permanent sensory deficit.

Studies revealed the rate of infection in roots remaining after intentional partial odontectomy was low but only one study reported signs of postoperative infection. When comparing the rate of postoperative infection in patients treated by intentional partial odontectomy and conventional extraction, indicate that the incidence of alveolitis was similar in both groups. In clinical cases presented no infection was observed until last follow up. There are relatively few contraindications to perform coronectomy and it includes 1) teeth with active infection around them, particularly periapical infections; 2) teeth that are mobile and 3) horizontally impacted teeth that itself endangers nerve while sectioning. Only vertical, mesio-angular and disto-angular impacted teeth are indicated for coronectomy.^[23]

III. Conclusion

Nerve injury after the extraction of the mandibular third molar is most important complication. Coronectomy can be proposed to minimize the risk of nerve damage in selected cases. The void in the literature reporting on the technique's long-term success requires prudent participation of clinicians to contribute to the knowledge base before the procedure can be routinely prescribed for prevention of damage to the inferior alveolar nerve in mandibular third molar surgeries.

Reference

- [1]. Motamedi MH. Concepts to consider during surgery to remove impacted third molars. *DentToday*. 2007 Oct;26(10):136, 138-41; quiz 141, 129.
- [2]. Motamedi MH. Preventing periodontal pocket formation after removal of an impacted mandibular third molar. *J Am Dent Assoc*. 1999 Oct;130(10):1482-4.
- [3]. Bataineh AB. Sensory nerve impairment following mandibular third molar surgery. *J Oral Maxillofac Surg*. 2001;59:1012-7.
- [4]. Bui CH, Seldin EB, Dodson TB. Types, frequencies, and risk factors for complications after third molar extraction. *J Oral Maxillofac Surg*. 2003;61:1379-89.
- [5]. Goldberg MH, Nemerich AN, Marco 2nd WP. Complications after mandibular third molar surgery: a statistical analysis of 500 consecutive procedures in private practice. *J Am Dent Assoc*. 1985;111:277-9.
- [6]. Kipp DP, Goldstein BH, Weiss Jr WW. Dysesthesia after mandibular third molar surgery: a retrospective study and analysis of 1,377 surgical procedures. *J Am Dent Assoc*. 1980;100:185-92.
- [7]. Smith AC, Barry SE, Chiong AY, Hadzakis D, Kha SL, Mok SC, et al. Inferior alveolar nerve damage following removal of mandibular third molar teeth. A prospective study using panoramic radiography. *Aust Dent J*. 1997;42:149-52.
- [8]. G.W. Bell, "Use of dental panoramic tomographs to predict the relation between mandibular third molar teeth and the inferior alveolar nerve. Radiological and surgical findings, and clinical outcome," *British Journal of Oral and Maxillofacial Surgery*, vol.42, no. 1, pp. 21-27, 2004.
- [9]. R. J. Middlehurst, G. R. Barker, and J. P. Rood, "Postoperative morbidity with mandibular third molar surgery: a comparison of two techniques," *Journal of Oral and Maxillofacial Surgery*, vol. 46, no. 6, pp. 474-475, 1988.

- [10]. V. Lopes, R. Mumenya, C. Feinmann, and M. Harris, "Thirdmolar surgery: an audit of the indications for surgery, postoperativecomplaints and patient satisfaction," *British Journal of Oral and Maxillofacial Surgery*, vol. 33, no. 1, pp. 33–35, 1995.
- [11]. M. A. Pogrel, J. S. Lee, and D. F. Muff, "Coronectomy: a technique to protect the inferior alveolar nerve," *Journal of Oral and Maxillofacial Surgery*, vol. 62, no. 12, pp. 1447–1452, 2004.
- [12]. Zola MB. Avoiding anaesthesia by root retention. *J Oral MaxillofacSurg*1992; 50:419–421.
- [13]. Whitaker DD, Shankle RJ (1974) A study of the histologic reaction of submerged root segments. *Oral Surg Oral Med Oral Pathol* 37: 919-935.
- [14]. Johnson DL, Kelly JF, Flinton RJ, Cornell MT (1974) Histologic evaluation of vital root retention. *J Oral Surg* 32: 829-833.
- [15]. Palma C, García B, Carolina L, Peñarrocha M. Radiographic signs associated with inferior alveolar nerve damage following lower third molar extraction. *Med Oral Patol Oral Cir Bucal*. 2010 Nov 1;15 (6):e886-90.
- [16]. Rood JP, Shehab BA. The radiological prediction of inferior alveolar nerve injury during third molar surgery. *Br J Oral Maxillofac Surg*. 1990;28:20-5
- [17]. Cook RT, Hutchens LH, Burkes EJ. Periodontal osseous defects associated with vitally submerged roots. *J Periodontol* 1977; 48: 249–260.
- [18]. Kim YB,JooWH,Min KS (2014) Coronectomyof a lower third molar in combination with vital pulp therapy. *Eur J Dent*8: 416-418.
- [19]. Whitaker DD, Shankle RJ (1974) A study of the histologic reaction of submerged root segments. *Oral Surg Oral Med Oral Pathol* 37: 919-935.
- [20]. Johnson DL, Kelly JF, Flinton RJ, Cornell MT (1974) Histologic evaluation of vital root retention. *J Oral Surg* 32: 829-833.
- [21]. Reames RL, Nickel JS, Patterson SS, Boone M, El-Kafrawy AH (1975) Clinical, radiographic, and histological study of endodontically treated retained roots to preserve alveolar bone. *J Endod* 1: 367-373.
- [22]. Sencimen M, Ortakoglu K, Aydin C, Aydintug YS, Ozyigit A (2010) Is endodontic treatment necessary during coronectomy procedure? *J Oral Maxillofac Surg*. 68: 2385-2390.
- [23]. Ahmed C. Coronectomy of Third Molar:A Reduced Risk Technique for Inferior Alveolar Nerve Damage. *Dent Update* 2011; 38: 267–276