

## A Case Of Hodgkin Lymphoma Presenting As Soft Tissue Mass

\*Dr. Daniel Ravikumar<sup>1</sup>, Dr. Rajeev Thilak C<sup>2</sup>, Dr. Ameesh Isath<sup>3</sup>,

Dr. Nikitha Rafeek<sup>4</sup>

(Institute Of General Surgery, Madras Medical College, Chennai, India)

Corresponding author: \*Dr. Daniel Ravikumar

**Abstract :** The most common early sign of Hodgkin lymphoma is a painless swelling (enlargement) of one or more lymph nodes. Lymphoma presenting as a soft tissue mass is relatively uncommon and can easily be confused with a wide variety of inflammatory conditions (neoplasia as well as infectious diseases). Chest wall involvement is uncommon and occurs in about 0.64% of cases. It may represent either an initial manifestation of the disease or a site of recurrence. Here we present a case of Hodgkin lymphoma presenting as soft tissue mass in right side of chest wall without nodal involvement.

**Keywords :** Hodgkins lymphoma, soft tissue mass, chest wall

### I. INTRODUCTION

Soft tissue sarcomas and lymphomas are among the malignant neoplasms which can be seen in chest wall and axillary regions. Differentiation between lymphoma and soft tissue tumour types is based on clinical findings, radiological features, and histopathology.

Hodgkin lymphoma (HL) most often occurs at latero-cervical region (75%), followed by mediastinal, axillary, and para aortic region. Peripheral extranodal involvement is very rare<sup>1</sup>. The onset of HL is usually nodal and can secondarily affect the extranodal tissue. Soft tissue sarcoma can also have similar presentation<sup>1</sup>. HL has a bimodal age distribution with the first peak occurring at 10 to 35 years of age<sup>1</sup>. HL should be always suspected based on site of involvement and the age at presentation.

The histopathological distinction between lymphoma and soft tissue sarcoma is routinely determined by IHC. Leucocyte common antigen (LCA) (lymphoid marker) and vimentin (mesenchymal marker) are commonly used for this purpose. However, in the case of HL, the malignant cells display a peculiar IHC pattern.

Non-Hodgkin lymphomas (NHL) are classically composed of a clonal monomorphic population of neoplastic lymphoid cells. This appearance is quite different to HL which comprises of a minority of neoplastic cells in a majority background reactive inflammatory cells. The diagnosis of HL is primarily based on the identification of characteristic multinucleated giant neoplastic cells within an inflammatory milieu. These cells are called Reed-Sternberg (RS) cells or Hodgkin cells in their mononuclear forms. The RS cells and their variants only constitute between 1% to 10% of the entire cell population. The IHC patterns displayed by HL are quite different to that of NHL. Unlike most lymphoid malignancies, RS cells and Hodgkin cells are not commonly reactive towards LCA. However, they are reactive towards vimentin which is a feature commonly seen in neoplasm of mesenchymal origin especially most soft tissue sarcoma.

In this report, we highlighted the important role of IHC in the diagnosis of HL which occurred in the shoulder region, an area predominantly occupied by soft tissue.

### II. Case Report

#### II.1 History and Examination

61 yr old Mr Pitchai coming with complaints of swelling in the right side of chest wall and axilla for the past 3 months. Patient noticed a swelling 3 months back which progressively increased in size, more rapidly for the past 1 month to attain present size. No h/o fever, trauma, swelling elsewhere in the body. No h/o metastatic symptoms. H/o loss of weight and appetite – present. No f/s/o compressive symptoms. No significant past/personal/family history.

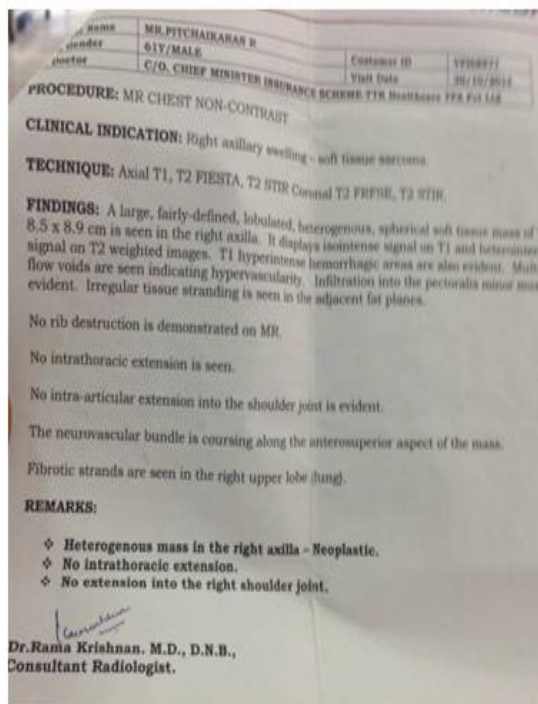
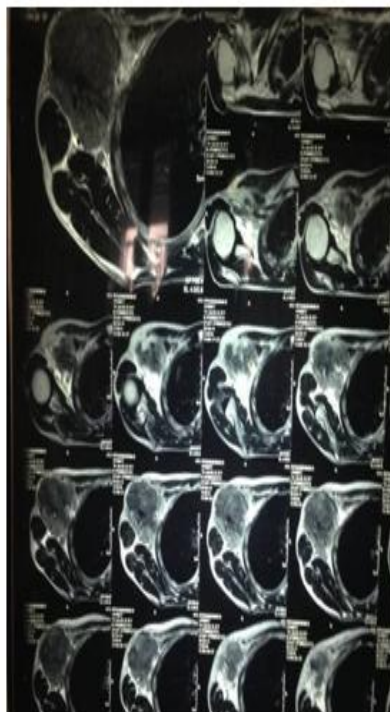
On examination patient is thin built, moderately nourished. Pallor is present. No generalised lymphadenopathy.

Local examination

- 15\*10 cm irregular swelling in rt chest wall extending into axilla, surface is irregular, borders are well defined, skin over swelling is stretched shiny with dilated veins over swelling, hard in consistency, skin is pinchable, on putting pec. major into contraction swelling appears prominent - 1\*1 cm axillary lymph node palpable - no distal neurovascular deficit. Systemic examination – normal. Provisional diagnosis of soft tissue sarcoma right chest wall was made.

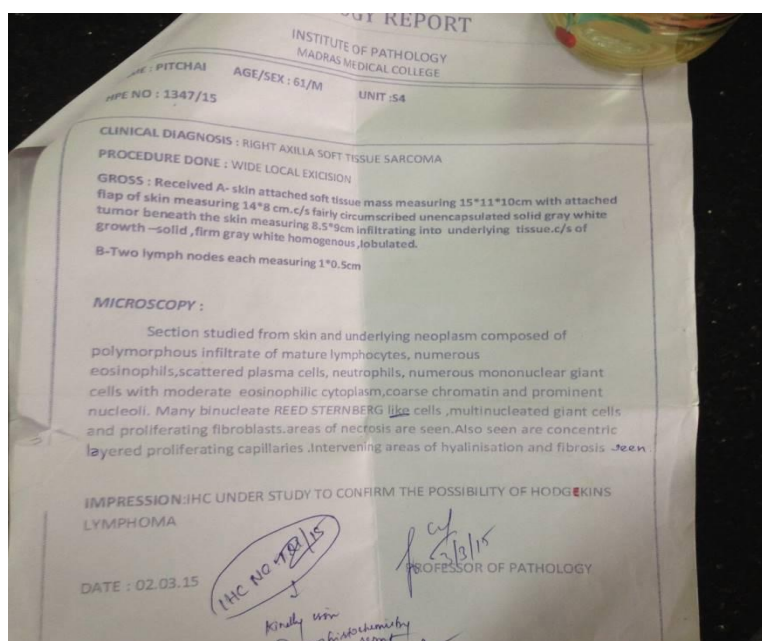
## II.2 Investigations

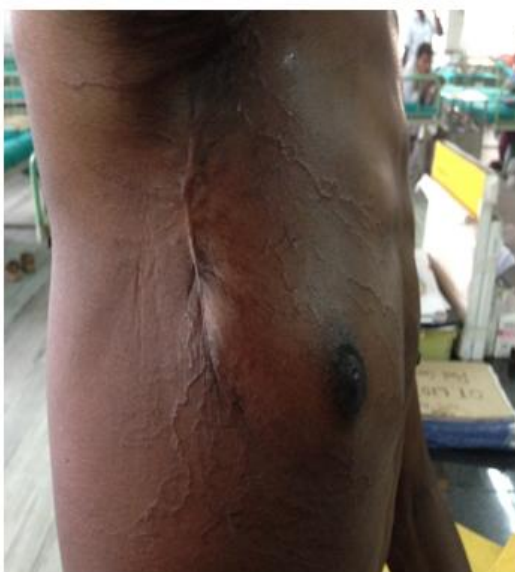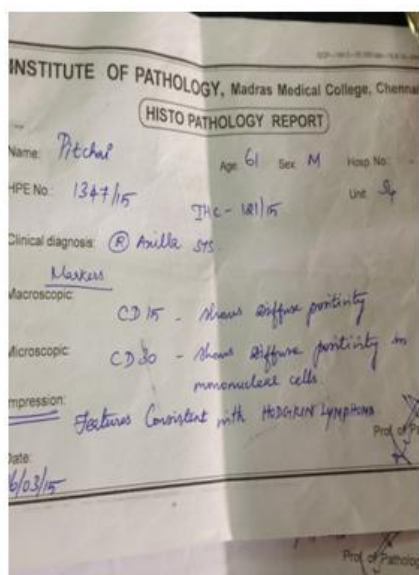
Blood investigations – anaemia MRI – soft tissue mass arising from rt chest wall extending into axilla, heterointense CT CHEST – soft tissue mass rt chest wall, no pleural effusion, no lung metastasis TRUCUT BIOPSY – spindle cell lesion with atypia (pleomorphic nuclei and scanty cytoplasm)



## II.3 Treatment

Patient was taken up for surgery with assistance from surgical oncology team wide local excision of tumor with primary closure was done. Post op – uneventful. Post op histopathology – Hodgkin lymphoma (cd 15+, cd 30+). After consulting with tumor board, chemotherapy was started (ABVD regimen). Patient is on follow up.





### III. DISCUSSION

Hodgkin lymphoma (HL), one of the most curable forms of cancer, was named for Thomas Hodgkin, a British pathologist. In 1832, Dr. Hodgkin described several cases of people with symptoms of a cancer involving the lymph nodes. This disease was called “Hodgkin’s disease” for about 170 years. It was officially renamed “Hodgkin lymphoma” in the late 20th century—when it became evident that the disease results from an injury to the DNA of a lymphocyte (type of white blood cell). The damage to the DNA is acquired (occurs after birth) rather than inherited. The altered DNA in the lymphocyte produces a cancerous change that—if untreated—results in the uncontrolled growth of the cancerous lymphocytes. The accumulation of the cancerous lymphocytes results in the tumor masses that are found in the lymph nodes and other sites in the body

HL is distinguished from other types of lymphoma by the presence of “Reed-Sternberg cells” (named for the scientists who first identified them). Reed-Sternberg cells are usually B cells and have differences and variations to them. The frequency with which these cells are seen and the variations observed help determine a patient’s subtype. Other cells associated with the disease are called “Hodgkin cells.”

#### Signs and Symptoms

The most common early sign of HL is a painless swelling (enlargement) of one or more lymph nodes. The vast majority of patients with HL have affected lymph nodes in the upper part of the body—usually in the neck or upper chest. Sometimes the affected lymph node is in the armpit, abdomen or groin

Other HL symptoms include Fever, Persistent fatigue, Persistent cough and shortness of breath (if HL is located in the chest), Sweating, especially at night (drenching sweats of the whole body, not just the neck area or chest area), Weight loss, Enlarged spleen and Itching. Individuals with HL may experience pain in the lymph nodes after drinking alcohol—this is an uncommon but specific symptom.

#### Subtypes of Hodgkin Lymphoma

Classical Hodgkin lymphoma -Nodular sclerosis Hodgkin lymphoma ,Mixed cellularity,Lymphocyte-depleted and Lymphocyte-rich classical Hodgkin lymphoma  
Nodular lymphocyte-predominant Hodgkin lymphoma

#### Stages and Categories of Hodgkin Lymphoma

Stage I Apparent involvement of a single lymph node region or a single organ, such as bone.

Stage II Involvement of two or more lymph node regions that are close to each other; for example, all in the neck and chest, or all in the abdomen and on the same side of the diaphragm (a thin muscle below the lungs).

Stage III Involvement of several lymph node regions in the neck, chest and abdomen (on both sides of the diaphragm).

Stage IV Widespread involvement of lymph nodes on both sides of the diaphragm and in other organs, such as the lungs, liver and bones.

Categories A, B, X and E. The four stages of HL can be divided into categories.

The A category indicates the absence of fever, exaggerated sweating and weight loss.

The B category indicates that patients have fever, excessive sweating and weight loss.

The X category indicates bulky disease (large masses of lymphocytes).  
The E category indicates organs involved outside of the lymph system.

Lymphoma presenting as a soft tissue mass is relatively uncommon and can easily be confused with a wide variety of inflammatory conditions, more common neoplasias as well as infectious diseases. Extranodal involvement by lymphoma has been described in every tissue of the body with multiple different appearances even within one organ system. Thus, it should be regularly included in the differential diagnosis of mass lesions. Diagnosis is formally established by pathology.

#### **IV. Conclusion**

Chest wall involvement is not uncommon and occurs in about 6.4% of cases. It may represent either an initial manifestation of the disease or a site of recurrence. If unrecognized, chest wall involvement increases the risk of treatment failure in patients with Hodgkin disease because it changes the stage of the disease and therefore requires more aggressive therapy. The most common type of chest wall involvement is infiltration of parasternal soft tissues by direct extension from anterior mediastinal nodes, primarily in cases of internal mammary node involvement. Occasionally, masses are seen beneath or between the pectoral muscles without contiguous mediastinal or axillary adenopathy. Thoracic spine involvement, when present, is frequently due to direct spread from posterior mediastinal nodes. Most patients with chest wall involvement have associated intrathoracic disease. However, chest wall masses may occasionally be seen without evidence of intrathoracic disease. Castellino et al. showed that CT is the modality of choice for detecting chest wall involvement by identifying the disease in 12 of 13 patients with CT alone. More recently, however, it has been shown that MR imaging is more sensitive than CT in this setting. Short-inversion-time inversion recovery and other fat-saturated sequences are particularly sensitive in detecting chest wall invasion.

Extranodal disease accounts for 15%–30% of all cases of Hodgkin disease. Therapeutic options are most numerous and the chance for cure is greatest at presentation. For this reason, when Hodgkin disease is diagnosed, extensive staging must be performed to determine whether extranodal involvement represents a primary manifestation or dissemination of systemic disease. It is important to distinguish between these two conditions because the prognosis is much less favourable in systemic Hodgkin disease. For this purpose, careful interpretation of CT findings is mandatory. In selected cases, US and MR imaging may be useful depending on tumor location. In the future, metabolic positron emission tomography may provide more information about extranodal lymphoma than do the current imaging modalities.

#### **References**

- [1]. Hasenclever D, Diehl V. A prognostic score for advanced Hodgkin's disease: International Prognostic Factors Project on Advanced Hodgkin's Disease. *N Engl J Med* 1998; 339:1506–1514.
- [2]. Proctor SJ, Taylor P, Donnan P, Boys R, Lennard A, Prescott RJ. A numerical prognostic index for clinical use in identification of poor-risk patients with Hodgkin's disease at diagnosis. *Eur J Cancer* 1991; 27:624–629.
- [3]. Straus DJ, Gaynor JJ, Myers J, et al. Prognostic factors among 185 adults with newly diagnosed advanced Hodgkin's disease treated with alternating potentially noncross-resistant chemotherapy and intermediate-dose radiation therapy. *J Clin Oncol* 1990; 8:1173–1186.
- [4]. Carde P, Burgers J, Henry-Amar M, et al. Clinical stage I and II Hodgkin's disease: a specifically tailored therapy according to prognostic factors. *J Clin Oncol* 1988; 6:239–252.
- [5]. North LB, Libshitz HI, Lorigan JG. Thoracic lymphoma. *Radiol Clin North Am* 1990; 28:745–762.
- [6]. Filly R, Blank N, Castellino RA. Radiographic distribution of intrathoracic disease in previously untreated patients with Hodgkin's disease and non-Hodgkin's lymphoma. *Radiology* 1976; 120:277–281.
- [7]. Castellino RA, Blank N, Hoppe RT, Cho C. Hodgkin's disease: contributions of chest CT in the initial staging evaluation. *Radiology* 1986; 160:603–605.
- [8]. Carlsen SE, Bergin CJ, Hoppe RT. MR imaging to detect chest wall and pleural involvement in patients with lymphoma: effect on radiation therapy planning. *AJR Am J Roentgenol* 1993; 160:1191–1195.
- [9]. Sandrasegaran K, Robinson PJ, Selby P. Staging of lymphoma in adults. *Clin Radiol*
- [10]. van der Schee AC, Dinkla BA, van Knapen A. Primary pulmonary manifestation of Hodgkin's disease. *Respiration* 1990; 57:127–128.
- [11]. Fishman EK, Kuhlman JE, Jones RJ. CT of lymphoma: spectrum of disease. *RadioGraphics* 1991; 11:647–669.

\*Dr. Daniel Ravikumar. "A Case Of Hodgkin Lymphoma Presenting As Soft Tissue Mass."  
*IOSR Journal of Dental and Medical Sciences (IOSR-JDMS)* 16.7 (2017): 81-84.