

A quantitative MRI study of the normative corpus callosum in Sudanese

Anna Mohamed Ahmed Ibrahim Mustafa¹, Mohamed Elfadil Mohammed Garelnabi¹, *Caroline Edward Ayad¹

¹Sudan University of Science and Technology-Khartoum-Sudan

*Corresponding author: Caroline Edward Ayad¹

Abstract : Morphometric measurements of the corpus callosum (CC) are important to have normative values according to gender, age and race/ethnicity. The present study examined the correlation between age, gender, and CC morphometrical data, across ages <10>60 years old to characterize normal developmental alternations in order to be as standard local reference for Sudanese. At issue; the objectives are also to examine whether CC index continues to increase throughout life, whether there are regional differences in measurements of CC maturation, and whether these outlines are sexually dimorphic.

The CC on Magnetic Resonance midsagittal T₁ weighted images was measured in 233 normal Sudanese subjects, (126 were males constituting 54.1% and 107 were females constituting 45.9%) admitted to Modern Medical Center, Royal care international hospital, MRI centers Khartoum-Sudan.

Considering age and gender; Fronto occipital maximum brain length, Thickness of CC compartments at its maximum level for rostrum, genu, body/trunk and splenium, CC greatest anteroposterior (AP)diameter, fronto-corpus callosum length, occipito-corpus callosum length and corpus callosum index (CCI) were measured. Data were analyzed using SPSS programe (Ver.16). All dimensions of CC compartments and brain have significant relation with increasing age at $p=0.000$ except for occipito-corpus callosum length where no significant relation was detected ($p=0.126$). The gender has an impact on the changes detected in the brain and CC compartments except for the rostrum, genu, callosal AP maximum diameter. Brain dimensions were significantly larger in males than in females at ($P \leq 0.05$). Reverse findings were found in the CC trunk, splenium maximum thickness and CCI, where females were greater than males with significant difference at $P=0.000, 0.011$ and 0.031 respectively. The CCI increased with age and then decreased thereafter. There was also a positive linear relationship between the AP length of the CC and the fronto-corpus callosum length. Regression equation for predicting the length of the CC and morphometric index as local reference for normative data of CC during maturation in the Sudanese population in both genders at similar age classes have been established.

Keywords - corpus callosum, morphometry, MRI

I. INTRODUCTION

Neuroimaging of the corpus callosum(CC) has attracted the researchers in both medical and neuroscience awareness in the past few decades.[1]Callosal changes due to brain atrophy were characterized in many diseases [2-4]as well the abnormalities in callosal morphology have also been reported in neuropsychiatric disorders[5] , developmental disorders[6] also changes are found during normal human development and aging [7], with callosal morphology reflecting gender differences [8]. Regarding differences in the size of humans'organs including CC according to race/ethnicity; CC dimensions, morphology and sex-related differences have been of interest to investigators. [9]

Most of the studies on the morphometry of CC were carried out in Western countries on the Caucasian population [10-14] and a few studies were performed in the East Asian population [15,16]Minimal variability in the dimensions and relative dimensions of the CC in Greek people was reported [9]. Takada in 2003 did not observe any difference in the regional size of CC between genders in Japanese subjects [15] On the other hand; another study found a well established difference in size, shape and position of the CC between genders. [11]

Magnetic resonance imaging (MRI) provides the most resolute images of the CC compared with the other imaging modalities [17].

To the best of our knowledge; no study has been obtained for Sudanese to characterize the norms, as clearly; there is a lack of comprehensive reference data with respect to callosal maturation. All data were interrelated to American, European, or Asian populations. In the present study we examine the correlation between age, gender, and CC morphometrical analyses using MRI, across ages <10>60 years old to characterize normal developmental alternations in order to be as standard local

reference for Sudanese residence in central Sudan. Knowledge about the norms might ease the early prediction of disorders if happened. At issue; the objectives are also to examine whether CC index continues to increase throughout life or reaches adult levels at earlier ages, whether there are regional differences in measurements of CC maturation, and whether these outlines are sexually dimorphic for Sudanese populations.

II. MATERIALS AND METHODS

This study is a descriptive cross-sectional study conducted at Modern Medical Center and Royal Care International Hospital. This study was carried out using MRI scanner of 1.5 Tesla (Toshiba) during the period from August 2014–2017.

2.1 Population:

This study included males and females with normal corpus callosum, their age ranged between 1–83 years. Patients were excluded only when the pathologic process affected, or could affect, the corpus callosum (e.g., hydrocephalus or tumor) and when the entire corpus callosum was not on a single slice as a consequence of an oblique imaging plane. Magnetic resonance images were eliminated if there was any visible evidence of deviation from the midsagittal plane.

2.2 Sample size and type:

A convenient sample type was adapted, where a total of 233 patients (126 males constituting 54.1% and 107 females constituting 45.9%) present for Brain MRI scan were included in the study in respect to the inclusion criteria. Considering the gender subjects were grouped as <10, 11–20, 21–30, 31–40, 41–50, 51–60 and >60 year old. Distribution of the total study sample age were as follows: <10=(24, 10.3%), 11–20=(33, 14.2%), 21–30=(37, 15.9%), 31–40=(49, 21.0%), 41–50=(40, 17.2%), 51–60=(17, 7.3%) and >60=(33, 14.2%), the study sample mean age was 36.72 ± 20.77 . The 126 males mean ages were classified into age classes as follows: Ages <10 = (4.084 ± 23.02) ages from 11–20 = (13.30 ± 3.23) and 21–30 were (26.06 ± 2.69), 31–40 were (36.56 ± 2.93), ages from 41–50 were (46.00 ± 2.91), 51–60 were (56.00 ± 3.16) and ages >60 were 72.88 ± 6.71 . The 107 females mean ages were classified into age classes as follows: Ages <10 = (3.40 ± 1.34), ages between 11–20 were (16.30 ± 2.45) ages from 21–30 were (26.09 ± 3.16), 31–40 were (36.26 ± 2.44) ages from 41–50 were (47.04 ± 2.78), 51–60 were 55.55 ± 2.06 and ages >60 were (70.85 ± 5.63).

2.3 Methods:

2.3.1 Techniques:

Head coil was used with a sheet on the table, dentures, hair clips, hair combs, earrings, nose rings, necklaces, were removed. Patients were positioned so their head and neck are relaxed, but without rotation in either plane, centre the field of view on the nasion in the midline, making minor adjustments for baseline tilt.

2.3.2 Measurement:

Data collection sheet were used to collect data about demographic characteristics (gender and age). In this study various parameters of corpus callosum were measured in Sudanese at the mid-sagittal plane of T₁ MR Images as described by Figueira et al. 2007 [18]. The considered variables were:-

- Fronto occipital maximum length.
- Thickness of various parts of corpus callosum at its maximum level (rostrum, genu, body/trunk and splenium).
- Greatest Anteroposterior Diameter Of corpus callosum.
- Fronto-Corpus Callosum length (Distance of corpus callosum from frontal pole) and Occipito-Corpus Callosum length (occipital pole of cerebral hemisphere).
- Corpus callosum index (CCI)

Corpus callosum index (CCI) was obtained on a conventional best midsagittal T1W image, using a simple orthogonal semi-automated system, by drawing a straight line at greatest anteroposterior diameter of CC and a perpendicular at its midline, owing to points genu maximum thickness, trunk maximum thickness and maximum thickness length of CC were measured and normalized to its greatest anteroposterior diameter (from genu to splenium), CCI was found for each cases, one by one, from the calculated measurements by *Formula* applied previously by Mehmet et al 2012 [19]

Corpus callosum index (CCI) = (Genu maximum thickness + Trunk maximum thickness + Splenium maximum thickness) / (CC greatest anteroposterior diameter)

2.3.3 Method of data analysis:

The Obtained data were transferred to SPSS (ver. 16.0) programme and were analyzed and presented as mean, standard deviation, and normal curve as well as significant differences between the different age groups was tested

III. FIGURES AND TABLES

Table 1 Descriptive statistics of the dimensions of Corpus Callosum (CC) and Brain in Sudanese population

Descriptive Statistics					
Morphometric index	N	Min(mm)	Max(mm)	Mean(mm)	STDV
Fronto Occipital Length	233	70.00	196.00	165.03	11.39
CC greatest anteroposterior diameter	233	52.00	163.00	74.33	7.49
Rostrum Maximum Thickness	233	0.30	3.00	1.24	.50
Genu Maximum Thickness	233	5.00	18.00	11.56	2.39
Trunk Maximum Thickness	233	2.70	9.00	6.21	1.34
Splenium Maximum Thickness	233	3.70	15.00	10.64	2.18
Fronto-Corpus Callosum Length	233	3.00	51.20	36.32	4.22
Occipito-Corpus Callosum Length	233	40.00	72.00	55.98	5.42
Corpus Callosum Index	233	0.034	0.514	0.37	0.06
CC greatest anteroposterior diameter /Fronto occipital length (<i>Ratio</i>)is 74.33/165.03=0.45					

Table 2 Descriptive statistics of the Brain dimensions in Sudanese population classified according to age

Descriptive							P-value
	N	Mean	STDV	Min	Max		
Fronto Occipital Length	<10	24	154.04	13.06	132.00	177.00	0.000
	11-20	33	163.67	10.49	143.00	196.00	
	21-30	37	166.37	8.44	153.00	190.00	
	31-40	49	168.85	7.46	154.00	186.00	
	41-50	40	164.92	16.71	70.00	187.00	
	51-60	17	166.19	8.64	153.00	180.00	
	>60	33	166.71	6.84	154.00	180.00	
	Total	233	165.03	11.39	70.00	196.00	
Fronto-Corpus Callosum Length	<10	24	38.78	3.52	32.00	44.00	.015
	11-20	33	36.91	3.71	29.00	47.00	
	21-30	37	36.20	3.27	31.00	48.00	
	31-40	49	34.89	5.49	3.00	42.00	
	41-50	40	36.22	3.10	30.00	46.00	
	51-60	17	37.17	5.84	32.00	51.20	
	>60	33	35.89	3.39	29.00	44.00	
	Total	233	36.32	4.22	3.00	51.20	
Occipito-Corpus Callosum Length	<10	24	55.45	6.55	43.00	65.00	.126
	11-20	33	56.54	5.71	44.00	67.00	
	21-30	37	56.54	5.21	47.00	72.00	
	31-40	49	57.50	4.88	48.00	68.00	
	41-50	40	54.62	5.08	44.00	63.00	
	51-60	17	53.91	5.11	46.60	63.00	
	>60	33	55.63	5.46	40.00	67.00	
	Total	233	55.98	5.42	40.00	72.00	

Table 3: Dimensions of Corpus Callosum compartments in Sudanese population classified according to age

Morphometric index	Age Class	N	Mean	Std.	Min	Max	P-value
CCAPD/(mm)	<10	24	61.50	6.69	52.00	80.00	0.000
	11-20	33	70.80	6.88	55.00	84.00	
	21-30	37	75.18	5.88	63.00	87.00	
	31-40	49	77.58	5.34	66.00	89.00	
	41-50	40	79.77	14.26	67.00	163.00	
	51-60	17	76.13	5.19	67.00	88.00	
	>60	33	76.93	5.30	67.00	92.00	
	Total	233	74.76	9.45	52.00	163.00	
RML/(mm)	<10	24	.77	.41	.30	2.40	0.000
	11-20	33	1.07	.43	.50	2.40	
	21-30	37	1.34	.43	.80	2.50	
	31-40	49	1.52	.46	1.00	3.00	
	41-50	40	1.31	.45	.80	2.60	
	51-60	17	1.35	.59	.50	2.80	
	>60	33	1.09	.48	.50	2.40	
	Total	233	1.24	.50	.30	3.00	
GML/(mm)	<10	24	8.81	1.97	5.00	13.00	0.000
	11-20	33	10.90	2.15	7.60	15.00	
	21-30	37	12.68	1.71	8.00	16.00	
	31-40	49	13.03	2.20	7.00	18.00	
	41-50	40	12.45	1.66	9.00	16.00	
	51-60	17	10.98	2.11	7.00	14.00	
	>60	33	10.01	1.85	7.00	15.00	
	Total	233	11.56	2.39	5.00	18.00	
BML/(mm)	<10	24	4.63	1.37	2.70	7.50	0.000
	11-20	33	5.88	1.29	4.00	8.00	
	21-30	37	6.75	.96	4.40	9.00	
	31-40	49	6.83	.98	4.70	9.00	
	41-50	40	7.05	.86	6.00	9.00	
	51-60	17	5.99	.75	5.00	7.00	
	>60	33	5.25	1.23	3.00	9.00	
	Total	233	6.21	1.34	2.70	9.00	
SML/(mm)	<10	24	7.88	1.57	4.00	10.00	0.000
	11-20	33	10.21	2.55	3.70	15.00	
	21-30	37	11.28	1.69	7.40	15.00	
	31-40	49	11.18	1.85	6.00	14.00	
	41-50	40	11.92	1.73	8.00	15.00	
	51-60	17	11.32	1.73	8.00	14.00	
	>60	33	9.66	1.64	7.00	13.00	
	Total	233	10.64	2.18	3.70	15.00	
CCI	<10	24	.34	.05	.267	.47	0.000
	11-20	33	.37	.08	.034	.51	
	21-30	37	.41	.04	.310	.50	
	31-40	49	.40	.04	.287	.48	
	41-50	40	.39	.07	.038	.50	
	51-60	17	.37	.04	.314	.45	
	>60	33	.33	.05	.236	.46	
	Total	233	.37	.06	.034	.51	

CCGAPD Stands for CC anteroposterior diameter, RMT for Rostrum Maximum Thickness ,GMT for Genu Maximum Thickness, for TMT Trunk Maximum Thickness, for SMT =Splenum Maximum Thickness, and CCI for Corpus Callosum Index .(sig at $p \leq 0.05$)

Table 4 Morphometric index/ chart established for brain and Corpus Callosum dimensions in Sudanese population for both genders at similar age classes

Morphometric index	Gender	Age Classes						
		<10	11-20	21-30	31-40	41-50	51-60	≥60
FOL/(mm)	Male	154.42 ±13.5	169.3 ±5.35	171.31 ±8.50	171.30 ±7.19	163.05 ±24.76	170.21 ±7.95	167.60 ±6.98
	Female	152.60 ±12.17	161.21 ±11.30	162.61 ±6.29	165.00 ±6.30	166.30 ±6.68	162.62 ±7.97	163.42 ±5.50
CCAPD/(mm)	Male	62.00 ±7.19	70.40 ±7.47	75.18 ±6.41	78.26 ±5.19	84.05 ±20.83	76.66 ±6.82	76.69 ±5.71
	Female	59.60 ±4.33	70.98 ±6.77	75.19 ±5.61	76.50 ±5.55	76.60 ±4.49	75.66 3.57	77.85 ±3.57
RMT/(mm)	Male	.80 ±.44	1.13 ±.49	1.42 ±.53	1.54 ±.39	1.46 ±.454	1.40 ±.79	1.08 ±.47
	Female	.66 ±.194	1.05 ±.420	1.27 ±.33	1.51 ±.55	1.20 ±.43	1.32 ±.38	1.12 ±.57
GMT/(mm)	Male	9.02 ±2.03	10.57 ±2.32	12.36 ±1.86	13.08 ±2.22	12.64 ±1.57	11.62 ±2.26	9.70 ±1.35
	Female	8.02 ±1.63	11.04 ±2.10	12.93 ±1.59	12.94 ±2.23	12.30 ±1.74	10.41 ±1.92	11.14 ±2.96
TMT/(mm)	Male	4.62 ±1.45	5.15 ±1.32	6.58 ±1.14	6.85 ±1.04	6.88 ±.78	6.08 ±.79	4.98 ±.90
	Female	4.68 ±1.21	6.20 ±1.16	6.89 ±.81	6.79 ±.90	7.18 ±.91	5.91 ±.75	6.27 ±1.80
SMT/(mm)	Male	7.70 ±1.57	9.36 ±2.65	11.00 ±2.08	11.43 ±1.79	11.97 ±2.13	11.30 ±1.97	9.46 ±1.54
	Female	8.58 ±1.51	10.58 ±2.47	11.50 ±1.33	10.78 ±1.93	11.87 1.41	11.35 ±1.59	10.42 ±1.90
FCCL/(mm)	Male	39.04 ±3.61	38.90 ±3.17	37.37 ±3.91	36.16 ±3.01	37.00 ±3.26	39.98 ±6.88	36.09 ±3.73
	Female	37.80 ±3.34	36.05 ±3.65	35.30 ±2.42	32.89 ±7.68	35.65 ±2.91	34.66 ±3.46	35.14 ±1.67
OCCL/(mm)	Male	54.89 ±7.01	59.80 ±5.99	59.06 ±5.07	58.69 ±5.35	53.58 ±4.80	54.45 ±6.18	55.88 ±5.77
	Female	57.60 ±4.33	55.12 ±5.08	54.61 ±4.53	55.64 ±3.39	55.39 ±5.24	53.44 ±4.27	54.71 ±4.38
C.C.I	Male	0.34 ±.05	0.35 ±.05	0.39 ±.044	0.40 ±.05	0.40 ±.04	0.37 ±.04	0.32 ±.05
	Female	0.35 ±.04	0.37 ±.09	0.41 ±.03	0.39 ±.03	0.39 ±.09	0.36 ±.03	.35 ±.06

FOL Stands for Fronto Occipital Length , CCAPD for CC greatest anteroposterior diameter,RMT for Rostrum Maximum Thickness ,GMT for Genu Maximum Thickness, for TMT Trunk Maximum Thickness, for SMT =Splenum Maximum Thickness, FCCL for Fronto-Corpus Callosum Length,OCCL for Occipito-Corpus Callosum Length, and CCI for Corpus Callosum Index

Table 5: Dimensions of Brain and Corpus Callosum compartments in Sudanese population classified according to gender with independent Samples Test.

Group Statistics					Independent Samples Test	
					Means	
Morphometric index	Gender	N	Mean	STDV	t	Sig. (2-tailed)
Fronto Occipital Length	Male	126	166.65	13.23	2.38	.018
	Female	107	163.11	8.43		
CC anteroposterior diameter	Male	126	75.15	11.36	.67	.499
	Female	107	74.31	6.56		
Rostrum Maximum Thickness	Male	125	1.27	.54	.82	.410
	Female	107	1.21	.46		
Genu Maximum Thickness	Male	126	11.33	2.45	-1.59	.112
	Female	107	11.83	2.30		
Trunk Maximum Thickness	Male	126	5.91	1.41	-3.77	.000
	Female	107	6.56	1.16		
Splenum Maximum Thickness	Male	126	10.31	2.34	-2.57	.011
	Female	107	11.04	1.92		
Fronto-Corpus Callosum Length	Male	126	37.31	3.88	3.99	.000
	Female	107	35.16	4.31		
Occipito-Corpus Callosum Length	Male	126	56.71	5.98	2.25	.025
	Female	107	55.12	4.55		
Corpus Callosum Index	Male	126	.37	.05	-2.17	.031
	Female	107	.38	.06		

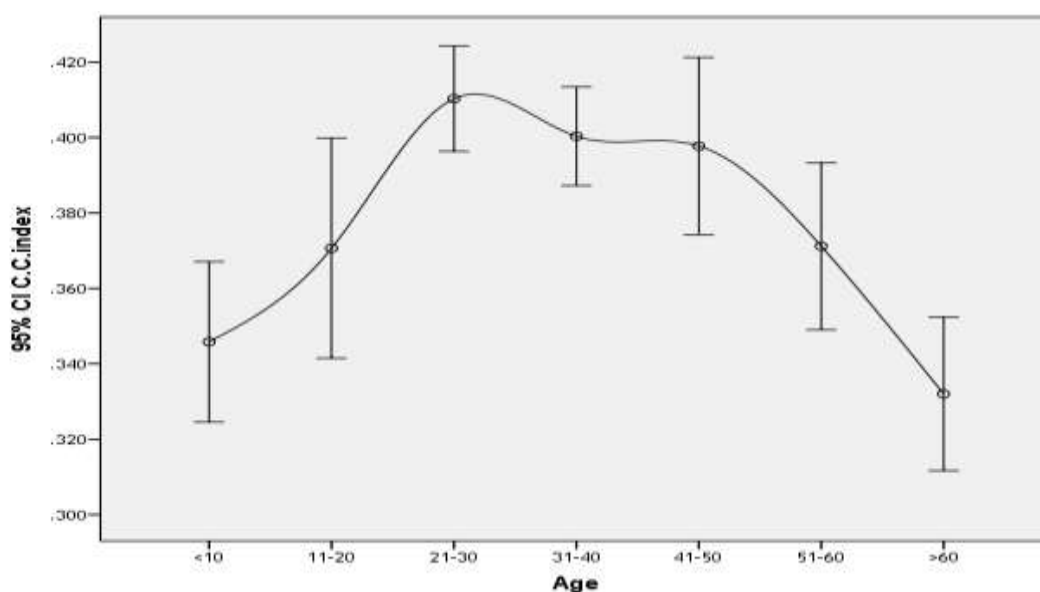


Figure (1) The maturation of corpus callosum considering the index and age classes during life development.

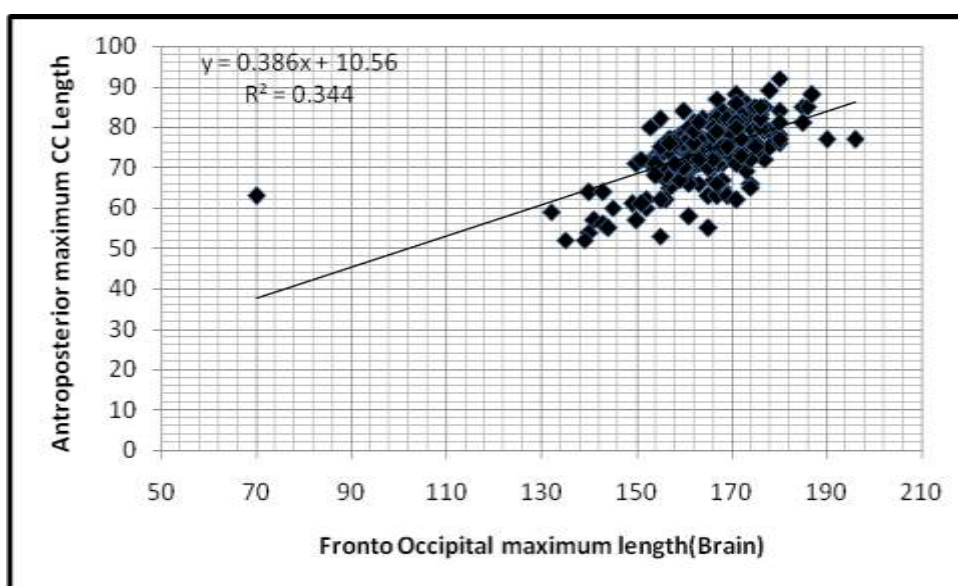


Figure (2) A scatter plot diagramme shows the linear relationship between the fronto occipital maximum length and CC maximum AP diameter. As the FOML increases the CCMAPD increase by 0.39 mm starting from 10.56 mm {the contribution of the FOML to do change in the CC measurement is 34%} ,{regression equation $y=0.386x+10.56$ }

IV. DISCUSSION

The (CC) is the major commissure connecting the cerebral hemispheres and there is evidence of its continuing development into young adulthood [20] However, few are known about changes in the characteristics of the CC compartments. Table (1) shows the measurements of the brain and the CC compartments for Sudanese measured in (mm). CC greatest anteroposterior diameter to Fronto occipital length (*Ratio*) was 0.45, that means it is around half of the brain measurement, the relation between them can be justified as that the segments of the CC (genu, body, rostrum and splenium) are topographically organized to carry interhemispheric fibers representing brain cortex and the development of each of these regions can provide approaching into the brain development. [21]The anatomical relation between the CC and brain is that CC is the main fiber tract connecting the two cerebral hemispheres.[22]These data reflect the fact that the fronto callosal maximum distance and CCMAPD have an association, as seen in figure (2) that shows the linear relationship between the two variables. As the FOML increases the CCMAPD increase by 0.39 mm starting from its measurement of 10.56 mm , the contribution of the FOML to do change in the CC measurement is 34%. Regarding the relation between the brain and CC dimensions in our study, we concluded that there is symmetry between the brain and the measurement of CC. This result is similar to Estruch *et al.* [23] and Mourgela *et al.*'s study (9) and another Iranian study [24]. Regression equation has been established for Sudanese CC: $y=0.386 x+10.56$; Corpus callosum maximum AP diameter (mm) = 0.386 X Frontocorpus maximum diameter (mm) +10.56.

We studied the age-related changes in the measurements of the brain and maximum thickness of the four compartments of the CC in the MRI scans of 233 healthy Sudanese individuals aged <10>60 years. The impact of age has been studied comprehensively as noticed in table (2) and (3). Fronto Occipital Length was found to be as maximum value at the age between 31-40 years with significant relation with the age except for occipital callosal length where no significant relation between this part and advancing age $p=0.126$. Total midsagittal measurements of the corpus callosum for all its compartments increased significantly across the age span although significant increases were limited to occipito-corporpus callosum length. Fronto-CC maximum value was found in the age <10 and measured 38.78mm. CCAPD/(mm)reached its maximum at the age of 41-50 (79.77mm) ,RML at 31-40(1.52mm), GML at 31-40(13.03mm) ,BML at 41-50(7.05mm),SML at 41-50(11.92mm) and CCI maximum maturation value at the age between21-30(0.41).

Table (4) presented morphometric index/ chart established for brain and CC dimensions in Sudanese population for both genders at similar age classes.

In our study without considering the gender, according to age group we observed development

of CC continued and showed statistical significant relationship between the age and its compartments at ($p < 0.05$). The significant relation between the fronto- occipital diameter of brain with age; and the maturation of the genu; is that they are correlated to each other's where the genu region is linked with the prefrontal cortex [25]. A similar view by Luders et al was given, they stated that genu growth may start in late adolescent period when frontal lobe is actively developed. [7] that is where the maximum value for the genu was found at the ages between 31-70 years in our study. Keshavan et al, has reported that between children and adolescent and between adolescent and young adults, the genu region is significantly increasing. [25] However, in their study, the distribution of age groups is obviously doesn't match with the age group in our recent study.

The gender has an impact on the changes detected in the brain and CC compartments except for the rostrum, genu, callosal AP maximum diameter. In a study done in Iranian population [24], there was no significant difference detected in CC diameters between genders. and they were similar to the findings of Takeda's study in Japan [15] and Tuncer's study in Turkey [26]. The current study showed that there is significant difference between the splenium in both genders as noticed in table (5). This findings was of reverse results to studies of human CC, who mentioned the insufficient evidence to support the presence of sex related differences in the size or shape of the splenium [27] other study showed no gender related difference of splenium in the Japanese [15] and in the Indians [28,29]. Another study showed no significant difference in splenial width found between males and females [30]. Another study found a significant gender related differences in the thickness of splenium. [24] However, on the basis of our findings in the present study, one can conclude that Sudanese differs from other population and there is significant sexual dimorphism in splenium. The differences on quantitative data of CC in various areas of the world which were seen in different studies may be due to racial/ethnic factors. [15,30]

Brain dimensions were significantly larger in males than in females ($P < 0.05$), and reverse findings were found in the CC trunk maximum thickness, splenium maximum thickness and CCI where females were greater than males with significant difference at 0.000, 0.011 and 0.031 respectively as noticed in table (5), similar results was mentioned by De- Lacoste-Utamsing and Holloway 1982 [31]. Some studies have reported greater width of trunk in females, [32,33] These findings were observed in our study. Another studies showed larger genu in males [32,34] and a larger anterior trunk in males. [32] Most studies have failed to find any evidence of sexual dimorphism in CC. Some studies have reported greater splenial width and area in females. [35-37] Bishop and Wahlstein [27] Witelson [32] also did not report any gender related differences in splenial areas. Similarly, an Indian study [34] also failed to find gender related difference in splenium. Our results concerning Sudanese were not in agreement with most of the literature.

The maturation of the CC has been described to begin at approximately 8 to 10 weeks of gestation. [38,39] Number of collosal fibers are fixed at birth, however, structural changes at CC continues due to myelination of fibers during postnatal development, redirection, pruning and myelination. [39] The complete formation of CC continues to enlarge throughout infancy, childhood, and young adulthood. [40] Schaefer et al stated that growing of CC continues till the 15 year age and during this period it could be reflections of increasing the myelinisation of CC. [41] On the other hand Simon et al claimed growing of CC continues until the 18th year-old. [42] In our study without considering the gender and according to age group we observed maturation of CC continued and showed significant increasing with age with maximum values for CCI were found at the ages between the 21-30 age and measured 0.41. One study done by Mehmet Ilkay Kosar 2012 [19] shows that the CCI was 0.44 ± 0.05 at the age 6-9 years, 0.46 ± 0.05 at 10-13 years and 0.45 ± 0.03 at the age 14-17 years old.

In our present study CCI showed significant difference between the two genders at $p=0.031$, CCI in males was 0.37 and in females was 0.38, it increased by increasing age and then it reduced thereafter figure (1) and table (5). Total midsagittal CCI (Splenium, body, Genu, rostrum and CC maximum AP length) increased strongly across this age span for both genders, although significant increases were limited for corpus to occipital brain regions. The maturation of brain and CC compartments across the age less than 10 and greater than 60 was presented in table (4) for both genders. It was considered as chart for Sudanese norms for development. The majority of maturational changes in the splenium of the CC across this age span suggests the anterior sections may have already reached their adult sizes in the childhood age 11-20 was (9.36 ± 2.65) for males and (10.58 ± 2.47) for females which is similar to the measures found at the age more than 60. This possibility was investigated by comparing our pediatric data to scans on adults subjects aged 20-60, acquired and analyzed in an identical approach, as noticed in table (4)

There were little differences between the adolescent and adult means in the rostrum; in the childhood ages between 11-20 and ages more than 60 for both genders as well the changes appears in the genu at the age group less than 10 years was found to be small for both males and females comparing to the subjects whose age greater than 60 years old. This is in contrast to the remaining mid and posterior part which was significantly smaller for the pediatric group. This supports the concept that the rostrum and genu plateau at adult sizes early in development. [43]

Ongoing development of the body/trunk of the CC is consistent with continued maturation of higher association well into adulthood, since a large amount of callosal fibers derived from these parts. [44] However aging affected this maturation, to be decreased by increasing age for both genders significantly. We had detected changes in the genu and rostrum regions in both genders, the changes was found to be due to age but not statistically correlated with gender. Perhaps the increasing frontal connectivity patterns of adolescence involve mainly intra hemispheric, as opposed to inter hemispheric, structures. This anterior-to-posterior CC maturation, reflects anterior/posterior patterns of inter hemispheric myelination and connectivity during normal development [43]

V. CONCLUSION

All dimensions of CC compartments and brain have significant relation with increasing age at $p=0.000$ except for occipito-corpus callosum length where no significant relation was detected ($p=0.126$). The gender has an impact on the changes detected in the brain and CC compartments except for the rostrum, genu, callosal AP maximum diameter. Brain dimensions were significantly larger in males than in females at ($P \leq 0.05$). Reverse findings were found in the CC trunk, splenium maximum thickness and CCI, where females were greater than males with significant difference at $P= 0.000, 0.011$ and 0.031 respectively. The CCI increased with age and then decreased thereafter. There was also a positive linear relationship between the AP length of the CC and the fronto-corpus callosum length. Regression equation for predicting the length of the CC and morphometric index of CC in the Sudanese population in both genders at similar age classes has been established. A local reference for normative data of Sudanese brain and CC morphometric indices has been established during maturation for both genders.

Acknowledgements

We sincerely thank the participants without whom the study would not have been feasible. The Sudan University of Science and Technology, College of Medical Radiological Science and at Modern Medical Center and Royal Care International Hospital, Radiology Department –in which the study was obtained, are thankfully acknowledged.

REFERENCES

- [1]. Timothy J. Herron, Xiaojian Kang and David L. Woods 2012 Automated measurement of the human corpus callosum using MRI *Frontiers in Neuroinformatics* www.frontiersin.org September |Volume6|Article25 | 1-15
- [2]. DiPaola, M., Spalletta, G., and Caltagirone, C. (2010). *In vivo* structural neuro anatomy of corpus callosum in Alzheimer's disease and mild cognitive impairment using different MRI techniques: a review. *J. Alzheimers Dis.* 20, 67–95.
- [3]. Frederiksen, K.S., Garde, E., Skimminge, A., Ryberg, C., Rostrup, E., Baaré, W., Siebner, H., Hejl, A.M., Leffers, A.M., and Waldemar, G. (2011b). Corpus callosum atrophy in patients with mild Alzheimer's disease. *Neurodegener. Dis.* 8, 476–482
- [4]. Hasan, K.M., Walimuni, I.S., Abid, H., Wolinsky, J.S., and Narayana, P. A. (2012b). Multi-modal quantitative MRI investigation of brain tissue neuro degeneration in multiple sclerosis. *J. Magn. Reson. Imaging.* 35, 1300–1311.
- [5]. Bearden, C.E., Van Erp, T.G.M., Dutton, R.A., Boyle, C., Madsen, S., Luders, E., Kieseppa, T., Tuulio-Henriksson, A., Huttunen, M., and Partonen, T. (2011). Mapping corpus callosum morphology in twin Pairs discordant for bipolar disorder. *Cereb. Cortex* 21, 2415–2424.
- [6]. Paul, L.K. (2011). Developmental malformation of the corpus callosum: a review of typical callosal development and examples of developmental disorders with callosal involvement. *J. Neurodev. Disord.* 3, 3–27.
- [7]. Luders E, Thompson PM, Toga AW. 2010 The development of the corpus callosum in the healthy human brain. *J Neurosci.*;18;30(33):10985-10990
- [8]. Gurd, J.M., Cowell, P.E., Lux, S., Rezai, R., Cherkas, L., and Ebers, G.C. (2012). fMRI and corpus callosum relationships in monozygotic twins discordant for handedness. *Brain Struct. Funct.* doi:10.1007/s00429-012-0410-9.
- [9]. Mourgela S, Anagnostopoulou S, Sakellaropoulos A, Gouliamos A. 2007 An MRI study of sex- and age-related differences in the dimensions of the corpus callosum and brain. *Neuroanatomy.*;6(1):63-5.10-14
- [10]. Peterson BS, Feineigle PA, Staib LH, Gore JC. 2001 Automated measurement of latent morphological features in the human corpus callosum. *Hum Brain Mapp.*;12(4):232-45.
- [11]. Bermudez P, Zatorre RJ. 2001 Sexual dimorphism in the corpus callosum: methodological considerations in MRI morphometry. *Neuroimage.*;13(6 Pt 1):1121-30.
- [12]. Luders E, Narr KL, Zaidel E, Thompson PM, Toga AW. 2006 Gender effects on callosal thickness in scaled and unscaled space. *Neuroreport.*;17(11):1103-6.
- [13]. Sullivan EV, Pfefferbaum A, Adalsteinsson E, Swan GE, Carmelli D. 2002 Differential rates of regional brain change in callosal and ventricular size: a 4-year longitudinal MRI study of elderly men. *Cereb Cortex.*;12(4):438-45.
- [14]. Luders E, Rex DE, Narr KL, Woods RP, Jancke L, Thompson PM, et al. 2003 Relationships between sulcal asymmetries and corpus callosum size: gender and handedness effects. *Cereb Cortex.*;13(10):1084-93.
- [15]. Takeda S, Hirashima Y, Ikeda H, Yamamoto H, Sugino M, Endo S. 2003 Determination of indices of the corpus callosum associated with normal aging in Japanese individuals. *Neuroradiology.*;45(8):513-8.

- [16]. Okamoto K, Ito J, Tokiguchi S. 1990 [The MR findings on the corpus callosum of normal young volunteers]. *Nihon Igaku HoshasenGakkai Zasshi.*;50(8):954-63
- [17]. Reinarz SJ, Coffman CE, Smoker WRK, Godersky JC. 1988MR imaging of corpus callosum: Normal and pathologic findings and correlationwith CT. *AJNR*; 9: 649-56.
- [18]. Figueira FF, Santos VS, Figueira GM, Silva AC. 2007Corpus callosum index: a practical method for long-term follow-up in multiple sclerosis. *Arq Neuro psiquiatr.*; 65 (4A):931-935.
- [19]. Mehmet Ilkay Kosar, Fatma Hayat Erdil, Vedat Sabanciogullari,Keziban Karacan, Mehmet Cimen, Mehmet 2012 A talar Morphometry of Corpus Callosum Related with Gender and Age: Magnetic Resonance Imaging Study Pak J Med Sci April - June Vol. 28 No. 3 408-412
- [20]. Pujol J, Vendrell P, Junque C, Marti-Vilalta JL, Capdevila A. 1993When does human brain development end? Evidence of corpus callosum growth up to adulthood. *Annals of Neurology*;34:71-5.
- [21]. Matcheri S. Keshavan, Vaibhav A. Diwadkar, Michael DeBellis,Elizabeth Dick, Rupali Kotwal, David R. Rosenberg, John A. Sweeney,Nancy Minshew, Jay W. Pettegrew (2002) Development of the corpus callosum in childhood,adolescence and early adulthood *Life Sciences* 70 1909-1922
- [22]. Eileen Luders, Paul M. Thompson, Arthur W. Toga 2010 The Development of the Corpus Callosum in the HealthyHuman Brain *The Journal of Neuroscience*, 30(33):10985-10990 • 10985
- [23]. Estruch R, Nicolas JM, Salamero M, Aragon C, Sacanella E, Fernandez-Sola J, et al. 1997Atrophy of the corpus callosum in chronic alcoholism. *J Neurol Sci.*;146(2):145-51.
- [24]. Mohammad Reza Mohammadi , Pouya Zhand , Behnoush Mortazavi Moghadam , Mohammad Jafar Gotalipour . Iran 2011Measurement of the Corpus Callosum Using Magnetic Resonance Imaging in the North of Iran *J Radiol.*;8(4):218-223. DOI: 10.5812/iranjradiol.4495
- [25]. Keshavan MS, Diwadkar VA, DeBellis M, Dick E, Kotwal R,Rosenberg DR, et al. 2002Development of the corpus callosum in childhood, adolescence and early adulthood. *Life Sci.*;70(16):1909-1922.
- [26]. Tuncer MC, Hatipoglu ES, Ozates M. 2005Sexual dimorphism andhandedness in the human corpus callosum based on magnetic resonance imaging. *Surg Radiol Anat.*;27(3):254-9.
- [27]. Bishop KM, Wahlstein D (1997): Sex differences in the human corpus callosum: myth or reality? *Neurosci Biobehav Rev* 1997; 21: 581-601.
- [28]. Banka S, Jit I. 1996Sexual dimorphism in the size of the corpus callosum. *J Anat Soc of India*; 45: 77-85.
- [29]. Suganthy J, Raghuram L, Antonisamy B, Vettivel S, Madhavi C, Koshi R. 2003Gender and Age related differences in the morphology of the corpus callosum. *Clin Anat*; 16: 396-403.
- [30]. Gupta T, Singh B, Kapoor K, Gupta M, Kochhar S.. 2009Normative Data of Corpus Callosal Morphology in a North-West Indian Population- An autopsy and MRI study. *J Nepal Med Assoc*; 48: 46-51.
- [31]. De Lacoste-Utamsing, C., and Holloway, R. L. 1982. Sexual dimorphism in the human corpus callosum. *Science* 216: 1431-1432.
- [32]. Witelson SF. 1989Hand and sex differences in the isthmus and genu of the human corpus callosum. A postmortem morphological study. *Brain*; 112: 799-835
- [33]. Clarke JM, Zaidel E. 1994Anatomical-behavioral relationships:corpus callosum morphometry and hemispheric specialization.*Behav Brain Res*; 64: 185-202.
- [34]. Banka S, Jit I. 1996Sexual dimorphism in the size of the corpuscallosum. *J Anat Soc India*; 45: 77-85
- [35]. Allen LS, Richey MF, Chai YM, Gorski RA. Sex differencesin the corpus callosum of the living human being. *J Neurosci*1991; 11: 933-42.
- [36]. Holloway RL, Anderson PJ, Defendini R, Harper C. 1993Sexual dimorphism of the human corpus callosum from three independent samples: Relative size of the corpus callosum.*Amer J of Phys Anthropol*; 92: 481-98.
- [37]. Davatzikos C, Resnick SM. 1998Sex difference in anatomic measuresof interhemispheric connectivity: Correlations with cognition in women but not men. *Cereb Cortex*; 8: 635-40.
- [38]. Barkovich JA, Kjos BO. 1988Normal postnatal development ofthe corpus callosum as demonstrated by MR imaging. *Am J Neuroradiol*;9:487-491.
- [39]. Barkovich JA, Norman D. 1988Anomalies of the corpuscallosum: correlation with further anomalies of the brain.*Am J Roentgenol.*;51:171-179.
- [40]. Dubovsky EC, Booth TN, Vezina G, Samango-SprouseCA, Palmer KM, Brasseux CO. 2001MR imaging of the corpus callosum in pediatric patients with neurofibromatosis type1. *Am J Neuroradiol.*;22(1):190-195.
- [41]. Schaefer GB, Thompson JN, Bodensteiner JB. 1990Quantitative morphometric analysis of brain growth using magnetic resonance imaging. *J Child Neurol.*;5:127-130.
- [42]. Simon JH, Schiffer RB, Rudick RA, Herndon RM. 1987Quantitative determination of MS-induced corpus callosum atrophy in vivo using MR imaging. *Am J Neuroradiol.*;8:599-604.
- [43]. Jay N. Giedd , Judith M. Rumsey, F. Xavier Castellanos, Jagath C. Rajapakse, Debra Kaysen,A. Catherine Vaituzis, Yolanda C. Vauss, Susan D. Hamburger, Judith L. Rapoport 1996 A quantitative MRI study of the corpus callosum in children and adolescents, *Developmental Brain Research* Volume 91, Issue 2, , Pages 274-280
- [44]. Pandya, D.N. and Rosene, D.L., 1985Some observations on trajectories and topography of commissural fibers. In A.G. Reeves (Ed.), *Epilepsy and the Corpus Callosum*, Plenum, New York, , pp.21-35.

*Caroline Edward Ayad. "A Quantitative MRI Study of the Normative Corpus Callosum in Sudanese." *IOSR Journal of Dental and Medical Sciences (IOSR-JDMS)* 16.7 (2017): 77-86.