

## Pillars to Immediate Loading

Dr Rajesh B Dhirawani<sup>1</sup>, Dr Kshitij Aggarwal<sup>2</sup>, Dr Sauvik Singha<sup>3</sup>,

Dr Jayant Marya<sup>4</sup>, Dr Jugojoyoti Pathi<sup>5</sup>

<sup>1</sup>Prof and Head of the department of oral and maxillofacial surgery,  
Hitkarini dental college and hospital

<sup>2,3</sup>PG Resident department of oral and maxillofacial surgery,  
Hitkarini dental college and hospital

<sup>4</sup>Consultant Oral and Maxillofacial Surgeon, Amritsar

<sup>5</sup>Senior Lecturer department of oral and maxillofacial surgery, Kalinga institute of dental sciences

Correspondence to: Dr. Sauvik Singha

---

### Abstract

**Introduction:** The immediate loading technique allows the placement of a temporary restoration supported by freshly inserted implants. The aim of this prospective study was to evaluate the concept of multicortical anchorage and Splinting as a suitable technique for immediate loading.

**Methods:** Thirty patients received Implants in edentulous regions to engage multiple cortices. These implants were used as a support for the interrim restoration, which was attached within 1 week of implant placement. Mean marginal bone loss and implant osseointegration were assessed using periapical radiographs immediately after surgery and at 6, 12, 24, and 36 months after placement.

**Results:** The results of this study revealed A total of 300 implants were consecutively placed in 30 adult patients between February 2011 and February 2014. 137 female and 163 male patients with 158 in maxillary cases and 142 in mandibular cases. The study concluded with high success rate (100%) with the immediate loading protocol. Average insertion torque, ISQ values, and bone quality assessments. At the 36-month follow-up, the accumulated mean marginal bone loss was within acceptable values.

**Conclusions:** The goal of an immediate loading protocol is to reduce the number of surgical procedures and to shorten the time frame without compromising the implant success rate. Engagement of multiple cortices helps achieve good primary stability and prevents macro movement. Splinting is able to resist the critical degree of micro movement at the bone implant interface. This study has confirmed that it is possible to successfully rehabilitate the edentulous patient within a week as implant placement with a interim fixed restoration.

**Keywords:** Immediate implant, multiple cortices, splint, intraoral welding

---

Date of Submission: 19-08-2017

Date of acceptance: 01-09-2017

---

### I. Introduction

The immediate loading technique allows the placement of a temporary restoration supported by freshly inserted implants. This protocol is increasingly requested by patients to overcome the esthetic and functional problems related to a two-stage procedure. Rehabilitation with a temporary, implant-retained restoration has already proved to be a viable option for the treatment of the edentulous patients,<sup>8-12</sup> at least when good primary implant stability could be obtained.<sup>13</sup> According to Adell et al<sup>1</sup> and Brånemark et al,<sup>2</sup> one of the prerequisites for establishing osseointegration is a nonloaded condition.<sup>1,2</sup> Strict surgical protocol requires a stress-free healing period of 3 to 6 months for osseointegration to occur between a titanium dental implant and the bone.<sup>3</sup> This stress free healing period is achieved by submerging the implant below the soft tissue and allowing the surgical site to heal without placement of any direct load on the implant. If the patient is edentulous, a 2 week period is recommended before a removable prosthesis is placed. When this protocol is followed, it is met with a high degree of success<sup>4</sup>. Schnitman et al<sup>5</sup> described a technique that avoids the need for a removable denture during this interim phase of therapy. With newer concepts the two stage protocol is fast being succeeded by immediate loading protocols. The aim of this prospective study was to evaluate the concept of multicortical anchorage and Splinting as a suitable technique for immediate loading.

### II. Materials And Methods

Thirty patients received Implants in edentulous regions which were placed strategically to engage multiple cortices. These implants were used as a support for the definitive restoration, which was attached

within 1 week of implant placement. Mean marginal bone loss and implant osseointegration were assessed using periapical radiographs immediately after surgery and at 6, 12, 24, and 36 months after placement.

**Patient inclusion criteria.**

Candidates for the study were selected from patients that presented for implant treatment at Hitkarini dental college and hospital (HDCH). The patients selected for treatment had to meet the following criteria:

1. Completely or partially edentulous.
2. Refused to wear a removable denture at any time during therapy.
3. The patient consented to the experimental protocol.
4. A medical history revealed no contraindication to implant therapy.

**Patient exclusion criteria:**

- 1) Purulent infection in the sites intended for implant placement
- 2) Systemic disease that could compromise osseointegration
- 3) Treatment with radiation therapy in the craniofacial region within the previous 12 months
- 4) Smoking >10 cigarettes per day
- 5) Pregnancy or lactation
- 6) Severe bruxism
- 7) Implants positioned with insertion torque <25 Ncm
- 8) Implant stability quotient (ISQ) <60 was recorded.

**Surgical procedure**

Local anesthesia was administered at the time of surgery. Surgery began with a midcrestal incision, a full-thickness flap was elevated, and in cases involving a knife-edge ridge, a minimal osteoplasty of the ridge was performed under profuse irrigation with sterile saline solution. Depending on the site of surgery, sensitive anatomical features, such as the mental foramina, were located and secured. All implants were placed without the use of any surgical template. Bone density was recorded after the insertion of each implant using the Lekholm and Zarb classification.<sup>7</sup> During the implant placement procedure, the insertion torque and the implant stability quotient (ISQ) were recorded using a torque wrench and a digital measurement probe (Osstell AB, Gamlestadsvägen 3B, Göteborg, Sweden)

No bone grafting material was used. Single layer closure was done using 3-0 (round body) vicryl. All implants were loaded within 1 week of surgery.

**Occlusal Considerations (Non Functional Loading)**

1. Narrow Occlusal tables and no offset loads on the transitional prosthesis
2. Long Axis Loads to the implant bodies
3. No posterior cantilever

**Case Discussion**

Thirty adult patients (15 males and 15 females) in good medical health were consecutively included in this prospective study between February 2011 and February 2014. All subjects provided written informed consent to participate in the study, which was conducted in accordance with the Helsinki Declaration of 1975, as revised in 2000. The mean age of the patients at the time of the surgery was 51.8 years. Each patient received a fixed restoration that was loaded to dental implants positioned in the edentulous region within 1 week of surgery. Three cases are discussed in brief in fig 1, 2

**III. Result**

A total of 300 implants were consecutively placed in thirty adult patients (15 males and 15 females) in good medical health in this prospective study between February 2011 and February 2014. The mean age of the patients at the time of the surgery was 51.8 years. 137 (45.66%) and 163 (54.33%) implants were, respectively, placed in female and male patients. 158 (52.66%) implants were placed in maxillary cases and 142 (47.34%) implants were placed in mandibular cases. The study concluded with high success rate (100%) with the immediate loading protocol. Average insertion torque, ISQ values, and bone quality assessments are listed in Table 2. At the 36-month follow-up, the accumulated mean marginal bone loss was within acceptable values. (Table 3)

#### **IV. Discussion**

The goal of an immediate loading protocol is to reduce the number of surgical procedures and to shorten the time frame between surgery and restoration placement without compromising the implant success rate. This study has confirmed that it is possible to successfully rehabilitate the edentulous patient within a week as implant placement with a definitive fixed restoration without jeopardizing osseointegration. Engagement of multiple cortices helps achieve good primary stability and prevents macro movement. Brunski has stated “Micro motion can be deleterious at the bone implant interface, especially if the micro motion occurs soon after implantation”<sup>15, 16</sup>

According to Brunski micro motion of more than 100 micrometers should be avoided and motion greater than this level will cause wound to undergo fibrous repair rather than the desired osseous regeneration.<sup>16</sup> Implants stabilized by splinting are able to resist the critical degree of micro movement at the bone implant interface. Non parallel Tilted implants further prevent micro as well as macro movement when splinted together. Hence immediate loading protocol has the following advantages.

1. Elimination of second stage surgery which saves the patient pain and suffering and also saves the dentist overhead time and material.
2. Patient does not have to wear removable prosthesis during healing phase which is uncomfortable
3. The soft tissue is allowed to mature for several months compared to a few weeks in two stage protocol. Tissue maturation is most important in esthetic zone (Fig2d)
4. In two stage protocol the implants are independent during healing. When immediately loaded they are splinted which is biomechanically superior. It results in better bone quality at bone implant interface

These 30 consecutive cases have led to us to follow these guidelines to help ensure clinical success for immediate loading.

1. Good Primary stability i.e. 45 Ncm or more by Active Implant design
2. Cortical anchorage
  - Engaging Opposing cortex in Maxilla[Sinus floor, Nasal floor, Pterygoid Plate]
  - Engaging socket wall of extraction socket
3. Splinting with Other implants or natural teeth as early as possible via intra oral welding or means of a screw retained prosthesis
4. Non functional Loading

#### **V. Conclusions**

The goal of an immediate loading protocol is to reduce the number of surgical procedures and to shorten the time frame without compromising the implant success rate. Engagement of multiple cortices helps achieve good primary stability and prevents macro movement. Splinting is able to resist the critical degree of micro movement at the bone implant interface. This study has confirmed that it is possible to successfully rehabilitate the edentulous patient within a week as implant placement with an interim fixed restoration

#### **Acknowledgment**

The authors would like to thank Dr Viney Aggarwal, Consultant Oral and Maxillofacial Surgeon, Aggarwal Dental Clinic

#### **References**

1. Adell R, Lekholm U, Roekler B, Brånemark P-I. A 15-year study of osseointegrated implants in the treatment of the edentulous jaw. *Int J Oral Surg* 1981;10:387-411.
2. Brånemark P-I, Hansson BO, Adell R, Beine U, Lindstrom J, Hallen O, Öhman A. Osseointegrated implants in the treatment of the edentulous jaw: Experience from a 10-year period. *Scand J Plast Reconstr Surg* 1977;2(suppl 16):1-132.
3. Brånemark P-I. Osseointegration and its experimental background. *J Prosthet Dent* 1983;50:399-410.
4. Zarb GA, Schmitt A. Osseointegration and the edentulous predicament. The 10 year Toronto study. *Br Dent J* 1991;170:4339-4414.
5. Schmitman PA, Wöhrle PS, Rubenstein JE. Immediate, fixed interim prostheses supported by two-stage, threaded implants: Methodology and results. *Oral Implantsol* 1990;16:96-105.
6. Goldman M, Cohen DW. *Periodontal Therapy*. ed 6. St Louis: Mosby, 1980:1133-1135.
7. Lekholm U, Zarb GA. Patient selection and preparation. In: Brånemark PI, Zarb GA, Albrektsson T, eds. *Tissue-Integrated Prostheses: Osseointegration in Clinical Dentistry*. Chicago, IL: Quintessence; 1985:199-209.
8. Salama H, Rose LF, Salama M, Betts NJ. Immediate loading of bilaterally splinted titanium root-form implants in fixed prosthodontics – A technique re-examined: Two case reports. *Int J Periodontics Restorative Dent* 1995;15:344-361.
9. Tarnow DP, Emtiaz S, Classi A. Immediate loading of threaded implants at stage 1 surgery in edentulous arches: Ten consecutive case reports with 1- to 5-year data. *Int J Oral Maxillofac Implants* 1997;12:319-324.
10. Grunder U. Immediate functional loading of immediate implants in edentulous arches: Two-year results. *Int J Periodontics Restorative Dent* 2001;21:545-551.
11. Olsson M, Urde G, Andersen J, Sennerby L. Early loading of maxillary fixed cross-arch dental prostheses supported by six or eight oxidized titanium implants: Results after 1 year of loading, case series. *Clin Implant Dent Relat Res* 2003;5:81-87.

12. Misch CE, Degidi M. Five-year prospective study of immediate/early loading of fixed prostheses in completely edentulous jaws with a bone quality-based implant system. *Clin Implant Dent Relat Res* 2003;5: 17-28.
13. östman PO, Hellman M, Sennerby L. Direct implant loading in the edentulous maxilla using a bone density-adapted surgical protocol and primary implant stability criteria for inclusion. *Clin Implant Dent Relat Res* 2005;7(Suppl. 1):S60-S69.
14. Misch CE, Contemporary Implant Dentistry
15. Brunski JB, Biomechanical factors affecting the bone—dental implant interface: Review paper. *Clin Mater* 1992;10:153-201.
16. Brunski JB. Avoid pitfalls of overloading and micromotion of intraosseous implants [interview]. *Dent Implantol Update* 1993;4(10):77—81.

**Figure - 1**

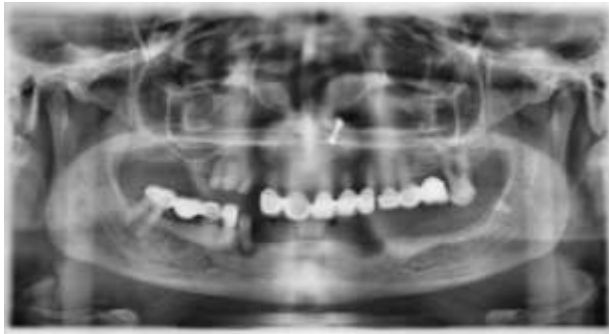

Fig 1a

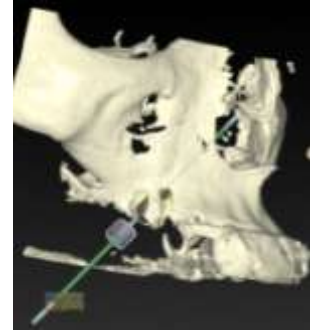


Fig 1b

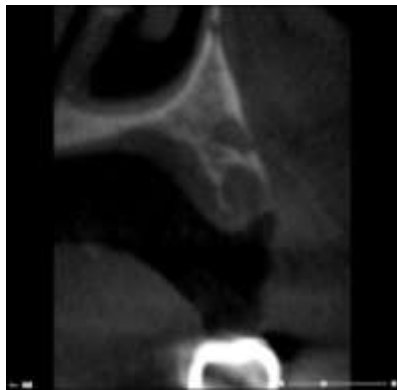

Fig 1c

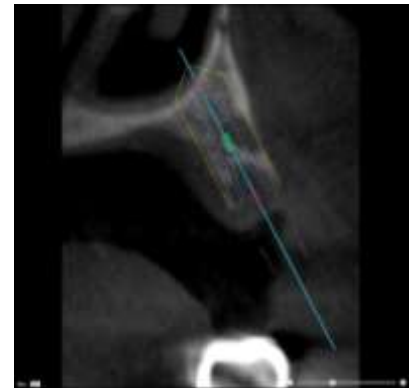


Fig 1d

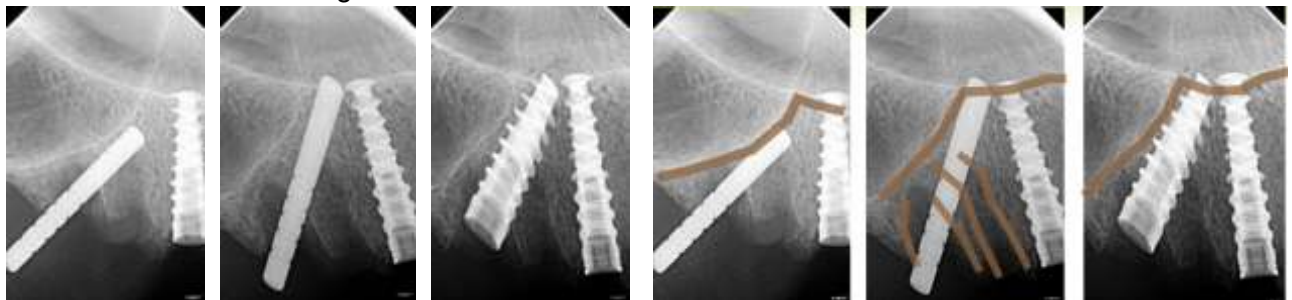


Fig 1e

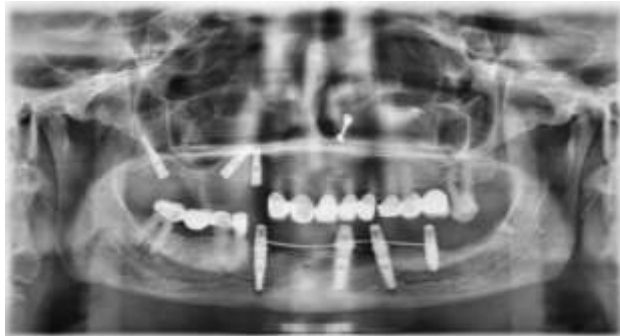

Fig 1f

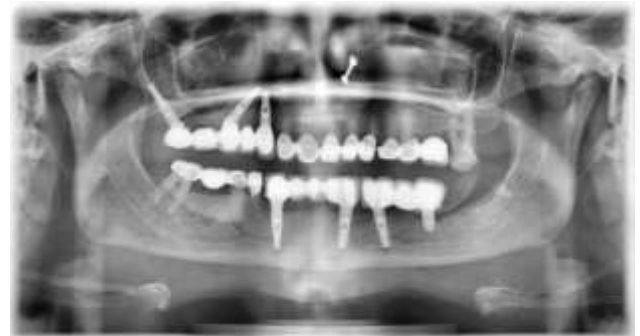


Fig 1g

Fig 1a: Preoperative OPG; Fig 1b:3D CBCT planning showing proposed angulations of the implant; Fig 1c, 1d: Oblique section through the CBCT showing path of implant and cortices it will engage during placement; Fig 1e: Intra op IOPA Showing implants engaging the planned cortices (cortices highlighted); Fig 1f: 6 months Post op OPG showing intra oral welded mandibular implants and maxillary implants; Fig 1g: 36 months post op OPG showing complete osseointegration.

Figure - 2

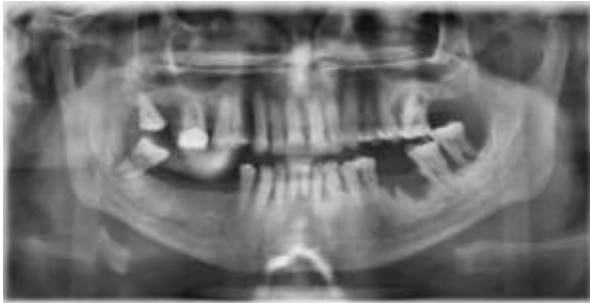


Fig 2a

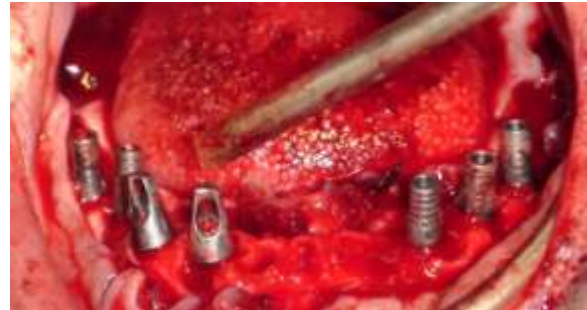

Fig 2b

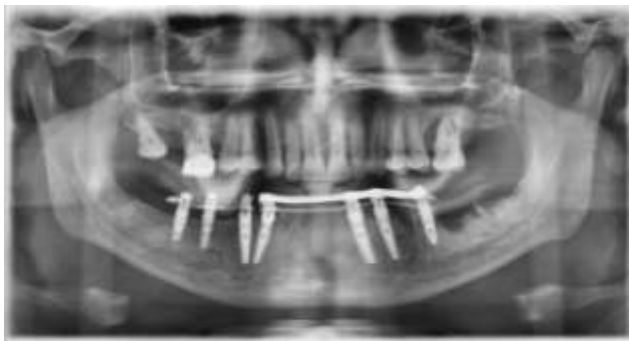

Fig 2c

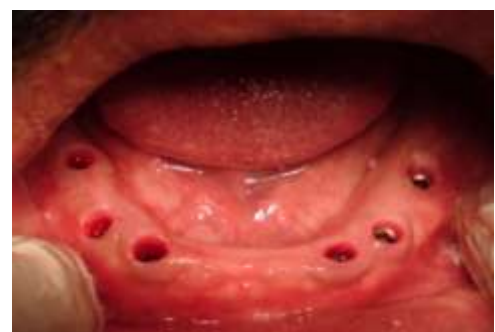

Fig 2d

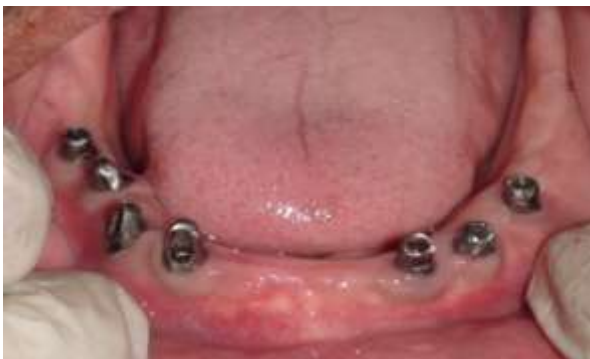

Fig 2e

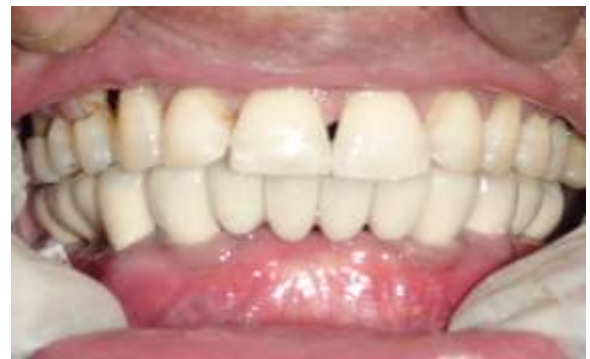

Fig 2f

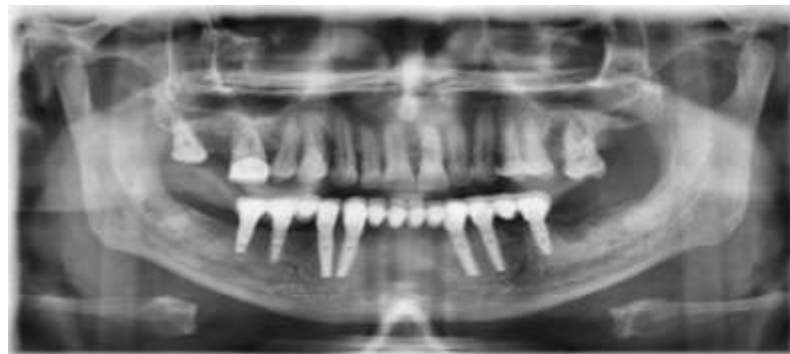


Fig 2g

Fig 2a: Pre operative OPG; Fig 2b: Implants placed and abutments torqued; Fig 2c 1 week post op OPG showing intraoral welding; Fig 2d:6 months post op interim abutment and prosthesis removed showing formation of attached gingival collar. Fig 2e, f: Placement of final prosthesis 6 months post op.Fig 2g: 36 Months post op OPG

**TABLE I- IMPLANT OSSEOINTEGRATION RATE**

<b>MONTHS</b>	<b>MAXILLARY IMPLANTS</b>	<b>MANDIBULAR IMPLANTS</b>	<b>IMPLANTS FAILED</b>	<b>IMPLANTS LOST TO FOLLOW UP</b>
<b>0</b>	158	142	0	0
<b>6</b>	158	142	0	0
<b>12</b>	150	140	0	10
<b>24</b>	150	140	0	0
<b>36</b>	146	136	0	8

**TABLE II - MEAN BONE LOSS**

<b>MONTHS</b>	<b>MAXILLARY IMPLANTS</b>	<b>MANDIBULAR IMPLANTS</b>
<b>0</b>	0	0
<b>6</b>	0.45	0.61
<b>12</b>	0.15	0.20
<b>24</b>	0.12	0.15
<b>36</b>	0.06	0.08

**TABLE III- MEAN INSERTION TORQUE AND ISQ VALUES**

<b>TORQUE / ISQ</b>	<b>MAXILLARY IMPLANTS</b>	<b>MANDIBULAR IMPLANTS</b>
<b>TORQUE (0 MONTHS)</b>	41	43
<b>ISQ(0 MONTHS)</b>	82	87
<b>ISQ (6 MONTHS)</b>	85	89

\* Dr Sauvik Singha “Pillars to Immediate Loading.” IOSR Journal of Dental and Medical Sciences (IOSR-JDMS) , Vol. 16, no. 08, 2017, pp. 65–70.