

## Adult Midgut Malrotation-An Unusal Case Report

\*<sup>1</sup>Dr.Nivash.S, <sup>2</sup>Dr.Statlin Raja.C

Place Of Study: Department Of General Surgery  
Rajah Muthiah Medical College And Hospital,  
Annamalai University,Chidambaram.

Corresponding author: \*<sup>1</sup>Dr.Nivash.S

---

**Introduction:** Malrotation of midgut is generally regarded as pediatric entity with majority of patients present during infancy and childhood. Adult midgut malrotation is very rare and its incidence has been reported to be 0.2% to 0.5%. we report a case of an adult patient with midgut malrotation.

**Methods:** A 38 years old moderately built and nourished gentleman was admitted to the accident and emergency department with upper abdominal distension for 10 days and vomiting for 5 days. H/O similar complaints on and off for the past 2 years. On examination, the patient was afebrile and haemodynamically stable. Abdomen distended over epigastrium. Palpation revealed no mass/organomegaly. patient was catheterized and Ryle's tube was inserted. Input /output charts, BP chart, Abdominal Girth chart monitored. Routine investigations were within normal limits. USG abdomen & X-ray abdomen revealed dilated bowel loops. CECT-abdomen reported as midgut malrotation without volvulus. Gastrograffin study was done once distension relieved which confirmed the diagnosis of midgut malrotation.

**Results:** The patient was resuscitated with IV fluids, analgesics and planned for surgery. Intra-op Ladd's band with malrotated gut was present. Ladd's procedure with gastrojejunostomy was carried out. The patient had an uneventful postoperative recovery and was discharged home on the seventh day. Patient is on regular follow-up.

**Conclusion:** Anomalies like midgut malrotation can present as an operative surprise and awareness regarding these anomalies can help surgeons to deal with these conditions. It usually needs surgical intervention to prevent Intestinal Obstruction and volvulus.

**Keywords:** Malrotation, Intestinal obstruction, Ladd's procedure.

---

Date of Submission: 01 -08-2017

Date of acceptance: 23-08-2017

---

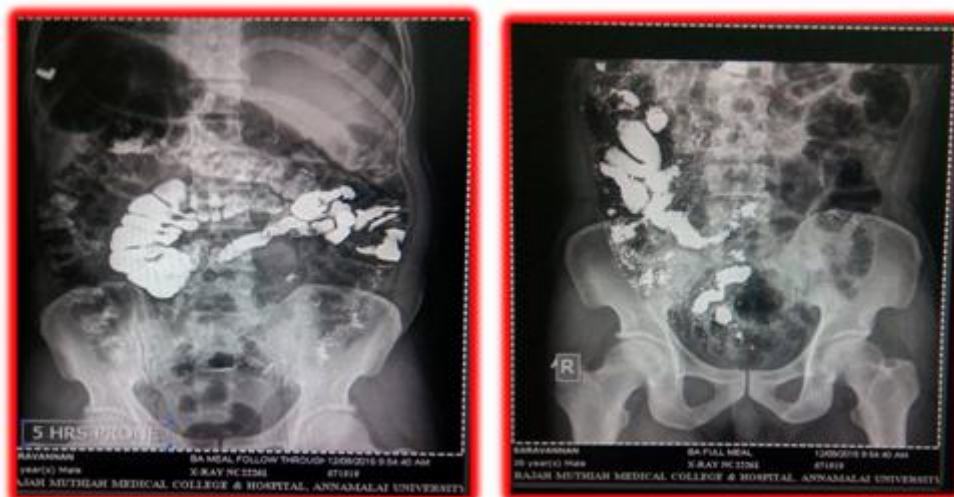
### I. Introduction

Intestinal malrotation refers to the partial or complete failure of 270 degree counterclockwise rotation of midgut around the superior mesenteric vessels in embryonic life. Arrested midgut malrotation results due to narrow based mesentery and increases the risk of twisting midgut and subsequent obstruction and necrosis. Most of the patients with malrotation present within first month of life and intestinal malrotation in adults is in ratio of 0.2-0.5%. Adult malrotation usually presents with intermittent colicky pain and bile stained vomiting. malrotation is the most frequent reason of midgut volvulus in adult and obstruction is observed mostly in colon. We report a case of an adult patient with an acute presentation of midgut malrotation which highlights the dilemmas of preoperative diagnosis, as supported by a review of the literature.

### II. A Case Report

A 38-year old gentleman was admitted to the Accident and Emergency department with upper abdominal distention for 10 days and vomiting 5 days. H/O similar complaints on and off for the past 2 years. There were no other associated red flag symptoms. The patient had no previous surgical history. On examination, the patient was afebrile and haemodynamically stable. The abdomen was moderately distended with significant tenderness in the epigastric region. There was no evidence of peritonitis. Routine admission blood tests including serum electrolytes, urea, amylase, lipase, liver function tests (LFTs), cbc, creatinine, clotting profile, C-reactive protein (CRP) and an arterial blood gas (ABG) were normal. A chest radiograph did not reveal air under the diaphragm. Abdominal radiograph showed dilated gas filled loops of bowel in the central and upper abdominal regions. The diagnosis remained elusive and hence planned for contrast computed tomography (CT) scan was obtained which demonstrated features of malrotation. Gold standard gastrograffin study was done to confirm the diagnosis which revealed malrotation of midgut.

GASTROGRAFFIN STUDY



The patient was resuscitated with intravenous fluids, analgesia and prepared for surgery. Initially diagnostic laparoscopy was performed to confirm the diagnosis and laparotomy was performed. The intra operative findings include

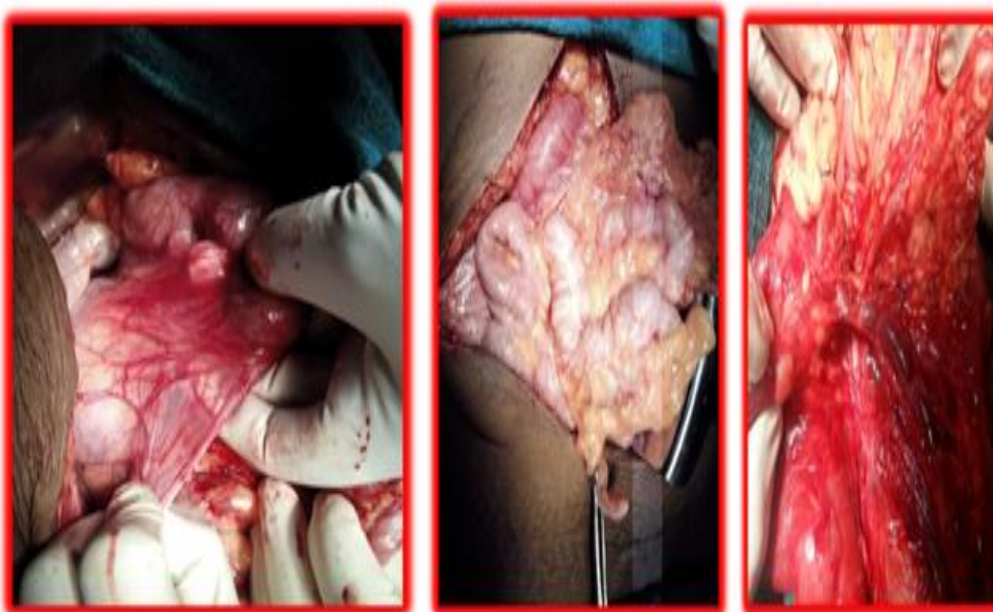
**Operative Findings**

Small bowel on the right side and caecum in the midline.

Straight duodenum to the right of vertebra

SMV is behind the third part of duodenum

Ladd's band extending from the Liver, caecum and ascending colon to the second and third part of duodenum.



LADD'S Procedure and Gastrojejunostomy was performed

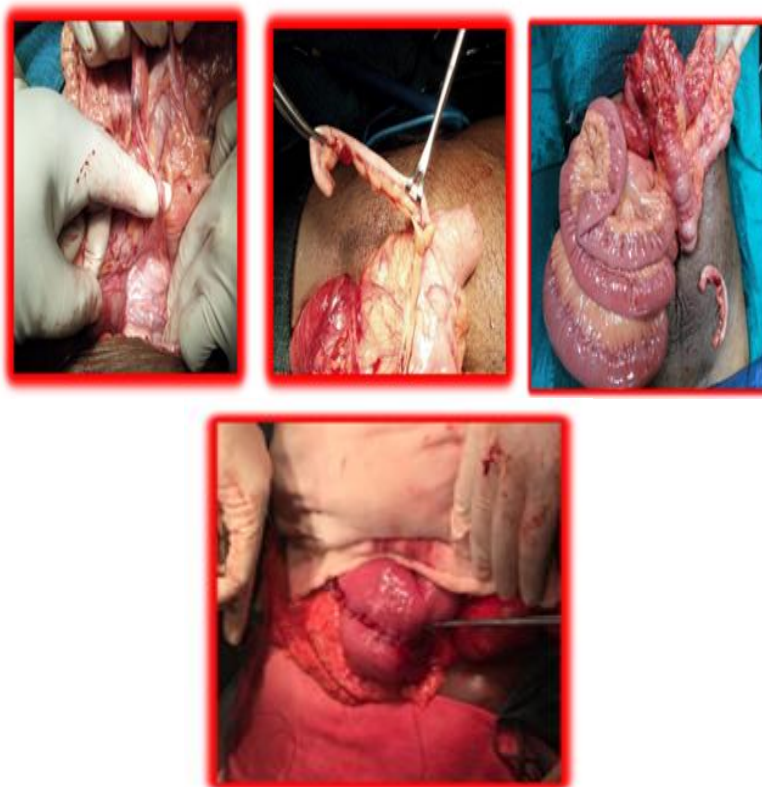
Ladd's band released

Small bowel mesenteric base widening done

Appendicectomy done

Small bowel kept on the right side and large bowel kept on the left side

Gastro jejunostomy done



The patient had an uneventful postoperative recovery and was discharged home on the seventh day post- surgery. On follow up he was well and there had been no late complications. He had returned to his premorbid level of function and did not report any symptom recurrence.

### **III. Discussion**

Initial presentation of symptomatic midgutmalrotation is rare in adults. However, a significant number of cases remain quiescent during childhood. Incidental diagnosis may then occur in adulthood; when imaging investigations are carried out for other symptoms or, during surgery for unrelated pathology. It has been reported that the incidence of malrotation in adults is approximately 0.2%. However, it is probable that this rate will rise with future developments in diagnostic imaging. It is difficult to ascertain the true incidence, but evidence from post mortem studies suggest that gut malrotation may affect up to 1 in 6000 Midgutmalrotation is broadly considered a deviation from the normal 270 degree counterclockwise rotation of the gut during embryonic development. During week 4 of foetal development, the embryonic gut, consisting of a straight endodermal tube, develops vascular pedicles to be divided into the foregut, midgut and hindgut based on the anatomical blood supply. The midgut is supplied by the superior mesenteric artery (SMA) and by the fifth week of embryonic life, it begins a process of rapid elongation and outgrows the capacity of the abdominal cavity. This leads to a temporary physiological herniation into the umbilical cord at about the sixth week of life with return to the abdominal cavity about 4 to 6 weeks later. During this period, the midgut undergoes a 270 degree counterclockwise rotation around the SMA axis. This process leads to the formation of the duodenal C-loop, placing it behind the SMA in a retroperitoneal position and emerging at the ligament of Treitz. The progressive reduction of the physiological midgut herniation commences at about week 10 of embryonic development. The duodeno-jejunal flexure (DJF) and jejunum to reduce first and lie to the left. The distal small bowel then follows and lies progressively to the right of the abdominal cavity. The descent of the caecum from its higher position in the right upper quadrant forms the latter part of this complex rotational development; it becomes positioned in the right lower abdomen. The ascending colon then assumes a retroperitoneal position, also on the right side. The base of the small bowel mesentery subsequently fuses with the posterior peritoneum in a diagonal fashion, from the ligament of Treitz at the DJF to the caecum, completing the whole process at about the eleventh week of foetal development

The failure of the normal physiological rotation of the midgut leads to various degrees of anomaly including the entire small bowel remaining on the right side of the abdomen, the caecum, appendix and colon on the left and an absent ligament of Treitz. In addition, the small bowel mesentery may develop a narrow vertical

attachment and the peritoneal fibrous bands fixing the duodenum and caecum to the abdominal wall may persist. These congenital bands extend from the right lateral abdominal wall, across the duodenum and attach to the undescended caecum and are known as Ladd's bands. Ladd's bands compress the duodenum and can potentially cause duodenal obstruction. The malrotation of the gut and abnormal location of the caecum produces a narrow superior mesenteric vascular pedicle, as opposed to the normally broadbased small bowel mesentery. This narrow SMA takeoff and lack of posterior peritoneal fusion predispose to subsequent midgut volvulus and obstruction with potential vascular catastrophe.

The classic treatment for incomplete intestinal rotation is the Ladd procedure, which entails counterclockwise detorsion of the midgut volvulus (if present), division of the abnormal coloduodenal Ladd bands tethering the midgut and causing extrinsic compression, widening of the mesenteric base to prevent further volvulus and removal of the malpositioned appendix. These principles have remained the same since Ladd's address to the New Hampshire Medical Society in 1936. Generally, symptomatic patients with malrotation should be treated surgically. Moreover, Spigland et al. recommended that all patients with malrotation are candidates for laparotomy, even if they are asymptomatic, because the complications associated with intestinal malrotation are based on anatomical reasons that do not alter with age, thus the potential to develop sudden onset of acute midgut volvulus in an asymptomatic patient, at any age, exists.

Recently, laparoscopic techniques for treating malrotation in both infants and adults have been described. The laparoscopic experience with adults has consisted primarily of isolated case reports, till Mazziotti et al. recently reported a series of malrotation patients managed successfully with laparoscopic intervention. Moreover, Matzke et al. published their comparative results for open and laparoscopic Ladd procedures, concluding that the laparoscopic Ladd procedure is feasible, safe and as effective as the standard open Ladd procedure for the treatment of adults who have intestinal malrotation without midgut volvulus. Similar conclusions are presented by Seymour et al, who also noted that long-term follow-up will be required to determine whether patients are at risk for either new symptoms or recurrent malrotation-related problems such as midgut volvulus.

#### **IV. Conclusion**

Intestinal malrotation is a rare condition but is considered an important cause of bowel obstruction in adults. The diagnosis of malrotation after childhood is difficult and usually not readily considered as the cause of intra-abdominal symptoms. The presentation is usually nonspecific and this often leads to diagnostic and treatment delay with possible bowel ischaemia and necrosis. Evidence of which portends a poor prognosis and death. Therefore, a high index of suspicion needs to be maintained and prompt surgical intervention must be considered in order to prevent an abdominal catastrophe and fatality. There are no reliable means of identifying which group of patients with intestinal malrotation will develop subsequent complications. In the light of this, many authors are now advocating early surgical intervention in the form of a standard and modified Ladd's procedure. There is evidence in the literature that the use of Ladd's procedure or ordinary division of Ladd's bands and adhesiolysis relieves symptoms and in fact, prevents recurrence in the majority of patients.

#### **References**

- [1]. Frazer TE, et al. On the factors concerned in causing rotation of the intestine in man. *J AnatPhysiol* 1915;50:75.
- [2]. Powell DM, Othersen H, Smith CD. Malrotation of the intestines in children: the effect of age on presentation and therapy. *J PediatrSurg* 1989;24:777-780.
- [3]. Fukuya T, Brown BP, Lu CC. Midgut volvulus as a complication of intestinal malrotation in adults. *Dig Dis Sci* 1993;38:438-444.
- [4]. Spigland N, Brandt ML, Yazbeck S. Malrotation beyond the neonatal period. *J PediatrSurg* 1990;25:1139-1142.
- [5]. Von Flue M, Herzog U, Ackermann C, et al. Acute and chronic presentation of intestinal nonrotation in adults. *Dis Colon Rectum* 1994;37:192-198.
- [6]. Ladd WE. Surgical diseases of the alimentary tract in infants. *N Engl J Med* 1936;215:705.
- [7]. Torres AM, Ziegler MM. Malrotation of the intestine. *World J Surg* 1993;17:326-331.
- [8]. McIntosh R, Donovan EJ. Disturbances of rotation of the intestinal tract. *Am J Dis Child* 1939;56:116-166.
- [9]. Frantzides CT, Cziperle DJ, Soergel K, Stewart E. Laparoscopic Ladd procedure and cecopy in the treatment of malrotation beyond the neonatal period. *LaparoscEndoscPercutan Tech* 1996;6:73-75.
- [10]. Mazziotti MV, Strasberg SM, Langer JC. Intestinal rotation abnormalities without volvulus: the role of laparoscopy. *J Am CollSurg* 1997;185:172-176.
- [11]. Gohl ML, DeMeester TR. Midgutnonrotation in adults. *Am J Surg* 1975;129:319-323.
- [12]. Ladd WE. Congenital obstruction of the duodenum in children. *N Engl J Med* 1932;206:273-283.
- [13]. Wang C, Welch CE. Anomalies of intestinal rotation in adolescents and adults. *Surgery* 1963;54:839-855.
- [14]. Firor HV, Steiger E. Morbidity of rotational abnormalities of the gut beyond infancy. *Cleve Clin Q* 1983;50:303-309.

\*Dr.Nivash.S. "Adult Midgut Malrotation-An Unusal Case Report." *IOSR Journal of Dental and Medical Sciences (IOSR-JDMS)* 16.8 (2017): 01-04