

Effect Of Different Pick-Up Techniques On The Retention & Patient Satisfaction Of Implant-Supported Mandibular Overdenture With Locator Attachment

*Mostafa Helmy Mostafa Ahmed

B.D.S., M.Sc., Ph.D. (lecturer of Removable Prosthodontics/ Faculty of Dentistry, Cairo University, Egypt)

Abstract

Objectives: The aim of this study was to compare the effect of Direct & Indirect pick-up techniques on The Retention & Patients' satisfaction of implant-supported mandibular overdenture with locator attachment.

Materials & methods: For the outcome of this clinical research study, twenty fully edentulous patients received new mandibular and maxillary complete dentures prior to implant placement. Every patient was instructed to use the denture for two months. After two months; each patient received four implants in the mandible by the aid of a computer-guided surgical stent. After ensuring complete osseointegration of the implants; patients were randomly divided into two groups; First group (of ten patients) had completed the procedures of fabricating Implant-supported overdenture with locator attachment using Direct pick-up technique (chair-side technique), while Second group (of ten patients) had completed the procedures of fabricating Implant-supported overdenture with locator attachment using Indirect pick-up technique (Laboratory-assisted pick-up technique). Retention of the Implant-supported overdentures was measured Five times (at time of insertion, one month, three months, six months and one year respectively), utilizing A Digital Forcemeter device. In addition, patients' satisfaction was also measured utilizing a customized chart of question (A five-point scale).

Results: For parametric data; Repeated measures Analysis of Variance (ANOVA) was used to study the changes by time, while for non-parametric data; Friedman's test was used to study the changes by time. Those studies revealed that: there was no significant changes in Retention as well as Patients' satisfaction scores between both groups throughout the whole study period.

Conclusion: locator attachments are highly recommended to retain mandibular overdentures, as they exhibited high retention values with minimal loss of retention. In addition, Patients were completely satisfied with their implant-supported overdentures, whatever the pick-up technique utilized.

Keywords: Overdenture, Patient satisfaction, Pick-up technique, Dental implants, Retention.

Date of Submission: 18-09-2017

Date of acceptance: 25-09-2017

I. Introduction

Completely edentulous patients often have problems with their mandibular complete dentures; a treatment modality of using two to four implants to support a mandibular overdenture has been proposed to improve the retention as well as the stability of the mandibular denture, in addition to preserving the residual alveolar bone. [1]

Several worldwide research studies tested the impact of implant-assisted overdentures on satisfaction and quality of life and concluded that; individuals with implant-assisted overdentures were more satisfied and had a better oral health quality than others with conventional dentures. [2-4] Four implant-supported overdentures are indicated in clinical conditions requiring high values of retention and stability; such as cases of high muscle attachments. [5]

Implant-retained overdentures offered a simpler, cheaper and equally successful prosthetic solution compared to the fixed restorations in the rehabilitation of maladapted edentulous mandibles. Moreover, they provide enhanced masticatory function, higher patients' satisfaction and quality of life than the conventional complete dentures. [6] Systematic reviews comparing implant-supported overdentures retained by utilizing a wide range of attachment mechanisms were recently published.

The implant-supported treatment modality might be in the form of splinted implants (e.g. bar-retained overdentures), or unsplinted implants (as in case of ball, locator or magnetic attachments). Owing to the smaller space requirements, ease of cleaning, more economical achievement and lower technique sensitivity; unsplinted attachments have been preferred over splinted ones. [7-9]

The most common maintenance requirement of any overdenture attachment, found to be the renewal or reactivation of the retentive element. Moreover, attachment systems exhibit wear during function, with subsequent decrease and even loss of retention. [10]

Effect Of Different Pick-Up Techniques On The Retention & Patient Satisfaction Of Implant-Supported Mandibular Overdenture With Locator Attachment

Inadequate inter-arch space found to be one of the major causes of bulk fracture of the acrylic denture base. Furthermore, it might lead to inappropriate positioning of the denture teeth with subsequent esthetic & phonetic problems. [11] Locators attachments presented the lowest profile of the currently available stud attachments. Moreover, they offer simplicity as well as modest space requirements. Furthermore, they provide a dual retention (obtained from the inner and outer contact surfaces between their male and female portions) and finally; easy handled by the patient with less cost effectiveness. [12]

Regarding the locator structure; it consists of a female matrix, which is a titanium nitride coated cylindrical abutment having internal & external undercuts, and a male matrix, represented as a metallic housing into which different nylon inserts could be placed, according the needed amount of retention. [13] Findings suggested that; depending on the attachment system used, the degree of patient satisfaction is directly affected by the amount of retention and stability of the implant-supported overdenture. [14-17]

The goal of this clinical investigation was to compare the effect of two different pick-up techniques for an implant-assisted overdenture, in terms of retention and patient satisfaction. The null hypothesis was that; there will be no significant difference between the two techniques throughout the entire study period.

II. Materials and Methods

Twenty patients were carefully chosen from the outpatient clinic of the Diagnosis department, Faculty of Oral and Dental Medicine, Cairo University. Where, patient selection was conducted according to the following criteria:

- Age ranged between 45-60 years.
- Patients with completely edentulous arches (mandible & maxilla). (*Fig. 1*)
- Patients exhibited sufficient inter-arch space (at least 15 mm. from the mandibular ridge to the occlusal plane).
- Patients with good oral hygiene.
- Patients free from bad oral habits, patients with tempo-mandibular joint troubles were excluded.
- Patients free from any systemic or debilitating diseases such as diabetes mellitus, bone diseases, blood discrasia or other diseases that affect bone healing around the implants.
- Absence of any medical disorder that might obscure the surgical phase or disturb osseointegration.
- Patients with Angle's class I maxillo-mandibular relationship with normal occlusion.
- Heavy smokers (more than 30 cigarettes per day), were omitted from this study.
- Uncooperative patients were excepted, where only cooperative patients were included in the study

The patients were asked for their approval to the conduction of the research & being recalled for follow-up appointments. All details were written & signed by the patients in consent forms.

The study was conducted according to principles stated in Helsinki Declaration & being approved by the Faculty ethical committee.

After taking full patient's personal, medical and dental history, each patient received a thorough clinical and radiographic examination.

II.1. Construction of the complete dentures prior to surgery

- Upper and lower primary impressions were made utilizing alginate impression material* according to the manufacturer's instructions and poured into stone plaster ** to attain diagnostic casts over which acrylic resin ***special trays were fabricated.
- For every patient, the casts were mounted on a simple hinge articulator aided by a Tentative inter-occlusal wax record. Afterwards, the occlusal relation between the upper and lower teeth was thoroughly examined.
- Final impressions were made by two-step rubber base impression material **** according to the manufacturer's instructions.
- Master casts were obtained, Occlusion blocks were constructed centric jaw relation was recorded using the traditional wax-wafer method.
- Occlusion blocks on their master casts were mounted on semi-adjustable articulator, where, the upper cast was mounted according to a face bow record & the lower cast was mounted by the aid of the recorded centric jaw relation record.
- Setting-up of teeth then, Try-in stage was carried out in the usual manner. When assuring satisfactory Try-in, the dentures were completed till obtaining the final maxillary & mandibular complete dentures following the traditional steps of construction.

*Cavex alginate, dust free, high consistency, Holland.

****Panasil, Katzenbach, Germany.

**Type III dental stone Lascod SP, sestofino, Italy.

***Moldano. Bayer Leverkusen, pekatrav, Germany.

Effect Of Different Pick-Up Techniques On The Retention & Patient Satisfaction Of Implant-Supported Mandibular Overdenture With Locator Attachment

Patients were asked to utilize their dentures for two months of adaptation with a recall appointment every single week for denture assessment & any needed occlusal refinement.

It is worth to clarify that all dentures were fabricated by the same dental technician in the same laboratory.

II.2. Patient imaging and case planning

- ❖ Duplication of the mandibular complete denture was encountered utilizing a radio-opaque material to construct radiographic stents for every patient.
- ❖ Patients were imaged using cone beam computed tomography scans (CBCT scans) through a cone beam CT machine (CBCT, i-CAT Vision) *. each patient was instructed to bite on a piece of cotton to achieve adequate jaw separation. Finally, the resultant image was obtained as a DICOM file.
- ❖ The images were processed using specialized image processing software (Blue Sky implant software) **.

II.3. surgical guide fabrication

virtual implants were placed in the position of lower lateral incisors & second premolars, A solid block was modeled & guiding holes denoting the implant direction were opened into the block. The final virtual guide was exported as an STL file to be prototyped using a 3D printer***. The obtained guide was modified by inserting specially designed metallic sleeves to accommodate the drills.

II.4. Pre-surgical steps

- the surgical stent was sterilized chemically**** to be used during surgery.
- The patient was instructed to take a prophylactic antibiotic preoperatively*****and to rinse with chlorohexidine mouth wash*****4 hours before surgery.

II.5. Surgical procedures

Two-stage surgery was followed and the patients could wear their dentures during the healing period in-between:

II.5.1. First surgical phase

- The entire surgical armamentarium was autoclaved.
- The surgical place as well as the circumoral tissues were also disinfected by wiping them with antiseptic solution*****.
- A mandibular nerve block anaesthesia was given at the surgical site using 4% articaine anesthetic solution*****. Also, field block anaesthesia was applied to diminish the bleeding as much as possible.
- The surgical template was introduced into the patient's mouth, seated over the mandible and checked for accuracy & stability in place.
- Osteotomy sites for the 4 implants were performed using a pilot drill of 2.3mm diameter & a final drill of 2.8mm diameter. For each drill, a specially designed "drill guide" was used. The drill guide is a cylinder with a short handle. The thickness of the handle was 1mm. The outer diameter of the drill guide fitted accurately within the metal sleeves fixed into the stent.
- The drills and the drill guide were supplied in a specially designed autoclavable surgical kit***** used with the computer-guided surgical stent.

II.5.2. Implant insertion:

- The sterile box of the implant *****was unwrapped, and then the inner vial was also opened & the implant osteotomy was washed thoroughly using sterile saline solution.
- The sterile implant was introduced into its site by screwing it using moderate finger pressure [self-tapping] Once resistance was felt, the abutment was unscrewed from the implant fixture & the ratchet wrench was adapted to the implant and the screwing process was continued.
- The screwing process was stopped when the implant becomes flushed with the crest of the bone or preferably 0.5mm below the crestal bone level.
- The universal hex driver was then introduced to install the covering screw onto the implant in a clock wise direction.

* Imaging Sciences International, Hatfield, Pa, USA.

** Blue Sky Bio, LLC

*** Invision Si2, USA.

****Micro 10, A.B. Pharma.

*****Ubestesin, 3M ESPE, Germany.

*****Augmentin 625mg Beecham, MUP.

***** Cleanlant, Dentis Implant Equipment, Korea.

*****Listerine mouthwash, USA.

*****Osstemm Dental Implant, Hiossen dental, Korea.

*****Betadine MW, El-Nil.

Effect Of Different Pick-Up Techniques On The Retention & Patient Satisfaction Of Implant-Supported Mandibular Overdenture With Locator Attachment

II.6. Post-Surgical Instructions

The patients were immediately given after surgery Diclofenac Sodium non-steroidal anti-inflammatory analgesic tablets (Voltaren 75mg) *. It was prescribed as one tablet three times daily for three days to reduce pain and swelling, and were advised to follow the antibiotic regimen previously prescribed (Augmentin 1g) for 5-7 days. Patients were given the following instructions:

- To apply ice packs for 10 minutes with 10 minutes intervals along a period of 3-4 hours immediately following surgery.
- To follow strict oral hygiene protocol.
- To avoid eating hard food for one month. (only soft diet)
- Not to wear the denture for 10 days, then asked for a recall appointment after 10 days to relive the fitting surface of the denture with application of soft liner.
- asked for a recall appointment after three months, to complete the restorative procedures.

II.7. Restorative procedures:

After three months, the patients were checked for maintaining the oral hygiene measures and then starting the restorative phase of treatment.

A post-operative Panoramic radiograph was made for the implant to ensure osseointegration.

- Infiltration anaesthesia was given at the surgical site & a probe was used to determine the exact position of the head of the implant guided by the surgical template (if the implant covered by gingival tissue).
- The universal hex driver was used to unscrew the covering screw of the implant. The gingival former was then introduced, fixed onto the implant using the universal hex driver. Then, left in the patient's mouth for ten days to obtain the normal gingival contour.
- Patients were then recalled, unscrewing the gingival former and measuring the trans-mucosal tissue height to choose the correct Locator Abutment height (should be 2 mm above the gingiva).
- Locator abutments were mounted in the internal hex of the implants using the insertion key tool, tightened by the torque rench (35 N torque). (*Fig. 2*)

At this stage, the patients were randomly divided (blind randomization) into two equal groups (ten patients/each), the first group (G.I) received their overdenture through Direct (chair-side) pick-up technique, while the second group (G.II) received their overdenture through indirect (laboratory) pick-up technique:

II.7.1. FIRST GROUP (CHAIR-SIDE PICK-UP TECHNIQUE) (*Fig. 3a, 3b, 3c*)

The fitting surface of the mandibular denture opposite to locator abutments was marked by the aid of an indelible pencil, the markings are then relived (deepened) and widened mesio-distally. In addition, two small holes were made in the lingual surface of the denture for easy escapement of excess acrylic resin material during the pick-up procedure.

The white locator blocking rings "white processing collars", which block the undercut, were stretched over the locator abutments followed by pressing the metal housings with the black processing nylon inserts directly over their corresponding abutments. The denture was checked for complete seating above the housings before completing the pick-up procedures. The denture was then dried & the relieved areas were slightly coated with acrylic resin monomer.

Mixing of sufficient amount of chemically-cured acrylic resin was then made, inserted in the relieved areas of the denture fitting surface & the denture was placed accurately in position to perform direct pick-up of the metal housings while the patient occluding in centric position (i.e. closed-mouth).

After setting of the acrylic resin, the denture was gently removed from the patient's mouth, checked that all metal housings were picked up into the fitting surface. Finishing & polishing of the denture was then applied, and the processing black nylon inserts were replaced by pink nylon inserts (of moderate retention values) by the aid of the insertion tool.

II.7.2. SECOND GROUP (LABORATORY PICK-UP TECHNIQUE) (*Fig. 4a,4b, 4c*)

Upper & lower alginate impression was made to obtain primary casts. Over the lower cast, a spacer is adapted and a custom-made acrylic resin tray was fabricated.

Metal transfer copings suitable for the used locator abutments were fitted on their corresponding abutments. The custom-made acrylic resin tray was painted by rubber base adhesive then loaded by heavy-body rubber base impression material. Meanwhile, A light-body rubber base impression material was injected around the locator abutment with their corresponding metal transfers. A one-step rubber base impression was taken.

*Voltaren, 75ml oral, NOVARTS, Egypt.

Effect Of Different Pick-Up Techniques On The Retention & Patient Satisfaction Of Implant-Supported Mandibular Overdenture With Locator Attachment

After setting, the impression was then removed from patient's mouth, checked for accuracy & presence of the metal transfers inside the impression. Abutment analogues were then accurately positioned into their corresponding metal copings. In the laboratory, the impression was poured utilizing extra-hard stone to obtain a cast that exhibited the locator abutment analogues over which the metal transfers were present. Upper & lower casts with their corresponding dentures are mounted on a semi-adjustable articulator* by the aid of a face-bow record & an inter-occlusal centric jaw relation record.

The white locator blocking rings (which block the undercut) were inserted over the locator abutments analogues, followed by inserting the metal housings with the black processing nylon inserts directly over their corresponding abutments. The fitting surface of the mandibular denture opposite to the abutments analogues was marked by the aid of an indelible pencil, the markings are then relived (deepened) and widened mesio-distally. In addition, two small holes were made in the lingual surface of the denture for easy escapement of excess acrylic resin material during the indirect pick-up procedure. The denture was checked for complete seating above the housings before completing the pick-up procedures. The denture was then dried & the relieved areas were slightly coated with acrylic resin monomer.

Mixing of sufficient amount of chemically-cured acrylic resin was then made, inserted in the relieved areas of the denture fitting surface & the denture was placed accurately in position to perform an indirect pick-up of the metal housings while the articulator was closed in centric position.

After setting of the acrylic resin, the denture was gently removed from the lower cast, checked that all metal housings were picked up into its fitting surface. Finishing & polishing of the denture was then applied, and the processing black nylon inserts were replaced by pink nylon inserts (of moderate retention values) by the aid of the insertion tool.

The denture was then delivered to the patient, checked for accuracy & complete non-endured seating. (**Fig. 5**)

II.7.3. For both groups

After denture insertion and training the patient on easy insertion & removal of the denture; patients were instructed to follow strict oral hygiene measures and asked for a recall appointment every single week in the first 4 weeks for any required denture adjustments &/or refinement of occlusion.

Retention of the implant-supported overdenture was measured by using a Digital Forcemeter; by the aid of (A Retention-Aided Measuring Device). For accurate reproducible measurement & ensuring equal distribution of the dislodging forces over the whole overdenture surface. Every patient was instructed to sit in the dental chair, so that the occlusal plane of the maxillary teeth was parallel to the floor. Patients were asked to fix their heads during the steps of examination.

The maximum force of vertical dislodgment in Newtons (N) was calculated; each measurement was repeated three times, and the mean of those measurements was utilized to represent the recorded retention value. Patients' satisfaction was also measured (the day following overdenture placement) utilizing a customized chart of question, where; Patients answered a series of questions to evaluate the overdenture in terms of: masticatory function, pain sensation, phonetics, esthetic behavior, psychological adaptation presence of any discomfort and finally, each patient had to give a number representing his General satisfaction (5= Excellent, 4= very good, 3= good, 2= fair, 1= working, 0= not satisfied) Regarding the previous questions.

- ❖ Patients of both groups were asked for recall appointments 3 months, 6 months and 12 months following overdenture insertion for measuring the retention values as well as assessment of the patients' satisfaction.
- ❖ *It is worth to clarify that the pink nylon inserts of the overdentures of all patients were replaced by new ones of the same color after 12 months of placement.*
- ❖ All the results were calculated, tabulated and then statistically analyzed.

*Bio. Art articulator 5000, Brazil

Effect Of Different Pick-Up Techniques On The Retention & Patient Satisfaction Of Implant-Supported Mandibular Overdenture With Locator Attachment

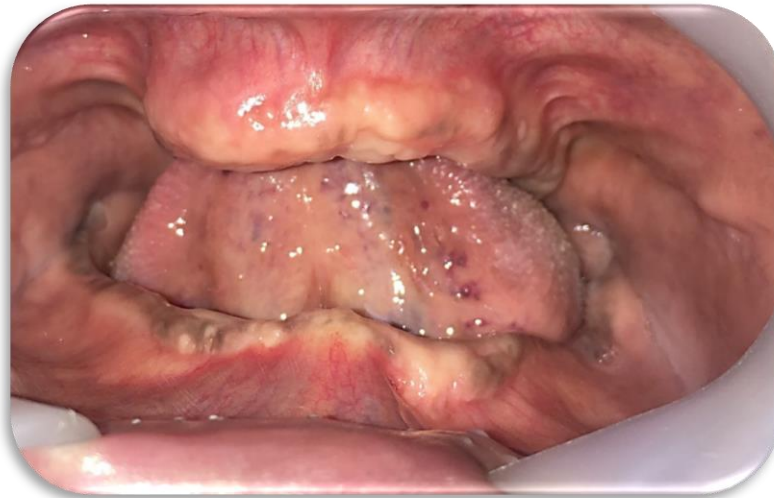

Fig. (1): A patient with completely edentulous arches (mandible & maxilla).

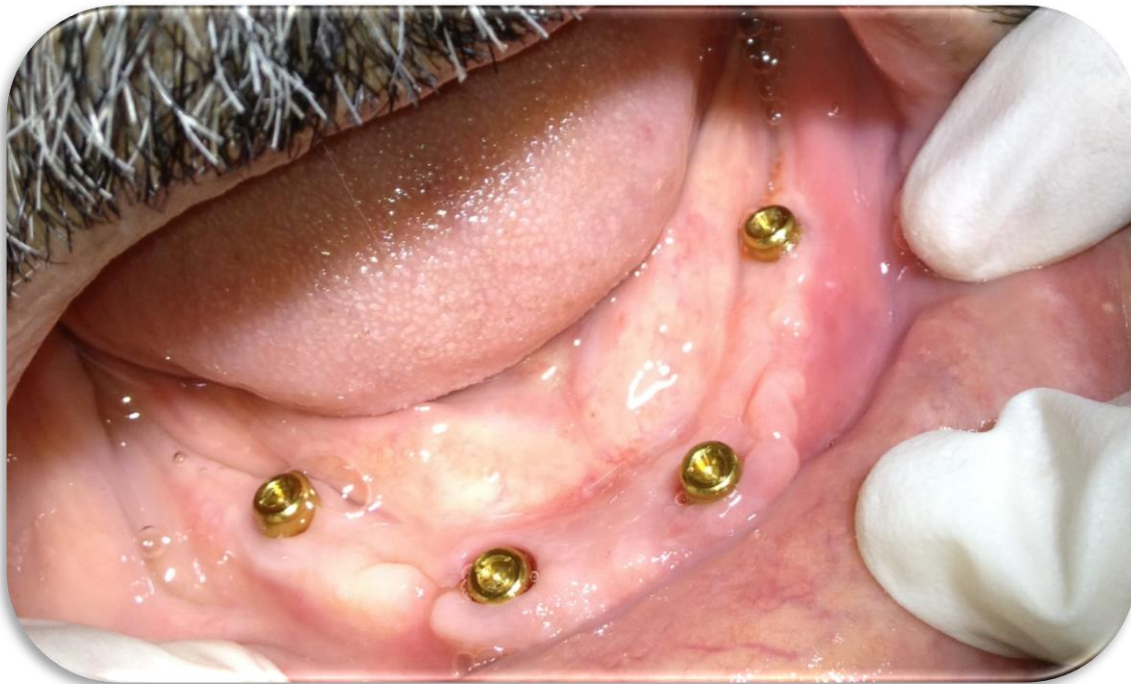

fig. (2): Locator abutments properly tightened onto corresponding implant fixtures.

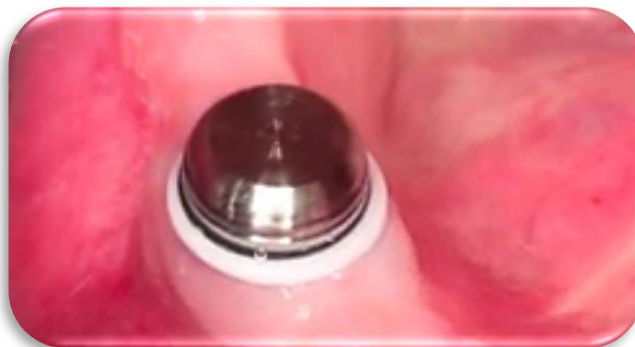

fig.(3a): white processing collars with its metal housings accurately fitted on it.

Effect Of Different Pick-Up Techniques On The Retention & Patient Satisfaction Of Implant-Supported Mandibular Overdenture With Locator Attachment

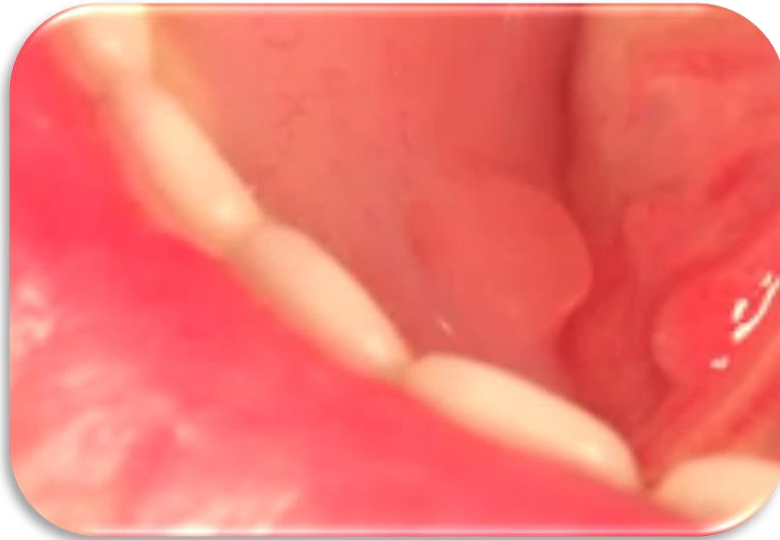

fig.(3b): Excess acrylic resin escaping from lingual holes in the overdenture.

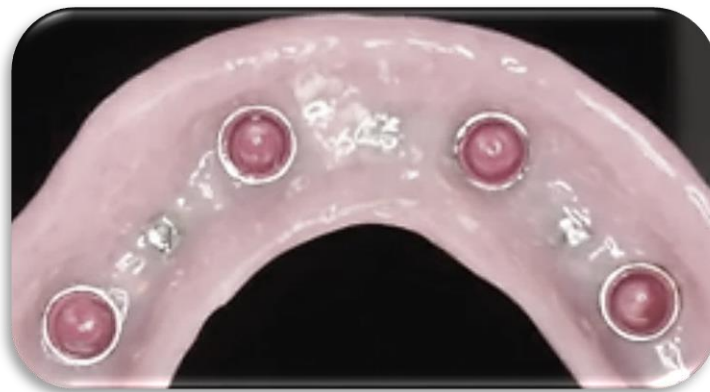

fig.(3c): Finished and polished overdenture containing the male patrices with pink retentive nylon inserts.

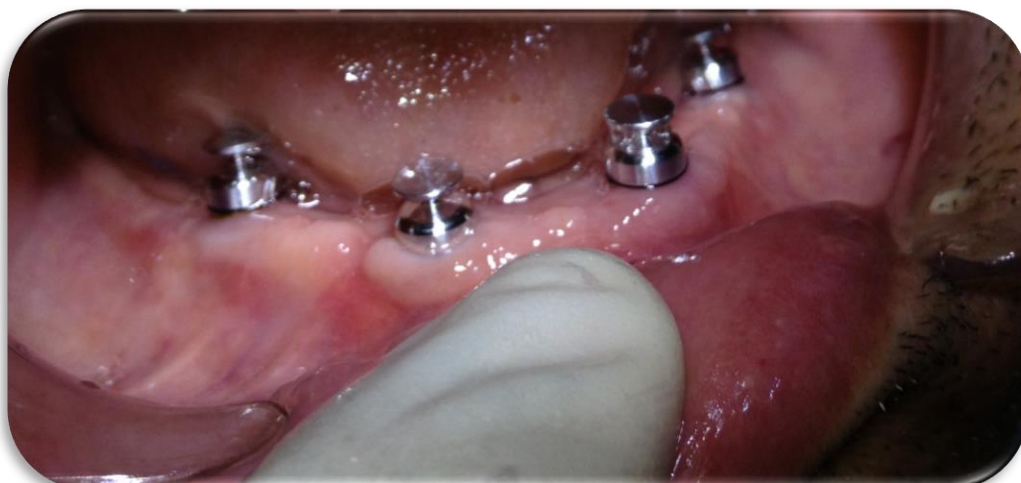

fig.(4a): Metal transfer copings suitable fitted on their corresponding abutments.

Effect Of Different Pick-Up Techniques On The Retention & Patient Satisfaction Of Implant-Supported Mandibular Overdenture With Locator Attachment



Fig.(4b): A one-step rubber base impression including the metal transfers.



fig.(4c): A stone cast showing; white processing collars with its metal housings accurately fitted on it.

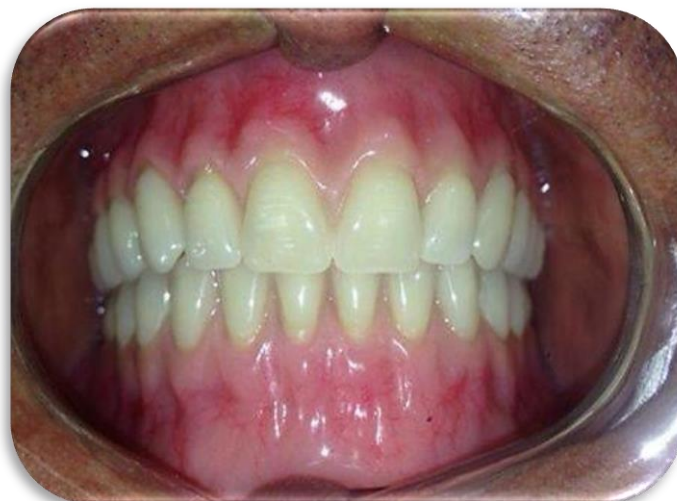

fig.(5): Finished & polished implant-supported overdenture accurately placed in patient's mouth.

II.8. Statistical analysis

Data were obtainable as means and standard deviation (SD) values.

II.8.1. Statistical tests

The data were stated as means \pm standard deviations and mean percentage changes.

Regarding parametric data; repeated measures ANOVA test was utilized to assess the changes by time inside each group as well as to compare between the two groups. Bonferroni's post-hoc test was performed for pair-wise comparisons when ANOVA test is significant.

Regarding non-parametric data; Mann-Whitney U test was introduced to compare between both groups.

II.8.2. Significance level

The significance level was established at $P \leq 0.05$. Statistical analysis was made with SPSS 20 (Statistical Package for Scientific Studies) for Windows.

III. Results

Numerical information was examined for normality by checking the distribution of information and using tests of normality (Kolmogorov-Smirnov and Shapiro-Wilk tests).

Retention data exhibited normal (parametric) distribution, while satisfaction scores were processed as non-normal (non-parametric) data.

For parametric data; repeated measures ANOVA test was used to assess the changes by time within each group as well as to compare between the two groups. Bonferroni's post-hoc test was performed for pair-wise comparisons when ANOVA test is significant.

For non-parametric data; Mann-Whitney U test was used to compare between the two groups.

The significance level was set at $P \leq 0.05$. Statistical analysis was performed with IBM® SPSS® Statistics Version 20 for Windows.

III.1. Retention (Forcemeter) measurement (*Fig. 6a*)- (*Table. I*)

Regarding the changes by time within each group; there was non- statistically significant decrease in mean retention values after 1, 3 as well as 6 months.

From 6 months to 12 months; there was a statistically significant decrease in mean retention values.

Comparison between the two groups revealed that (Group I) showed statistically significantly higher mean retention value than (Group II) after one month while there was no statistically significant difference between the two groups at time of overdenture insertion, after 3, 6 as well as 12 months.

® IBM Corporation, NY, USA.

® SPSS, Inc., an IBM Company.

Effect Of Different Pick-Up Techniques On The Retention & Patient Satisfaction Of Implant-Supported Mandibular Overdenture With Locator Attachment

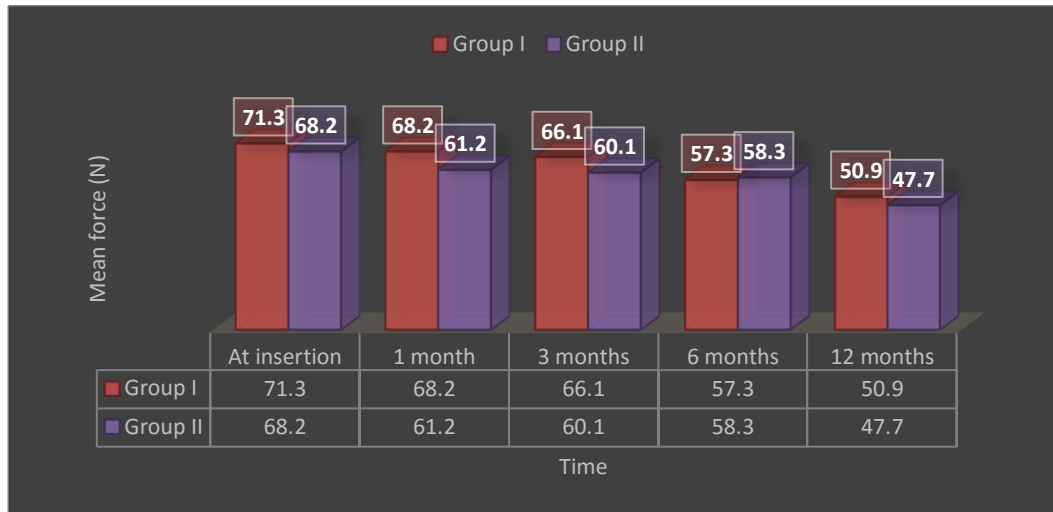


fig.(6a): A chart representing mean retention values in the two groups.

Table (I): The mean, standard deviation (SD) values and results of repeated measures ANOVA test for comparison between retention values in the two groups as well as changes by time within each group.

Time	Group I		Group II		P-value (Between groups)
	Mean	SD	Mean	SD	
At insertion	71.3 ^A	1.5	68.2 ^A	4.1	0.175
1 month	68.2 ^A	3.5	61.2 ^A	5.5	0.045*
3 months	66.1 ^A	5.7	60.1 ^A	4.7	0.097
6 months	57.3 ^A	4.2	58.3 ^A	3.3	0.841
12 months	50.9 ^B	3.3	47.7 ^B	6.7	0.719
P-value (Within group)	<0.001*		<0.001*		

*: Significant at $P \leq 0.05$, Different superscripts in the same column are statistically significantly different.

III.2. Patient satisfaction (**Fig. 6b**)- (**Table. II**)

Comparison between the two groups revealed that there was no statistically significant difference between satisfaction questionnaire scores in the two groups.

Effect Of Different Pick-Up Techniques On The Retention & Patient Satisfaction Of Implant-Supported Mandibular Overdenture With Locator Attachment

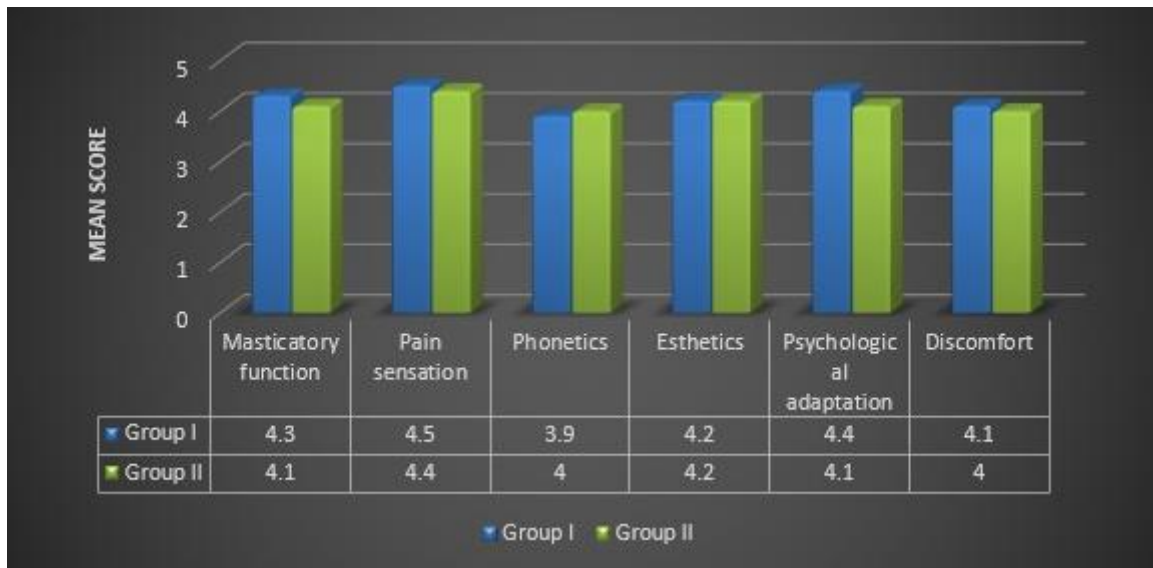


fig.(6b): A chart representing mean satisfaction scores in the two groups.

Table (II): The mean, standard deviation (SD) values and results of Mann-Whitney U test for comparison between patient satisfaction scores in the two groups.

Item	Group I		Group II		P-value
	Mean	SD	Mean	SD	
Masticatory function	4.3	1.1	4.1	0.9	0.793
Pain sensation	4.5	1.5	4.4	1.5	0.912
Phonetics	3.9	1.3	4.0	0.9	0.877
Esthetics	4.2	1.2	4.2	1.0	0.962
Psychological adaptation	4.4	1.6	4.1	1.5	0.569
Discomfort	4.1	1.6	4.0	1.1	0.846

*: Significant at $P \leq 0.05$

IV. Discussion

IV.1. Discussion of Methodology

In this study, all factors that could affect the osseointegration of implants were carefully considered during patient selection and later after restoration. These factors may be biological or mechanical or both; The biological factors could be related to the patient's selection, to the steps of implant installation and to the level of oral hygiene measures followed. [18]

Twenty fully edentulous, healthy patients of age ranging from 45-60 years old were included in this study to avoid any fluctuation in bone changes that might affect the obtained results.

Effect Of Different Pick-Up Techniques On The Retention & Patient Satisfaction Of Implant-Supported Mandibular Overdenture With Locator Attachment

Maintenance of good oral hygiene has a great influence on the success of this study to the extent that it has a great impact on the osseointegration process. The oral hygiene of each patient was, therefore, evaluated at the beginning of the study and then throughout the whole investigation period.

Patients exhibited adequate inter-arch space, to ensure adequate room for all the overdenture components without encroachment on the normal vertical dimension of occlusion.

Patients with superior general health were only selected, to avoid the reflection of any systemic disorder on the bone condition, and hence, osseointegration. [19]

Only cases with normal maxilla-mandibular relation were included in the study to avoid the effect of transmission of abnormal forces to the implants. [20]

Heavy smokers were excluded as smoking is considered as an important factor in early implant failure due to anoxia of the oral cavity together with significant increase in plaque formation and calculus deposits, as recommended by several authors. [21]

Uncooperative patients were excluded, where only cooperative patients were included in the study to ensure their commitment to the oral hygiene measures and the regular follow up visit.

Bone quality and quantity were evaluated radiographically to ensure primary stability of the implant at the time of its placement. In addition, patients with sufficient bucco-lingual width at sites of implants placement were only selected to ensure at least one mm. thickness of bone remaining buccal and lingual to the implant after its placement. [22]

Tentative jaw relations have been made to the patients to ensure an adequate inter-arch space. Moreover, it helped in determination of ridge relationship where patients only with Angle class I were included in the study to facilitate implant insertion and avoid implants overloading. [23].

Construction of a computer-guided surgical stent was carried out, to ensure accuracy of implant placement in the three dimensions as well as decreasing the human interfering factors that might affect the adjustment of implants angulation. [24]

The difference in diameter between the drills and the drill guide prevented friction between the drill and the sleeve and allowed for penetration of the irrigation with the up and down motion of the drill.

For infection control during and after implant installation, pre-and post-surgical antibiotics and chlorohexidine mouth wash were prescribed.

All implants used were threaded, self-tapping, root form implants, 10 mm length and 4 mm width. This implant design was used to ensure primary stability during the initial healing period, as well as, increasing the contact area between the implant and the surrounding bone for better osseointegration. [25]

Panoramic radiograph was the imaging modality of choice in evaluating implants osseointegration, to avoid the metallic artifacts that accompany CBCT (due to presence of multiple implants). [26]

A rubber base impression material was utilized to ensure accurate recording of fine details, and hence, obtaining an accurate restoration. [27]

Varnishing the impression surfaces surrounding the analogues with Vaseline was carried out to facilitate impression removal from the stone cast and ensuring that the implant analogues remain embedded into the stone cast.

The covering screws are placed onto the implants to avoid entrance of contaminants or food accumulation between the visits.

The Retention-Aided Measuring Device was utilized to ensure adequate distribution of vertical dislodging forces (exerted by the digital Forcemeter) on the whole overdenture surface; hence, reliable measurements of retention could be gained.

The cases were followed up for one year to ensure proper evaluation of retention and patient satisfaction throughout a suitable period of time.

IV.2. Discussion of Results

Oral rehabilitation with implant-supported overdentures in completely edentulous mandibles offers a wide range of treatment modalities not only based on the varying number of implants utilized, but also relied on the variety of different retentive options provided. [28]

The management of a completely edentulous mandible using four osseointegrated implants to support a mandibular overdenture with locator attachments is an accepted treatment modality. However, a controversy exists about the most suitable pick-up technique to be used for such situations. [29-31]

During the recall periods of all patients, there were no complaints from the installed implant and all the patients followed the oral hygiene instructions to avoid any harmful effect which might influence the results of this study. [32]

The position of the posterior implants in the second premolar regions, was preferred over their placement mesial to the mental foramen; because, this position increased the length of antero-posterior spread (A-P distance) and hence, better load distribution. [33, 34]

Effect Of Different Pick-Up Techniques On The Retention & Patient Satisfaction Of Implant-Supported Mandibular Overdenture With Locator Attachment

Several studies reported that, the patients' quality of life had been improved by the increased retention and stability of their implant-assisted overdentures. [35]

Both groups exhibited reduced retention values over the whole study period, which might be attributed to wear of the retentive nylon inserts. But, it was found that; after 6 months of clinical use, the range of retention values of locator attachments was still within the accepted range of required retention. [36-38]

The significance difference in retention values occurred between the two groups after one month of overdenture insertion might be attributed to more rapid physiological adaptation of muscles surrounding the overdenture of group one than in group two. [39]

The presence of saliva and constant occlusal loading might have an additional advantage on the amount of wear occurred in the locator nylon inserts.

The significant decrease in retention of the overdentures in all patients after 12 months of clinical use, dictated replacement of the wearied pink nylon inserts with new ones utilizing the insertion tool. [40]

The non-statistically significant difference in patients' satisfaction between the two groups throughout the whole study period, showed that whatever the utilized pick-up technique is, would not affect the efficiency of the used overdenture. [3]

The results of the present clinical investigation confirmed the null hypothesis previously established.

V. Conclusion

This study was performed to evaluate the impact of using two different pick-up techniques on the retention measurements besides patient's satisfaction for an implant-assisted mandibular overdenture.

- Twenty patients were carefully chosen from the outpatient clinic of the prosthodontic department, Faculty of Dentistry, Cairo University, with edentulous arches. Patients were similarly divided into two equivalent groups; First group, had completed the procedures of constructing Implant-supported overdenture with locator attachment using *Direct pick-up technique (chair-side technique)*, while Second group had completed the procedures of fabricating Implant-supported overdenture with locator attachment using *Indirect pick-up technique (Laboratory-assisted pick-up technique)*.

-Retention of the Implant-supported overdentures was measured Five times (at time of insertion, one month, three months, six months and one year respectively), utilizing A Digital Forcemeter device. In addition, patients' satisfaction was also measured utilizing a customized chart of question (A five-point scale).

- A statistically non-significant difference in retention values between the two groups was observed throughout the whole study period.

- A statistically non-significant difference in patient's satisfaction was observed in all patients.

V.1. From the results of this study, the following conclusions could be achieved

- ❖ locator attachments are highly recommended to retain mandibular overdentures, as they exhibited high retention values with minimal loss of retention.
- ❖ Both pick-up techniques utilized, presented a workable treatment option for non-rigid splinting of four implant-supported mandibular overdentures; therefore, decision for selecting one of the two techniques will be relied on the preference of the dental clinician.
- ❖ The Forcemeter measurements were accurate & favorable for measuring retention of the removable implant-supported mandibular overdentures.
- ❖ Patients were completely satisfied with their implant-supported overdentures, whatever the pick-up technique utilized.

Conflict of Interest

This clinical study was self-funded by the author, with no conflict of interest.

Effect Of Different Pick-Up Techniques On The Retention & Patient Satisfaction Of Implant-Supported Mandibular Overdenture With Locator Attachment

References

- [1] Akoglu, B., Ucankale, M., Ozkan, Y. & Kulak-Ozkan, Y.: Five-year treatment outcomes with three brands of implants supporting mandibular overdentures. *Intern. J. of Oral and Maxillof. Impl.* 26, 2011, 188–194.
- [2] Andreiotelli, M., Att, W. & Strub, J.R.: Prosthodontic complications with implant overdentures; A systematic literature review. *I. J. of Prosthodont.* 23, 2010, 195–203.
- [3] Awad M.A., Locker D., Korner-Bitensky N. & Feine J.S.: Measuring the effect of intra-oral implant rehabilitation on health-related quality of life in a randomized controlled clinical trial. *J. of Dent. Res.* 79, 2000, 1659–63.
- [4] Boerrigter E.M., Geertman M.E., Van Oort R.P., Bouma J., Raghoebar G.M., van Waas M.A. et al.: Patient satisfaction with implant-retained mandibular overdentures; A comparison with new complete dentures not retained by implants—a multicenter randomized clinical trial. *British J. of Oral and Maxillof. Surg.* 33, 1995, 282–288.
- [5] Cehreli M.C., Uysal S. & Akca K.: Marginal bone level changes and prosthetic maintenance of mandibular overdentures supported by 2 implants; A 5-year randomized clinical trial. *Clin. Impl. Dent. and Related Res.* 12, 2010, 114–121.
- [6] Cooper L.F., Moriarty J.D., Guckes A.D., Klee L.B. Smith, R.G. Almgren C. & Felton D.A.: (2008) Five-year prospective evaluation of mandibular overdentures retained by two micro-threaded, tioblast non-splinted implants and retentive ball anchors. *Intern. J. of Oral and Maxillof. Impl.* 23, 2008, 696–704.
- [7] Davis D.M. & Packer M.E.: Mandibular overdentures stabilized by Astra tech implants with either ball attachments or magnets; 5-year results. *Intern. J. of Prosthodont.* 1999; 12: 222–229.
- [8] Eccellente T., Piombino M., Piattelli A., Perrotti V. & Iezzi G.A.: new treatment concept for immediate loading of implants inserted in the edentulous mandible. *Quint. Intern.* 41, 2010, 489–495.
- [9] Nguyen CT, Masri R, Driscoll CF, Romberg E.: The effect of denture cleansing solutions on the retention of pink Locator attachments; an in vitro study. *J. Prosth.* 19, 2010, 226–230.
- [10] Ellis, J.S., Burawi, G., Walls, A. & Thomason, J.M.: Patient satisfaction with two designs of implant supported removable overdentures; ball attachment and magnets. *Clin. Oral Impl. Res.* 20, 2009, 1293–1298.
- [11] Esfandiari S., Lund J.P., Penrod J.R., Savard A., Thomason J.M. & Feine, J.S.: Implant overdentures for edentulous elders; Study of patient preference. *Gerodont.* 26, 2009, 3–10.
- [12] Gjengedal H., Berg E., Gronningsaeter A.G., Dahl L., Malde M.K., Boe O.E. et al.: The influence of relining or implant retaining existing mandibular dentures on health-related quality of life; A 2-year randomized study of dissatisfied edentulous patients. *I. J. of Prosth.* 26, 2013, 68–78.
- [13] Heckmann S.M., Winter W., Meyer M., Weber H.P. & Wichmann M.G.: Overdenture attachment selection and the loading of implant and denture-bearing area. Part 2; A methodical study using five types of attachment. *Clin. Oral Impl. Res.* 12, 2001, 640–647.
- [14] Heydecke G., Thomason J.M., Lund J.P. & Feine J.S.: The impact of conventional and implant supported prostheses on social and sexual activities in edentulous adults results from a randomized trial 2 month after treatment. *J. of Dent.* 33, 2005, 649–657.
- [15] van Kampen F., Cune M., van der Bilt A. & Bosman F.: Retention and postinsertion maintenance of bar-clip, ball and magnet attachments in mandibular implant overdenture treatment; An in vivo comparison after 3 months of function. *Clin. Oral Impl. Res.* 14, 2003, 720–726.
- [16] Karabuda C., Yaltirik M. & Bayraktar M.: A clinical comparison of prosthetic complications of implant-supported overdentures with different attachment systems. *Impl. Dent.* 17, 2008, 74–81.
- [17] Kohal R. J., Straub L. M., Wolkewitz M., B€achle M. & Patzelt S. B.: Evaluation of guided bone regeneration around oral implants over different healing times using two different bovine bone materials; A randomized, controlled clinical and histological investigation. *Clin. Impl. Dent. and Rel. Res.* 17, 2015, 957–971.
- [18] Krennmaier G., Seemann R., Weinlander M. & Piehslinger E.: Comparison of ball and telescopic crown attachments in implant-retained mandibular overdentures; A 5-year prospective study. *Intern. J. of Oral and Maxillof. Impl.* 26, 2011, 598–606.
- [19] Misch CE.: *Dental Implant Prosthetics.* St Louis; Elsevier Mosby 2005; pp. 211-230.
- [20] May D. & Romanos G.: Immediate implant-supported mandibular overdentures retained by conical crowns; A new treatment concept. *Quint. Intern.* 33, 2002, 5–12.
- [21] Sayardoust S., Gr€ondahl K., Johansson E., Thomsen P. and Slotte C.: Implant Survival and Marginal Bone Loss at Turned and Oxidized Implants in Periodontitis-Susceptible Smokers and Never-Smokers; A Retrospective, Clinical, Radiographic Case-Control Study. *J. Period.* 7, 2013, 33-41.
- [22] Misch CE. and Scortecchi GM.: Immediate load and restoration in implant dentistry; Rationale and Treatment. *Contem. Impl. Dent., St Louis: Elsevier Mosby* 35, 2008, 799-838.
- [23] Flanagan D., Iliis H., Lasko B. and Stack J.: Force and movement of non-osseointegrated implants: an in vitro study. *J. Oral Impl.* 35 (6), 2009, 270-276.
- [24] Schropp L., Stavropoulos A., Gotfredsen E. and Wenzel A.: Comparison of panoramic and conventional cross-sectional tomography for preoperative selection of implant size. *Clin. Oral Impl. Res.* 22 (4), 2011, 424-429.
- [25] Degidi M. and Piattelli A.: A 7-year follow-up of 93 immediately loaded titanium dental implants. *J. Oral Impl.* 7, 2005, 25-31.
- [26] Rebele SF., Zuhr O. and Hurzeler MB.: Pre-extractive Inter-Radicular Implant Bed Preparation: Case Presentations of a Novel Approach to Immediate Implant Placement at Multirooted Molar Sites. *Int. J. Period. Rest. Dent.* 33 (1), 2013, 89-96.
- [27] McGrath C., Lam O. & Lang N.: An evidence-based review of patient-reported outcome measures in dental implant research among dentate subjects. *J. of Clin. Period.* 39(Suppl 12), 2012, 193–201.
- [28] Awad MA, Lund JP, Dufresne E, Feine JS.: Comparing the efficacy of mandibular implant-retained overdentures and conventional dentures among middle-aged edentulous patients; satisfaction and functional assessment. *Int. J. Prosth.* 16, 2003, 117–122.
- [29] van der Bilt A, van Kampen FM & Cune MS.: Masticatory function with mandibular implant-supported overdentures fitted with different attachment types. *Eur. J. Oral Sci.* 114, 2006, 191–196.
- [30] Heckmann SM, Winter W, Meyer M, Weber HP, Wichmann MG.: Overdenture attachment selection and the loading of implant and denture-bearing area. Part 2; A methodical study using five types of attachment. *Clin. Oral Impl. Res.* 12, 2001, 640–647.
- [31] Trakas T, Michalakakis K, Kang K, Hirayama H.: Attachment systems for implant retained overdentures; A literature review. *Impl. Dent.* 15, 2006, 24–34.
- [32] Alsabeeha NH, Payne AG, Swain MV.: Attachment systems for mandibular two-implant overdentures; A review of in vitro investigations on retention and wear features. *Int. J. Prosth.* 22, 2009, 429–440.

Effect Of Different Pick-Up Techniques On The Retention & Patient Satisfaction Of Implant-Supported Mandibular Overdenture With Locator Attachment

- [33] Meijer H.J., Raghoobar G.M. & Van't Hof M.A.: Comparison of implant-retained mandibular overdentures and conventional complete dentures; A 10-year prospective study of clinical aspects and patient satisfaction. *Intern. J. of Oral and Maxillof. Impl.* 18, 2003, 879–885.
- [34] Meijer H.J., Raghoobar G.M., Van't Hof M.A. & Visser A.: A controlled clinical trial of implant-retained mandibular overdentures; 10 years' results of clinical aspects and aftercare of imz implants and Branemark implants. *Clin. Oral Impl. Res.* 15, 2004, 421–427.
- [35] Naert I., Alsaadi G., van Steenberghe D. & Quirynen M.: A 10-year randomized clinical trial on the influence of splinted and unsplinted oral implants retaining mandibular overdentures; Peri-implant outcome. *Intern. J. of Oral and Maxillof. Impl.* 19, 2004, 695–702.
- [36] Passia N., Wolfart S. & Kern M.: Six-year clinical outcome of single implant-retained mandibular overdentures – a pilot study. *Clin. Oral Impl. Res.* 26, 2015, 1191–1194.
- [37] Payne, A.G. & Solomons, Y.F.: Mandibular implant-supported overdentures; A prospective evaluation of the burden of prosthodontic maintenance with 3 different attachment systems. *Intern. J. of Prosth.* 13, 2000, 246–253.
- [38] Stoumpis, C. & Kohal, R.J.: To splint or not to splint oral implants in the implant-supported overdenture therapy? A systematic literature review. *J. of Oral Rehab.* 38, 2011, 857–869.
- [39] Zhang R.G., Hannak W.B., Roggensack M. & Freesmeyer W.B.: Retentive characteristics of ankylos syncone conical crown system over long-term use in vitro. *Eur. J. of Prosth. and Rest. Dent.* 16, 2008, 61–66.

Mostafa Helmy . "Effect Of Different Pick-Up Techniques On The Retention & Patient Satisfaction Of Implant-Supported Mandibular Overdenture With Locator Attachment." *IOSR Journal of Dental and Medical Sciences (IOSR-JDMS)* 16.9 (2017): 09-22