

## **Faciomaxillary injuries Associated with Craniocerebral Trauma in Present Scenario of Kashmir (A Govt. Medical College Srinagar Kashmir Experience)**

\*<sup>1</sup>Nahida Dar, Humam Nisar

Nahida Dar MDS Oral and Maxillofacial Surgery, Humam Nisar, MCH  
Neurosurgery

<sup>1</sup>Oral and maxillofacial surgeon, Senior Resident Neurosurgery

<sup>2</sup>Lecturer in neurosurgery Govt medical college Srinagar,

Corresponding Author: \*Nahida Dar

**Abstract:** Sixty five patients were admitted in the department of Neurosurgery Govt. Medical College Srinagar Kashmir for last one and half year, who had facial maxillary injuries associated with craniocerebral trauma. This department has been newly introduced in Govt Medical College Srinagar and has been functional for last four years. Study was carried out to analyse the association of faciomaxillary injuries in brain injury patients due to craniocerebral trauma. After initial resuscitation patients were subjected to computerized Tomographic scanning and 3D scanning of face. Patients with low G.C. Shadpoor outcome associated faciomaxillary injuries added to morbidity and mortality. Associated injuries were seen more in males. A total of 80% cases were found in the age group of 16-35 years. Majority of patients were victims of modern day vehicular trauma, though victims of violence of present day conflict in Kashmir were no less. Violence was either due to stone pelting or firearms.

**Keywords:-** Faciomaxillary injuries, Craniocerebral trauma, Computerized Tomography, Violence of Conflict, Vehicular trauma.

Date of Submission: 20-06-2017

Date of acceptance: 30-09-2017

### **I. Introduction**

With the urbanisation and increased modern day vehicular traffic the incidence of faciomaxillary injuries associated with craniocerebral trauma has increased manifold. In our centre of Govt. Medical College, Srinagar inflow of patients has tremendously increased as this centre is the primary centre close to the city and the department is newly introduced and has been operational for last four years. Increased incidences has been found due to vehicular accidents and the violence in conflicting zone. This violence has taken new turn for last few years. Stone pelting and firearms have been found main causes in this conflict. We did find faciomaxillary injuries alone but associated craniocerebral trauma has taken a lead. The impact of trauma whether it was due to violence in conflicting zone or vehicular accidents was really severe. In spite of early resuscitation and availability of modern day investigations like CT Scan and 3D Scans of face mortality and morbidity was more beyond doubt. Faciomaxillary injuries associated with craniocerebral trauma remain a most challenging subject in any neurosurgical centre. In spite of proximity of facial region to skull there is definitely paucity of literature regarding same.

### **Methodology**

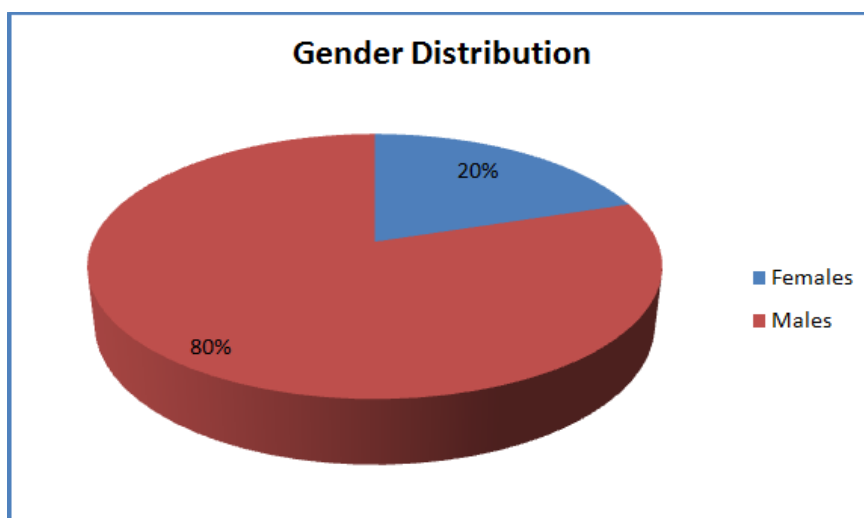
This study was conducted at Neurosurgery centre of Govt Medical College Srinagar for last one and a half year. Sixty five cases of facial trauma were seen associated with craniocerebral trauma. Cause of injury and information on sex and age were taken into account. Patients were examined for facial injuries using 3D face. Out of 65 cases 52 were males and 13 were females. A total of 80% cases were between age group of 16 to 35 years, 12% cases were between age group of 35 to 40 years and 8% cases were above 51 years age. Majority of these cases were due to vehicular accidents but cases like stone pelting and fire arms used in present day conflict were no behind. Patients were resuscitated in emergency department. Comatose patients were intubated and large bore intravenous lines were placed. Resuscitation continued according to advance life trauma guidelines. Every effort was made to recover and maintain stable vital signs. Patients were evaluated by G.C.S score and investigations including Haemogram, Coagulogram, Serum chemistry and blood gas analysis. Patients were evaluated with G.C.S score and subjected to radiography C.T Scan of head and face. Face was included in associated injuries of Craniocerebral trauma. 3D C T Scan of face which captures organ bones and vessels in quick span of time Surgical debridement of wounds was done necrotic tissue removed and hematoma

and contused brain presenting as mass lesion were removed, bullet track was followed to its site, proper haemostasis was achieved and Dural and scalp closure were done. Postoperative patients were nursed in Intensive Care Unit. Patients were treated by antibiotics, anti convulsants and decongestive therapy. Repeated postoperative check scans were done within first week and at the time of discharge. In all patients stitches were removed on tenth day.

**II. Result**

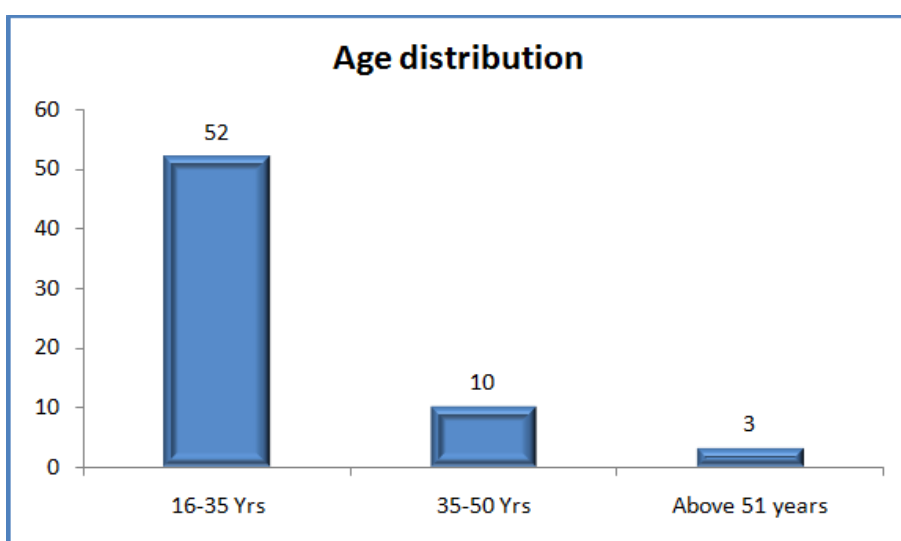
A total of sixty five patients were included in study. The gender distribution is shown in the table below.

Gender	No. of Patients	Percentage
Females	13	20%
Males	52	80%
<b>Total</b>	<b>65</b>	<b>100%</b>



There were 52 males and 13 females.

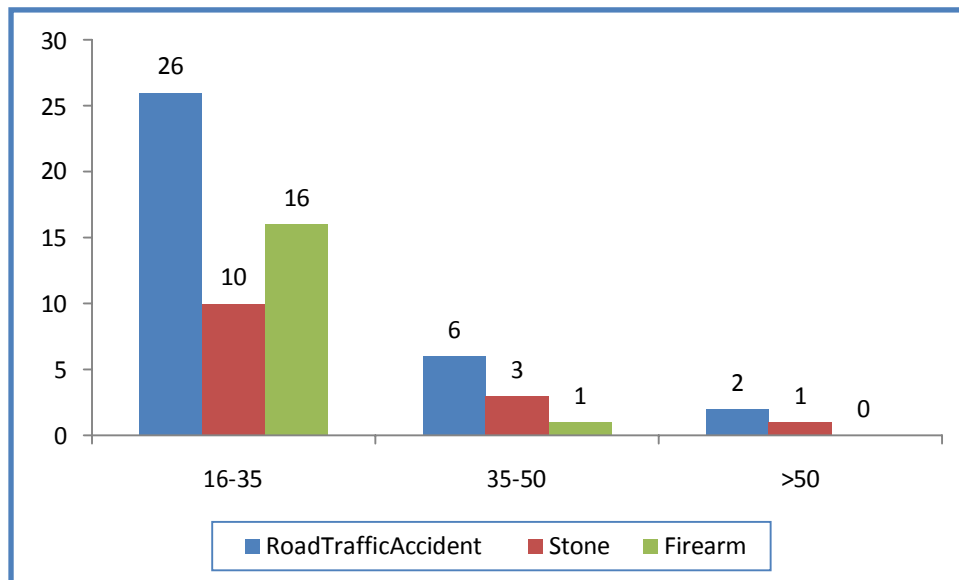
Age in Years	No. of Patients	Percentage
16-35	52	80%
35-50	10	12%
Above 51 years	03	08%



A total of 80% cases were between 16-35 years, 12% were between 35-50 years of age and 8% cases above 51 years

**Table-3: Cause of Injury**

Age Group (Years)	Road Traffic Accident	Stone	Firearm
16-35	26(50.00)	10(19.23)	16(30.77)
35-50	6(60.00)	3(30.00)	1(10.00)
>50	2(66.66)	1(33.33)	0
Total	34(52.30)	14(21.54)	17(26.15)



Cause of Faciomaxillary injuries associated with craniocerebral injuries. Road traffic accidents score over injuries by stones and firearms

### III. Discussion

Head injury causes hospitalization of large population in hospitals worldwide. A head injury associated with facial trauma comprises a number of complications such as Sinusitis, Nasolacrimal duct injury, Facial deformity and injury to globe and Squelstrum formation. Facial trauma can be dangerous as this could impact essential parts like Respiration, Speech, Vision or smell. Major or minor facial injuries have often been reported in severely injured patients where head injury component was also dominant. In the literature incidence of these facial injuries associated with head trauma range between 14 to 22%.<sup>1,2,4,5,7</sup>

However due to differences in study population socioeconomic status and geographic location comparative studies can differ. Even time of study can influence the data however our study was done continuously over a period of One and a half year. Our study mainly focused on association of faciomaxillary injuries with Craniocerebral Trauma.<sup>1,6,8</sup> Our study besides association of faciomaxillary injury with head trauma focused on age group and type of trauma and gender distribution. Our data revealed sixty five patients of facial and maxillary injuries with associated head injury. Out of sixty five patients fifty two were males and thirteen were females. Incidence of 80% was reported in males. Young males predominantly affected. Common age group in our study was 16 to 35 years which framed 50% of total patients reported in our data. These observations were reported in other studies also. Thirty five years ago Van Hoof reported 19-21 years most vulnerable age group. Similar observations were reported by Goodisson<sup>1</sup> and Khan AA<sup>4</sup> and Motumedi MH<sup>5</sup> and Yasir SR<sup>6</sup>. Incidence in age group of 35-50 and above 51 years were 10% and 3%. Our study also focused on various causes of these injuries. Road traffic accidents remained highest cause in our study. Incidence was 50% in age group 16-35 and 60% in 35-50 years and 90% above 51 years. Similar observations were reported by Hashim H, Iqbal S.<sup>2</sup> Study was conducted in Malaysia. A Nigerian study conducted at teaching Hospital found road traffic accidents as common cause of injuries. Use of three dimensional CT scan has been observed by Saigal K and Wino Kour R.S<sup>5</sup>.

Use of 3D Scan and subsequent treatment of faciomaxillary injuries has been studied retrospectively by Aksoye and Unlue Sansozo<sup>8</sup>. Another retrospective study of injuries to maxillofacial skeleton was carried out in Harare Zimbabwe<sup>3</sup>. Due to relatively small patient collection we did not analyze statistical relation between maxillofacial and Intracranial injuries. Due to high incidence of maxillofacial injuries with brain injuries it is justifiable to assume potential brain injuries with any kind of facial trauma until proved otherwise. It is important to maintain high level of suspicion for cranial injuries in all patients of maxillofacial trauma even with those where there are no obvious signs and symptoms of brain injury.

In our zone of conflict stones and firearms were two other cause of severe faciomaxillary injuries associated with craniocerebral trauma. Our study found incidence of 30% by firearms in age group of 16-35 and 8% in 35-50. Stone were another cause of severe injuries and incidence as high as 20% was seen in age group of 16-35 and 32% in 35-50 years. Due to high level of force in stone injuries and firearm injuries orbital and maxillary fractures were common. In complex trauma due to firearm and stones Lefort III fracture and maxillary fractures were predominant. In associated cranial injuries frontal sinuses fractures were commonly seen. Such observations have been reported by various studies as conducted by Montumedia MH<sup>5</sup> and Yasir SH<sup>6</sup> and Ramkin M<sup>9</sup>. Three dimensional CT Scan played a vital role in detecting facial injuries

To come to conclusion our study besides age group and type of trauma revealed severe face injuries are associated with high rates of concomitant injuries like cranial injuries. This association underlines the importance of diagnostic workup in all severe facial trauma, so that no injury is overlooked. We did find the importance of close collaboration of maxillofacial and Neurosurgeon. Immediate intervention for maxillofacial injury were Tracheostomy and Intubation. In haemodynamically unstable patients, nasal packing and direct compression were of great importance. In our study maxillofacial injuries mostly required operative intervention but emergency surgery was not required.

#### **IV. Conclusion**

This study concluded prevalence of head injuries highest in the age group of 16-35 years with males scoring over females. Vehicular trauma and stones and firearms were keen as leading causes.

#### **References**

- [1]. Goodisson, D Macfurlane M. Snape L, Darwish B. Head injuries and associated maxillofacial injuries. NZ Med J 2004 Sept; 117: 1201 [2]. Hashmi H, Iqbal S. Motorcycle Accidents main cause of maxillofacial injuries in the penungmarilarid Malaysia, Dent Traumatol 2011 Feb; 27(1): 19-22.
- [3]. Medubul ZE, Chukwuco, Omokeni Oyakhilome OP, OZOC. Road traffic accidents seen in a Nigerian teaching hospital ENT. Orthop 2011 May; 35(5): 743-6.
- [4]. Khan AA. A Retrospective study of injuries to maxillofacial skeleton in Harare Zimbabwe Br. J. Oral Maxillofac Surg 1988 Oct; 26(5): 435-439
- [5]. Daigal K, Einokour R. S, Findin S, Taub D, Pribitkin E. Use of three dimensional computerized tomography reconstruction in complex facial trauma (Facial Plast Surg 2005 Aug; 21(3): 214-220.
- [6]. Montumedi M. H. An Assessment of maxillofacial fractures. A 5 year study of 237 patients. J Oral Maxillofac Surg. 2003 Jan; 61(1): 61-64.
- [7]. Yasir SH. Facial trauma among patients with head injuries. J of IMAB 2014 Oct-Dec; 20(6): 535-538.
- [8]. Aksoy, Unlue Senoz O. A retrospective study of Epidemiology and treatment of faciomaxillary fractures. J Cranio Surg 2002 Nov; 13(6): 7672-5.
- [9]. Biros MH, Heegard WG. Head injury int. RURXYA, Hochberger R. S Walls R M, itulleds. Rosens Emergency Medicine. Concept and clinical practice 7<sup>th</sup> Edition St. Louis M D Mostry 2009; Chap 38.
- [10]. Ramkin M, Bonah GL. Perceived functional impact of abnormal facial appearance. Plast Reconstr Surg. 2003 June; 117(7): 2140-6.

\*Nahida Dar. "Faciomaxillary injuries Associated with Craniocerebral Trauma in Present Scenario of Kashmir (A Govt. Medical College Srinagar Kashmir Experience)." IOSR Journal of Dental and Medical Sciences (IOSR-JDMS) 16.9 (2017): 60-63