

Atypical Manifestation of Dengue: Clinical Profile and Outcome in a Tertiary Care Hospital of Eastern India

^{*1}Dr Sarbani Misra, MD . ²Sumantra Sarkar, MD.
³Arpan Saha, MD PGT

¹Assistant Professor. Department of Pediatrics, Institute of Post Graduate Medical Education and Research, 244 Acharya Jagadish Chandra Bose Road, Kolkata- 700020. India. Email: misra.sarbani@gmail.com

²Associate Professor. Department of Pediatrics, Institute of Post Graduate Medical Education and Research, 244 Acharya Jagadish Chandra Bose Road, Kolkata - 700020. India. Email: sumantra.com@gmail.com.

³Final Year Student. Department of Pediatrics, Institute of Post Graduate Medical Education and Research, 244 Acharya Jagadish Chandra Bose Road, Kolkata - 700020. India. Email: dr.arpan.saha@gmail.com

*Corresponding Author: Sarbani Misra

Abstract

Background and Objective: Dengue, a mosquito –borne arboviral illness, may present with many atypical manifestations.

Methods: Children (0-12 years of age) admitted into Pediatric Intensive care unit of a tertiary care hospital Kolkata, between the 1st August 2016 to 30th November 2016, diagnosed and confirmed as dengue fever following revised a WHO guideline, were reviewed retrospectively. Atypical manifestations were noted and analyzed.

Results: Atypical manifestations were found in 61.11% of cases. Those were increased level of hepatic transaminases (22.22.%), acute respiratory distress syndrome (5.56%), pulmonary hemorrhage (16.67%), acalculus cholecystitis (16.67%), acute pancreatitis(5.56%), acute renal failure (5.56%), myocarditis (5.56%), intracranial hemorrhage (5.56%) and cerebral demyelination (5.56%). Overall survival was 77.78%.

Conclusions: Atypical manifestations in dengue, though rare, could be present along with the classical manifestations. A high index of suspicion and vigilance can lead to an early and prompt diagnosis and appropriate management for the life threatening disease.

Keywords: dengue, severe dengue, tertiary health care

Date of Submission: 28 -08-2017

Date of acceptance: 09-09-2017

I. Introduction

Dengue fever (DF) is transmitted by Aedes (Stegomyia) mosquitoes .Dengue virus belongs to family Flaviviradae and has four serotypes namely, DEN-1, DEN-2, DEN-3, DEN-4 [1]. Peoples residing in tropical and subtropical countries are at risk .Dengue virus infection has a varied clinical spectrum ranging from asymptomatic infection to undifferentiated febrile illness ,classical DF , dengue hemorrhagic fever (DHF) , dengue shock syndrome (DSS) , and expanded dengue syndrome/Isolated organopathy, also knows as unusual manifestations [1]. The unusual manifestations are seen in patients with DHF with prolonged shock / organ failure as well as in patients with coinfections or comorbidities. According to the disease severity, WHO has classified dengue as: probable dengue, dengue with warning signs and severe dengue characterized by severe plasma leakage/severe bleeding/ severe organ involvement [2]. A large proportion peoples with DHF (approximately 90%) are children aged less than five years with about 2.5% mortality in them [1].

With increase in epidemics of dengue [1] ,atypical manifestations are also on the rise [3], which might be underreported due to lack of awareness .Knowledge of atypical manifestations of dengue is essential to carry out their appropriate management .

II. Materials And Methods

This retrospective study was carried out at the Pediatric Intensive care unit(PICU) of Institute of Post Graduate Medical Education & Research (IPGME&R),Kolkata, between the 1st August 2016 to 30th November 2016. All the consecutive cases (0-12 years of age),admitted to PICU in whom diagnosis of dengue was confirmed by enzyme linked immunoabsorbent (ELISA) based dengue antigen detection test (NS1 antigen)

and antibody detection test- immunoglobulin (Ig) M capture ELISA (MAC- ELISA) were included in the study. A detailed history, physical examination and investigations undertaken and daily assessment during hospital stay and outcome were analyzed through a retrospective review of records. Atypical neurological, gastrointestinal, respiratory, cardiovascular, renal, hematologic manifestations in dengue fever were recorded and analyzed.

III. Results

Out of the 18 patients documented with dengue NS1 antigen ELISA positivity and MAC ELISA confirmed anti Dengue—IgM seropositivity , atypical manifestations were found in 11 of them (n=11;61.11%). Most common atypical manifestation seen with gastrointestinal system (n=8;44.44%) . Increased hepatic transaminase levels were seen in 4 cases (n=4;22.22%) (cases 6,7,8,12). Aspartate transaminase(ALT) was greater than the enzyme alanine transaminase (ALT) in 3 cases(7,8,12) and was > 500 u/L.; in case 7 ALT was 1980 u/L, and ALT was 1184 u/L . ALT was greater than AST (1711 u/L ALT vs 500 u/L AST) in case 6 in our study. Acalculous cholecystitis was seen with 3 cases (cases 5,8,17) (n=3;16.67%) , all of them also had ascites and right sided pleural effusion .Acute pancreatitis was documented in a patient(case 18) associated with severe dengue (n=1;5.56%).

Neurological atypical manifestations were documented in 3 patients(n=3;16.67%)(cases 2,7,9) : Single episode of generalized tonic- clonic seizure associated with fever were found in 2 cases (cases 7,9) (n=2;11.11%) and encephalopathy in 1case (n=1; 5.56%) (case2). Computed tomography (CT) scan of brain done on 7th day from onset of fever revealed evidence of intracranial hemorrhage in case 9. Magnetic resonance imaging (MRI) scan of brain done on 10th day from onset of fever onset in case 2 showed areas of hyperintensities in brain stem, bilateral cerebellum,thalamus, and posterior periventricular white matter with restricted diffusion in thalamus , suggestive of acute disseminated encephalomyelitis (ADEM). Co-infection with Japanese encephalitis (JE) was associated in case 2 : her serum IgM for JE was positive and cerebrospinal fluid (CSF) anti JE Ig M antibody was negative. Neuroimaging in case 7 in our study was normal. Atypical respiratory manifestations were seen in 3 patients(n=3;16.67%) (cases 3,4,7) . Acute respiratory distress syndrome (ARDS) was associated in 1 patient(case 3) (n=1; 5.56%) . Pulmonary hemorrhage (PH) complicated the outcome in all those 3 patient(n=3; 16.67 %). Multiorgan involvement with acute renal failure(ARF), myocarditis, and hepatitis was seen with case 6 (n=1;5.56 %). Echocardiography revealed mitral and tricuspid regurgitation during the acute stage, while his follow up echocardiographic study was normal. Hemodialysis was required for his ARF component on 7th day of admission.

Infection associated hemophagocytic lymphohistiocytosis (HLH) was seen in 2 cases (case1,3) (n=2; 11.11%). Disseminated intravascular coagulation(DIC) was associated in 2 cases (cases4,7). Most interesting and novel findings seen in case 1 of our study , who was associated also with Kawasaki disease (KD).Clinical findings of KD started appearing after 7 days of onset of dengue fever. In view of the progressive clinical manifestations fulfilling the clinical criteria for diagnosis of KD, intravenous immunoglobulin (IVIG) was given . Echocardiographic finding was also supportive for the diagnosis of KD. Rapid reversal of mucosal manifestations was noted after IVIG administration, but skin peeling on hand and feet was persisting over 2 weeks.The other patient also received IVIG in our study was case 2 on view of her clinical, CSF and MRI findings suggestive of ADEM. She also responded well with reversal of encephalopathy. Overall survival in our study was 77.78 %(n=14).There were 4 deaths (n=4;22.22%) (cases 3,4,7,13) from severe dengue . Cause of death in case 3 was IAHS,ARDS and PH ; in case 4 was DIC and PH ; in case 7 was hepatitis, DIC and PH. In case 13 cause of death was refractory shock from massive plasma leakage. Cases 4 and 7 were 5 months and 2 months old infants , case 3 and 13 were 2 years and 6 year old girls respectively.

IV. Discussion

Unusual manifestations are increasingly reported in recent years in patients with DHF as well as in patients with DF who do not have evidence of plasma leakage [1].These manifestations may be associated with complications of prolonged shock, co-infections or co-morbidities. Many a time they are underreported, unrecognized or not related to dengue [1]. Blood vessels and platelets are the two main end organs involved in dengue [4] . The hallmark of the disease is increased vascular permeability and coagulopathy [5]. An increase in activated partial thromboplastin time(aPTT), reduction in fibrinogen and thrombocytopenia are the components of coagulopathy [5]. A functional change in vascular integrity mediated by various cytokines results in increased vascular permeability with plasma leakage and hemoconcentration [4,5]. These mechanisms can explain the system involvements in atypical manifestations [3]. Any patient presenting with pain abdomen in dengue endemic areas should be investigated for dengue related illness [3]. Atypical gastrointestinal /hepatic manifestations in our study are: hepatitis , acalculous cholecystitis and acute pancreatitis. None of the patients with hepatitis appeared icteric . Transaminitis can be seen in 30% of patient in dengue epidemic [4]. A greater

elevation of AST than ALT in dengue may be explained by release of AST from damaged monocyte and this is useful in differential diagnosis of acute hepatitis in dengue endemic areas [3]. Fatal DHF associated with severe liver damage can be due to direct infection of hepatocytes and Kupffer cells [4]. Pathogenesis of acalculous cholecystitis is not known. The possible causes might be prolonged fasting, infection, endotoxemia, microangiopathy and ischemia [3]. It usually resolves spontaneously with supportive care in majority of cases, excepting in some isolated cases with gangrene/perforation of gall bladder with peritonitis, which needs surgical intervention [6]. The patients with acalculous cholecystitis in our study presented with nonspecific pain abdomen and abdominal distension. Ultrasonography(USG) abdomen in these patients revealed gall bladder mucosal edema and pericholecystitic fluid without any gallstones. The course of the disease was self limited and gall bladder wall thickness returned to normal in all of them. Acute pancreatitis is another rare complication of dengue fever. Involvement of pancreas might be due to direct viral invasion of pancreas or it might be due to hypotension in DHF [3]. The course of the patient with pancreatitis in our study was self limited with symptomatic management.

One atypical neurological manifestation in our study were generalized tonic clonic seizure on first day of fever in 9th patient of this series mimicking febrile convulsion. In the other patient- 7th case of this series who was 2-month old infant, tonic attack with uprolling of eyes occurred on 4th day of fever. In another patient (case 2) encephalopathy was evident on 7th day from onset of fever. Varied neurological manifestation in dengue are related to (i) neurotrophic effect of the virus (ii) due to systemic complications during infection (cytokine mediated capillary hemorrhage, DIC, hepatic failure, electrolyte disorder, severe dehydration/shock, renal failure) and (iii) postinfectious [4,7]. Postinfectious immune mediated myelitis usually occurs 1-2 weeks after disease onset whereas parainfectious myelitis can occur within 1st week. Some cases of ADEM have been reported in the convalescence of dengue [7], though abnormalities in MRI of brain usually occurs after 7 days of onset of fever. Acute lung injury (ALI)/ acute respiratory distress syndrome (ARDS) usually occurs secondary to increased alveolar-capillary membrane permeability leading to interstitial and alveolar edema which leads to pulmonary dysfunction. Dengue virus antigen can be found in alveolar lining cells of the lung [3,8]. Management of patients of DSS with fluid is critical in this situation because extra fluid infusion after adequate volume replacement can lead to volume overload and may aggravate ALI/ARDS [6]. DSS is a leading cause of ARDS in dengue endemic area [3] with a high mortality rate [8]. This complication necessitates early recognition and appropriate fluid management. Pulmonary hemorrhage is another fatal complication that can be also seen in these patients [3,6]. All 3 patients in our study with pulmonary complications died.

Myocarditis in dengue is due to infection of myotubules by the virus leading to alteration of intracellular calcium ion and expression of inflammatory genes [4]. The 6th patient in our study had palpitations, persisting tachycardia, and hypotension; electrocardiography (ECG) showed T wave inversion, 2D echocardiogram showed mitral and tricuspid regurgitation. Patient improved with supportive management which included vasoactive drug and inodilator (milrinone). This child also suffered from pre-renal variety acute kidney injury and single hemodialysis hastened his recovery. This child also had liver injury. In spite of his multiorgan involvement we could save his life.

HLH was associated in 2 cases in our study (cases 1,3). In this clinical syndrome the uncontrolled and nonmalignant proliferation of T-lymphocytes and macrophages leads to a cytokine storm [9]. In both the cases there was progressive pancytopenia, increased ferritin and triglyceride along with persistent fever and progressive splenohepatomegaly. With supportive therapy could save the life of case 1 who also had Kawasaki disease as mentioned earlier, but we could not able to save the life of case 3 in our study. Survival rate was 77.78% (n=14) in our study. Main line of management in our study was supportive care with fluid resuscitation, intubation and ventilation as and when required, FFP transfusion for DIC, platelet transfusion in severe thrombocytopenia, correction of metabolic derangements. Major causes of death in our study were PH (cases 4,7), HLH and ARDS (case 3), and refractory shock (case 13). Risk factors in our study were low platelet count <15000 and infancy/lower age group. Severe plasma leakage with shock (DSS) (n=8; 44.44%) was managed successfully in most cases except in 13th patient in our study, who had massive plasma leakage and refractory shock. More than half (61.11%) of the patients in the present study had one or more atypical manifestations. Similar atypical presentation were found in 2 other Indian studies with the incidence around 40% and 50% [6,8]. However small sample size is a limitation in our study.

V. Conclusion

Atypical manifestations in dengue are not rare and could be present along with the classical manifestations. It is imperative for treating physicians as well as surgeons to be aware of these deceiving presentations of dengue infection. A high index of suspicion and vigilance can lead to an early and prompt diagnosis and appropriate management.

References

[1]. World Health Organization, Regional Office for South-East Asia. Comprehensive Guidelines for Prevention and Control of Dengue and Dengue Haemorrhagic Fever. Revised and expanded edition. WHO-SEARO 2011. (SEARO Technical Publication Series No. 60)

[2]. Handbook for Clinical Management of Dengue. World Health Organization 2012

[3]. Gulati S, Maheshwari A. Atypical manifestations of dengue. Tropical medicine & international health: TM & IH. 2007;12(9):1087–95.

[4]. Kadam DB, Salvi S, Chandanwale A. Expanded Dengue. J Assoc Physicians India. 2016 Jul;64(7):59- 63 .

[5]. National guidelines for clinical management of dengue fever.Ministry of health. National Vector borne disease control programme.

[6]. Nimmagadda SS, Mahabala C, Bolor A, Raghuram PM, Nayak U. A. Atypical Manifestations of Dengue Fever (DF) – Where Do We Stand Today? . J Clin Diagn Res. 2014; 8: 71–73. Published online 2014 Jan12. doi: 10.7860/JCDR/2014/6885.3960

[7]. Pal S, Sen K, Biswas NM, Ghosal A, Rousan Jaman SK, Yashavantha Kumar KY. Clinico-radiological profile and outcome of dengue patients with central nervous system manifestations: A case series in an Eastern India tertiary care hospital . J Neurosci Rural Pract. 2016;7:114-24. doi: 10.4103/0976-3147.165410

[8]. PawariaA, Mishra D, Juneja M, Meena J. Atypical manifestations of dengue fever. Indian Pediatr 2014;51:495-6

[9]. Wan Jamaludin WF, Periyasamy P, Wan Mat WR, Abdul Wahid SF.Dengue infection associated hemophagocytic syndrome: Therapeutic interventions and outcome..J Clin Virol. 2015;69:91-5. doi: 10.1016/j.jcv.2015.06.004. Epub 2015 Jun 15

Legends

- [10]. **Fig 1** Frequency of atypical clinical manifestations of dengue in our study.
- [11]. **Fig 2.** Magnetic resonance imaging of brain showing hyperintensity in bilateral thalamus, posterior periventricular white matter ,left central semiovale.

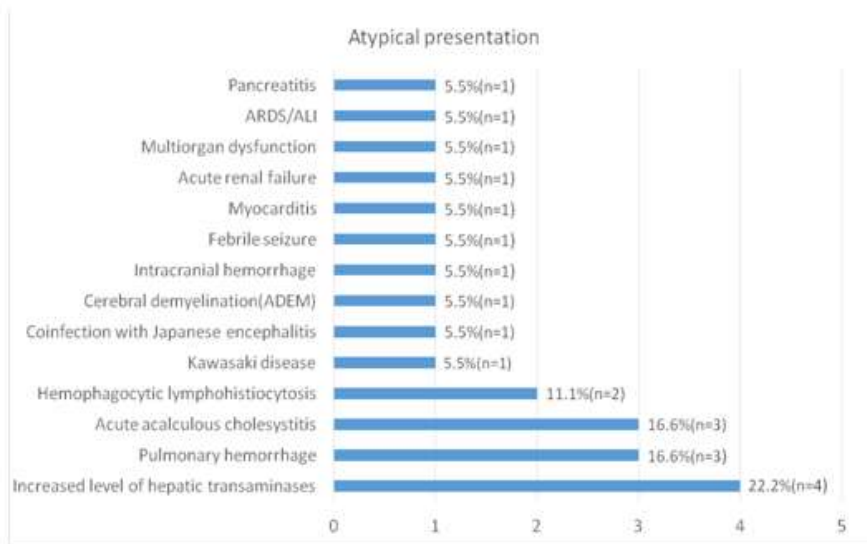


Fig 1

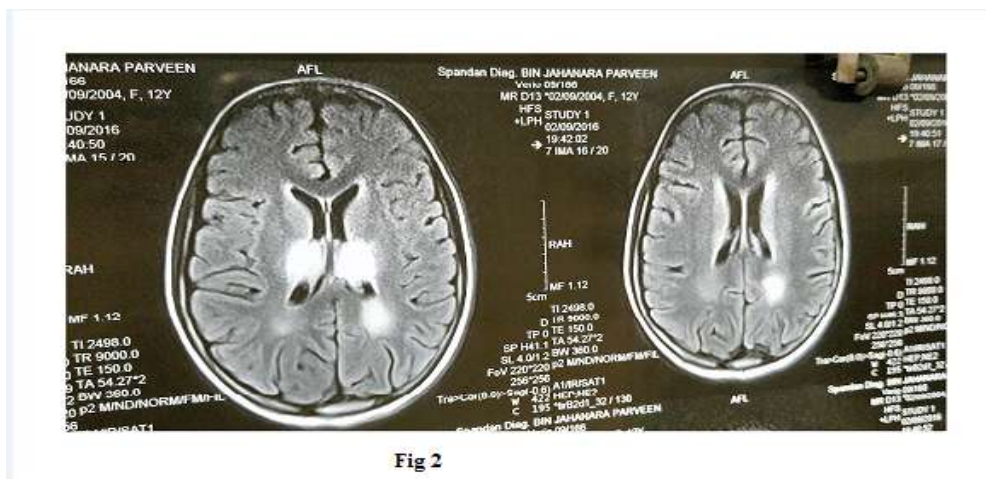


Fig 2

*Sarvani Misra (Roy). "Atypical Manifestation of Dengue: Clinical Profile and Outcome in a Tertiary Care Hospital of Eastern India." IOSR Journal of Dental and Medical Sciences (IOSR-JDMS) 16.9 (2017): 34-37