

Management of Infected Non Union Distal third Tibia With Single Stage Ilizarov Method.

¹Dr. Cherukuri Nagesh, ²Dr. Raja Ramesh Badavath, ³Dr PA Shravan Kumar

¹Additional Professor, Department of Orthopaedics, Nizams Institute of Medical Sciences, Hyderabad

²Assistant Professor, Department of Orthopaedics, Nizams Institute of Medical Sciences, Hyderabad

Corresponding Author: Dr Raja Ramesh,

Abstract: The fractures of the distal third of the tibia and fibula are critical for treatments due to its subcutaneous position and minimal muscle cover which contributes to the complexity. Severe damage to the soft tissue indicates high risk of delayed bone union and results in contamination and a wide range of wound complications such as non-union, infection and necrosis. To achieve union with eradication of infection is an orthopaedic challenge. We have retrospectively reviewed cases of infected nonunion of distal third tibia managed by single stage debridement and Ilizarov method and analysed. A retrospective study of 16 adults (age 15-65 years) admitted to the orthopaedic department at Nizams Institute of Medical Sciences (NIMS), Hyderabad and with infected non union distal tibia was completed between July'2013 and July'2016. The patients were followed up for an average period of 15 months. The bone and functional results evaluated using ASAMI protocol revealed that bone union and eradication of infection was achieved in 15 out of 16 cases studied. In one patient arthrodesis was seen due to severe bone loss. However pinsite infection and pain was the most common observation. Infected distal third non union tibia can be managed in single stage provided good care while elevating skin flaps is taken. This procedure shortens the rehabilitation protocol and follow-up can be minimised.

Date of Submission: 22 -08-2017

Date of acceptance: 09-09-2017

I. Manuscript

Introduction:

The distal third of the tibia is located adjacent to the talocrural articulation, which is crucial in the kinematics of walking. The fractures or the lesions at this part of the bone are undoubtedly critical for the treatment, as it is subjected to important mechanical stress and several other reasons [1]. When this bone is affected by infection, amputation was the only valid therapeutic choice before 1970. Later, the development of more effective chemotherapy drugs and therapy schemes improved the survival percentage remarkably. In the current scenario, the surgical treatments are now focused on the attempt of preserving the limb (2). Furthermore it is very important to consider the restoration of the skeletal and soft tissue in continuity which is an extremely challenging process. However the post - surgical procedures are accompanied by several other issues which needs to be addressed. Few of them includes failure of union, contamination and persistent infection at the site of fracture for 6 to 8 months, compromised soft tissues, poor bone quality, devitalisation of bone fragments, bone loss due to extensive surgical exposure. In addition one may have to address certain challenges such as blood supply (bone per se maybe relatively avascular), predominant tendon base which may involve in closure difficulties and may need to raise thick flap cover with periosteum for closure. Management of Infected non union in such scenario is a challenge. Although alternative staged procedures are successful, they are expensive, time taking and most importantly needs prolonged immobilisation of the limb. An alternative, cheaper, single staged reliable procedure that allows patient to bear weight post surgery in the form of Ilizarov ring fixator in treating infected non union of tibia is evaluated in the present study.

II. Materials And Methods

Sixteen patients (both male and female) in the age group between 18 and 65 years (Average 26.2 years) operated with single staged ilizarov fixation for distal tibia non union between July'2013 and July'2016 were included in the study group to analyse the results retrospectively. Pre-operative evaluation with plain radiographs of leg, both anteroposterior and lateral views were done. Culture and sensitivity from discharging sinus taken to isolate the organism and antibiotic it is sensitive to. Location of Sinus tracts, previous scars, degree of deformity and limb length discrepancy, Knee range and Neurovascular condition were documented.

Surgical Technique: Lazy ‘S’ shaped incision, Judicious thick Cuticuloperiosteal flap on either side of Non union site, this facilitates closure after docking the bone. All loose implants (if any) were removed. Adequate debridement, Sequestrectomy and Necrectomy. Bone ends are freshened, Medullary canal was restored by reaming the canal. Cortical bleeding, called paprika sign, was accepted as an indication of vital tissue. Achieve best possible contact between them, bone to bone contact maximized by docking the spike if present, Oblique osteotomy done for fibula for docking

Ilizarov Fixation: Under image intensifier control, 2 wires of 1.8mm in diameter were inserted 2 to 5 cm above and below the pre-selected site respectively. Another 2 wires of 1.8mm in diameter were inserted as parallel and close to the joint as possible. All these wires were inserted in the same plane and perpendicular to the long axis of the tibia. Pre constructed sterile Ilizarov frame was applied at proximal and distal construct by ring with three multiplanar and remaining two rings with two biplanar ilizarov wires. Foot arch is made in cases with small distal fragment. Skin closure was done with Ethibond sutures.

Post Surgical Procedures: Post operation procedure the patient’s limb was elevated, with a crepe support and in prone position, so that wound healing would be better. Patient was made to ambulate on 2nd post operative day. Shoe raise for correction of limb length discrepancy. Full weight bearing was encouraged to promote the bone healing. Serial radiographs were performed to check for bony union. Dynamization of frame and removal of frame with PTB cast for 4 weeks after achieving satisfactory union. Outcome of union and functional results were evaluated by ASAMI scoring method as described in Table.1.

Scoring	Bone Results	Functional results
Excellent.	Bone union present, No Infection, Deformity < 7 ^o . LLD < 2.5 cms	Ability to Perform previous ADL, No Pain or Mild Pain, No Limp, No soft tissue sympathetic dystrophy knee or ankle contracture <5 ^o Loss of Ankle or Knee Motion <15 ^o
Good	Bone union present, failure to meet one of other criteria	Almost all ADL with minimal difficulty, No pain or mild pain, failure to meet one of the other criteria
Fair	Bone union present, failure to meet two of other criteria	Most ADL with minimal difficulty No pain or mild pain, failure to meet two of the other criteria
Poor	Nonunion or refracture, failure to meet three of the other criteria.	Significantly limited ADL, Significant Pain requiring narcotics, failure to meet three of the other criteria

Table 1. Evaluation of union and functional results.

III. Results

On an average 70 % of the cases were in active infected state with sinus. The mean amount of bone defect was 3.5 cm (range 1.0-7.8 cm) and the mean leg-length discrepancy was 4.4 cm (range 0 to 8.7 cm). Of 18 legs treated 16 were right limbs and 2 were left limbs. Complaints: 10 patients have complained about pain and discharge, 4 patients for pain, 1 patient for deformity and 1 for LLD. Fracture Patterns of all the cases were assessed and found that 7 were segmental, 5 were segmental and with deformity and the rest were segmental with deformity and shortening of the limb. The bone and functional results assessed using the ASAMI scoring method revealed that 12 patients showed excellent, 4 showed good and 1 showed fair bone recovery, where as 3 patients showed excellent, 10 patients indicated good, 4 poor functional results as per ASAMI scoring method. However treatment was failed in one patient with respect to both bone and functional recovery (Fig. 1). The patients were followed upto 15 months on an average. The mean frame keeping period was 6.3 Months [4.5-14 Months]. All the fractures were united where the bony union and eradication of infection was achieved in 15 patients. Arthrodesis in one patient was observed due to severe bone loss. The most common problem observed in all the cases was pin-site infection. Further the bony union was confirmed with the radiological procedures.

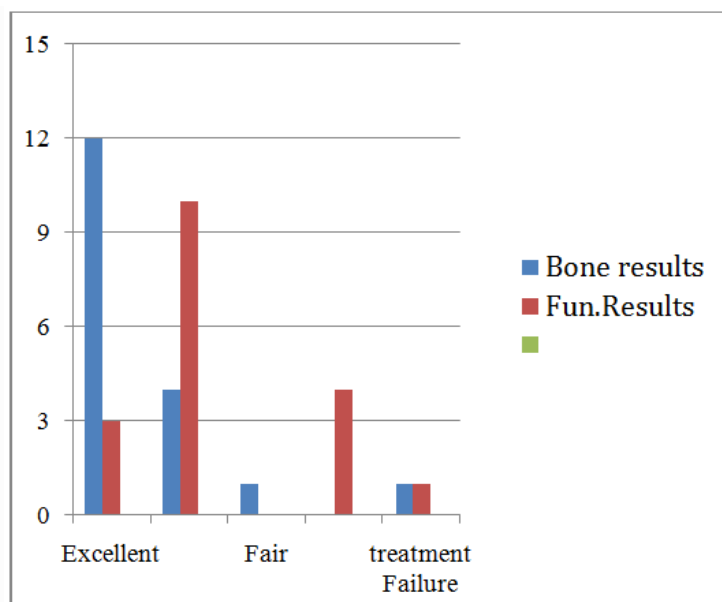
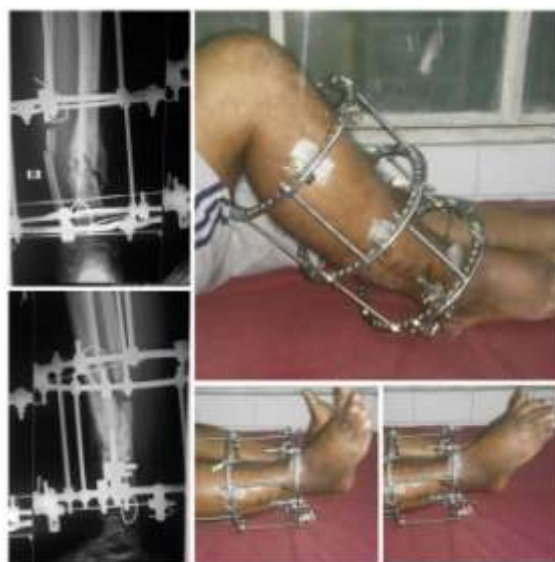

Fig.1: Bone and Functional Results- ASAMI Protocol.

Pin site infections were the most common complications noted in the study group. In 3 Patients, pain was the most common complaint, followed by watery discharge from pin sites that eventually led to superficial abscess requiring drainage. 3 patients have angulations with shortening which was corrected by distraction and compression. 5 patients developed ankle stiffness which was later improved after physiotherapy. 2 patients required an additional procedure in the form of bone grafting at the non union site for union to complete. 2 patients required a plastic surgery procedure in the form of flap cover. Fig 2 : A case of non union tibia lower third treated with Ilizarov fixation.



IV. Discussion

Post-traumatic tibial infection, nonunion is one of the most challenging orthopaedic problems. Liu et al. 2012 reported 35 cases of infected non-union treated with immediate granulated cancellous bone grafting after debridement [3]. We have followed a similar strategy to address the non-union observed in 2 patients. Autologous cancellous bone grafts were effective for small defects, but when the defect is massive it is not effective. Vascular bone grafting has been proven useful in overcoming massive bone defects. Tu et al. 2001 analyzed their clinical results in 48 patients treated with free vascularized bone graft reconstruction for bone defects. 41% (20/48) of their patients had an active osteomyelitis, with the follow-up average of upto 6 years. The functional outcome was good in 43 patients [4].

Healing and remodelling of bone grafts are lengthy processes with osteopenia and joint stiffness being the common complication which may incur due to prolonged remodelling. This grafting technique in addition is associated with other major complications such as refracture and host-graft junction healing. Cierny and Karen, in 1994 reported the comparison of the results of treating segmental tibial defects using Ilizarov bone transport and massive autologous bone graft and found that the results with Ilizarov method were much accomplishing than the results obtain in autologous bone grafting method [5]. Furthermore, if the patients have limb-length discrepancy, they might not be corrected with conventional bone grafting but bone transport. Complete cure of the infection is the mainstay of treatment in infected non-unions. Radical removal of the necrotic and infected parts of both bone and soft tissues represents the important element for the success of treatment by compression-distraction technique. Dendrinios et al. in 1996 treated defects of the tibia in 24 patients using the Ilizarov bone transport method and compression at the docking site for bone union to freshen both bone ends. Infection burns in the heat of inflammation of distraction [6].

Pin site infections were the most common complication that we faced as it is with most of the other studies [7]. The higher incidence of PTI in our study may be due to lower socio-economic and educational level of our patients and as such insufficient pin site care. It leads to loosening of wires and instability of the frame. Pain caused by a loose inflamed wire is an important reason for non-weight bearing and the very purpose of ring fixation is compromised. A proper technique of wire insertion and meticulous post-operative pin site care is very important. Two wire sites developed local abscesses and needed incision drainage. We did not encounter any ring sequestrum.

References

- [1]. Zeytoonjian T, Mankin HJ, Gebhardt MC, Hornicek FJ (2004) Distal lower extremity sarcomas: frequency of occurrence and patient survival rate. *Foot Ankle Int.* 25(5):325-330.
- [2]. Eilber FR, Eckhardt J, Morton DL (1984) Advances in the treatment of sarcomas of the extremity: current status of limb salvage. *Cancer* 54 (Suppl 11):2695-2701.
- [3]. Liu T, Yu X, Zhang X, Li Z, Zeng W (2012) One-stage management of post-traumatic tibial infected nonunion using bone transport after debridement. *Turk J Med Sci.* 42(6):1111-1120.
- [4]. Tu YK, Yen CY, Yeh WL, Wang IC, Wang KC, Ueng WN (2001) Reconstruction of posttraumatic long bone defect with free vascularized bone graft: good outcome in 48 patients with 6 years' follow-up. *Acta Orthop Scand.* 72(4):359-364.
- [5]. Cierny G 3rd, Zorn KE (1996) Segmental tibial defects. Comparing conventional and Ilizarov methodologies. *Clin Orthop Relat Res.* 301:118-123.
- [6]. Dendrinios GK, Kontos S, Katsenis D, Dalas A (1996) Treatment of high-energy tibial plateau fractures by the Ilizarov circular fixator. *J Bone Joint Surg Br.* 78(5):710-717.
- [7]. Green SA, Jackson JM, Wall DM et al. (1992) Management of segmental defects by the Ilizarov intercalary bone transport method. *Clin Orthop Relat Res* 280, 136.

*Dr. Cherukuri Nagesh. "Management of Infected Non Union Distal third Tibia With Single Stage Ilizarov Method." *IOSR Journal of Dental and Medical Sciences (IOSR-JDMS)* 16.9 (2017): 17-20