

A Rare Case of Paraganglioma Presenting As Hydatid Cyst

*Dr. Vaibhav Krishna¹, Dr. Alok Chandra²,

¹Senior Resident, ²Associate Professor

Department of Pulmonary Medicine, Motilal Nehru Medical College, Allahabad (Uttar Pradesh)

Correspondence Author: Dr Vaibhav Krishna,

Abstract: Mediastinal paraganglioma are rare, highly vascularized tumours arising from chromaffin tissue located in the para-aortic ganglia. Tumours tend to invade bordering structures and may also form metastasis. Up to 50% of patients are asymptomatic and diagnosis is incidental. Herein, we discuss a case paraganglioma, A 40 yrs female who presented with chief presentation of right sided chest pain since 1.5 months and breathlessness since 15 days. Earlier she was diagnosed and treated as Hydatid cyst on basis Chest X-ray, other reports were inconclusive. On Examination patient was having tachycardia. Chest X-ray showed well defined round homogenous opacity. Eosinophils Counts were 16 Patient was discharged with appropriate treatment and was followed up. There was no significant improvement on followup. Then USG chest done which was inconclusive. Further CT thorax was done and it's changed the diagnosis to Posterior Mediastinal Mass i.e, Paraganglioma. Further management was done with supportive team of CTVS surgeons by removal of the mass, along with medical treatment and patient recovered uneventfully and is on regular follow-up.

Keywords: Paraganglioma, Echinococcus, ELISA, CTVS

Date of Submission: 29 -08-2017

Date of acceptance: 09-09-2017

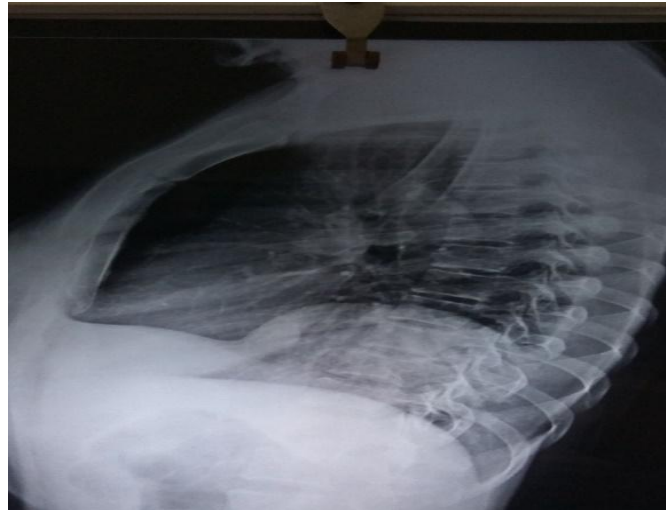I. Introduction

Paraganglioma are rare tumours that grow in cells of the peripheral nervous system. Their occurrence in the mediastinum is extremely rare. Such lesions are usually discovered on incidental chest radiographs of asymptomatic individuals. Although the radiographic features of these tumours have previously been reported¹⁻⁶. Unlike other types of cancer, there is no test that determines benign from malignant tumours; long-term follow-up is therefore recommended for all individuals with paraganglioma. Approximately 50% of patients with recurrent disease experience distant metastasis. The five-year survival in the setting of metastatic disease is 40% to 45%.⁷

II. Case Report

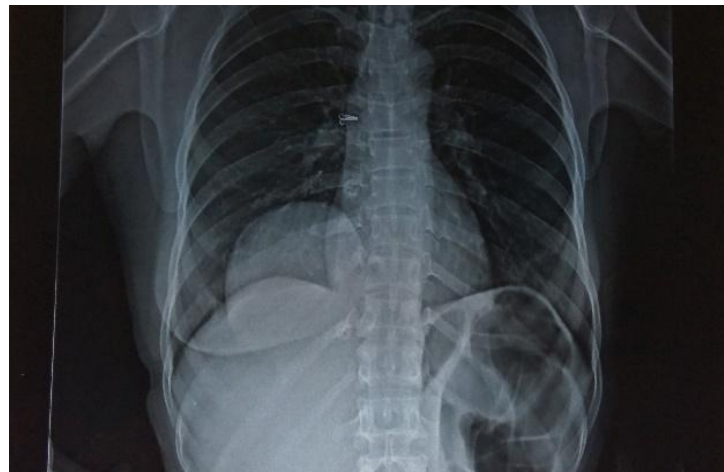
A 40 yrs female, non-smoker presented to us in July 2017 with complaints of right sided chest pain on and off since 1-2 month, which was dull aching, mild intensity, and continuous type. She also complained of generalised weakness since 3-4 months, along with on and off breathlessness MMRC grade II. There was no significant past history. There was no history of Hemoptysis, episodic headache, sweating, though tachycardia was present.

There was no pallor, Icterus, cyanosis, clubbing or lymphadenopathy. On respiratory system examination the only feature was breath sound decrease in right lower zone. Blood pressure was within normal limits. ECG was within normal limits. There was no significant finding in other system. Investigation revealed Packed Cell Volume (PCV-31.8), Mean corpuscles haemoglobin concentration (MCHC-38.6). Haemoglobin and total counts were within the normal limits. Chest X-Ray was done which revealed well defined round opacity in right lower zone. Patient was discharged with the treatment for hydatid cyst as patient was not willing for further investigations and was made to follow up after a month.



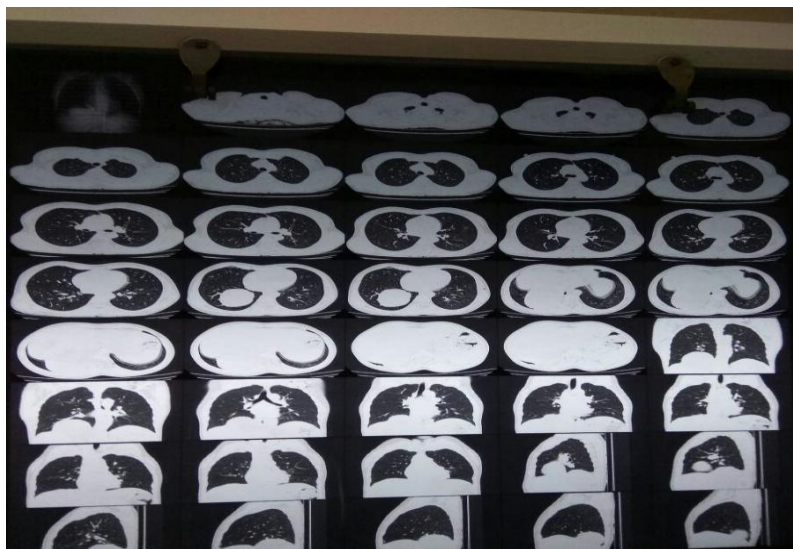On follow up Chest X-Ray was repeated and there was no significant improvement in the opacity. Patient symptoms also didn't showed any improvement. But developed a new features of Headache. Blood pressure was slightly on higher range (190/110).

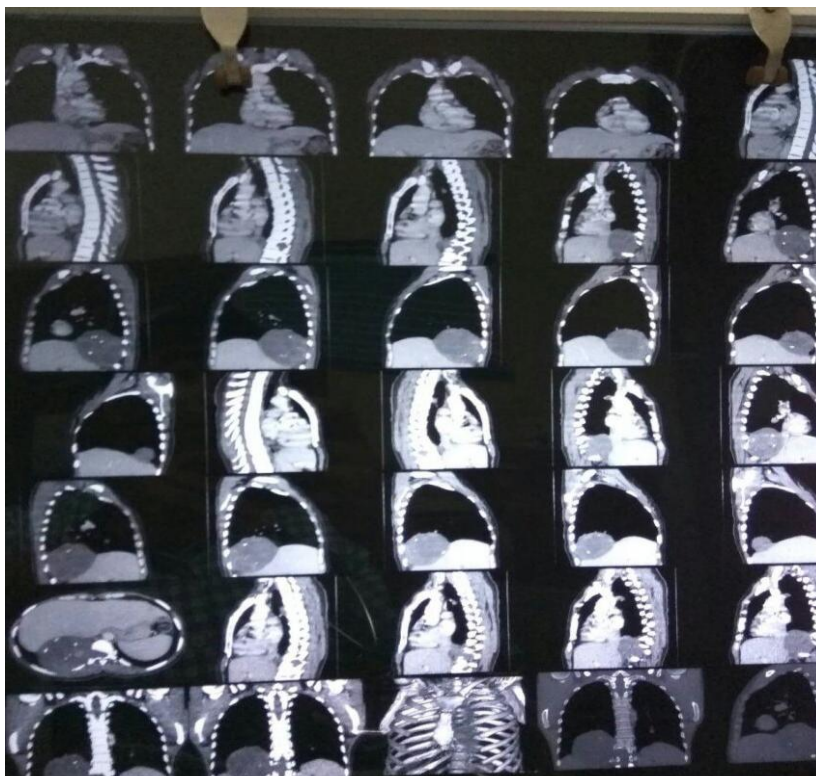
Chest Xray Lateral View



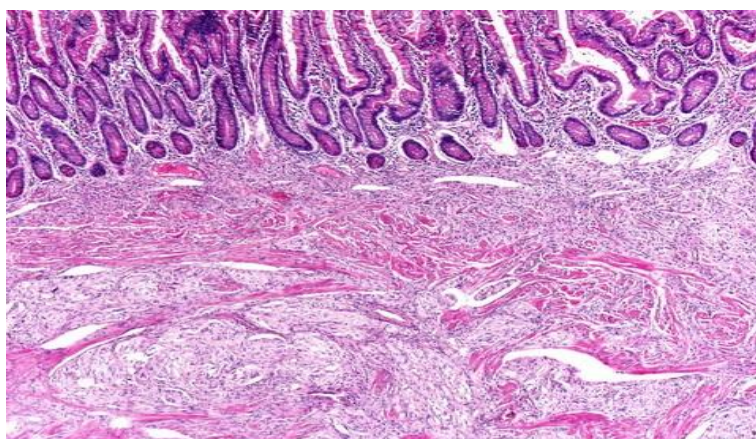
Chest Xray Pa View

CT chest was done and incidental and rare mediastinal mass was revealed i.e, Paraganglioma.





Patient was then managed with combined approach of CTVS and Pathology. Patient was subjected to surgery leading to removal of mediastinal mass. Resected mass was examined which was well circumscribed polypoid masses and they have a firm to rubbery consistency. They are highly vascular tumours and have a deep red colour.



Mass lesion was subjected to histopathological examination revealed Individual tumour cells are polygonal to oval and are arranged in distinctive cell balls, called *Zellballen*. These cell balls are separated by fibro vascular stroma and surrounded by sustentacular cells.

III. Conclusion

Physicians and Surgeons should consider paraganglioma as a differential diagnosis for extra-adrenal lesions. Adequate history and examination along with pathological investigation should be performed in affordable setup. CT Thorax is a non-invasive approach for diagnosis. Surgical removal should be done in order to avoid catastrophic complications.

References

- [1]. Haber S. Retroperitoneal and mediastinal chemodectoma: report of a case and review of the literature. *AJR* 1964;92: 1029-1041
- [2]. Lacquet LK, Moulijn AC, Jongerios CM, Umburg M, Rensing JB. Intrathoracic chemodectoma with multiple localizations. *Thorax* 1977;32:203-209
- [3]. Olson JL, Salyer WA. Mediastinal paragangliomas (aortic body tumor). *Cancer* 1978;41 :2405-2412
- [4]. Lack EE, Stillinger RA, Colvin OB, Groves AM, Bumette OG. Aorticopulmonary paraganglioma: report of a case with ultrastructural study and review of the literature. *Cancer* 1979;43: 269-278
- [5]. Ogawa J, Inoue H, Koide S, Kawada S, Shohtsu A, Hata J. Functioning paraganaglioma in the posterior mediastinum. *Ann ThoracSurg* 1982;33:507-510
- [6]. O'Altorio RA, Rishi US, Bhagwanani OG. Arteriographic findings in mediastinal chemodectoma. *J ThoracCardiovascSurg* 1974;67:963-965
- [7]. Wychulis AR, Payne WS, Clagett OT, Woolner LB. Surgical treatment Pheochromocytoma and Paraganglioma Treatment (PDQ®)—Patient Version - National Cancer Institute

*Dr. Vaibhav Krishna. "A Rare Case of Paraganglioma Presenting As Hydatid Cyst." *IOSR Journal of Dental and Medical Sciences (IOSR-JDMS)* 16.9 (2017): 57-60