

## **Amelanotic Malignant Melanoma of Maxilla: A Rarity- Case Report**

\*Dr. Manan Gupta<sup>1</sup>, Dr. Nitin Bhola<sup>2</sup>, Dr. Anendd Jadhav<sup>3</sup>, Dr. R.M. Borle<sup>4</sup>,  
Dr. Nupoor Deshpande<sup>5</sup>, Dr. Murtaza Fidvi<sup>6</sup>

<sup>1</sup>(Post Graduate student, department of Oral and Maxillofacial surgery, Sharad Pawar dental college & hospital, DMIMS, Wardha, Maharashtra, India, 442001)

<sup>2</sup>(Professor, department of Oral and Maxillofacial surgery, Sharad Pawar dental college & hospital, DMIMS, Wardha, Maharashtra, India)

<sup>3</sup>(Associate Professor, department of Oral and Maxillofacial surgery, Sharad Pawar dental college & hospital, DMIMS, Wardha, Maharashtra, India)

<sup>4</sup>(Professor, department of Oral and Maxillofacial surgery, Sharad Pawar dental college & hospital, DMIMS, Wardha, Maharashtra, India)

<sup>5</sup>(Post graduate student, department of Oral and Maxillofacial surgery, Sharad Pawar dental college & hospital, DMIMS, Wardha, Maharashtra, India)

<sup>6</sup>(Post graduate student, department of Oral and Maxillofacial surgery, Sharad Pawar dental college & hospital, DMIMS, Wardha, Maharashtra, India)

Corresponding Author: \*Dr. Manan Gupta

---

**Abstract:** Amelanotic malignant melanoma is a rare entity with challenging histopathological features, comprising of about 5-35% of all the oral mucosal melanomas. The most common site of its occurrence is maxillary gingiva and hard palate. Amelanotic form being more biologically aggressive and has poor prognosis than pigmented melanomas. Amelanotic malignant melanoma of maxilla has been sparsely reported. Surgery is the keystone treatment of choice with other adjuvant therapies. The present case report highlights the occurrence of this uncommon tumor at a common site which was managed surgically followed by adjuvant radiotherapy. A four year follow-up shows uneventful healing with no evidence of disease.

**Keyword:** Oral Melanoma, Amelanotic malignant melanoma, Maxilla, Mucosal melanoma.

---

Date of Submission: 11 -07-2017

Date of acceptance: 09-09-2017

---

### **I. Introduction**

Melanoma is a malignant tumor that arises from melanocytes and is most commonly cutaneous in origin. Extracutaneous melanomas are exceedingly rare and aggressive neoplasm that involves ocular, mucosal and leptomeningeal melanomas. Mucosal melanomas comprise 4-6.8% of all primary melanomas. Incidence of mucosal melanoma is 2.3 per million. [1] Malignant melanoma affects the gender equally with a slight male predominance. [2] Primary oral mucosal melanoma are believed to arise from pigmented nevi, pre-existing pigmented areas or de novo from apparently normal mucosa with predisposing factors like mechanical trauma including injury from ill-fitting prostheses, infection and tobacco use. [3] Hard palate and maxillary alveolus is predominant site for oral melanoma having vertical growth phase. [3] Oral melanoma is asymmetric, irregular in outline with surface architecture ranging from macular to ulcerated and nodular. Rarely melanoma is present without clinically evident pigmentation, which is known as amelanotic melanoma. One out of three of all oral melanomas are amelanotic approximately. [4] Oral Amelanotic malignant melanoma (OAMM) is difficult to diagnose as it lacks a radial (vertical) growth phase due to which it may be misdiagnosed as a squamous cell carcinoma or benign tumor. [3] Different treatment modalities include ablative surgery, chemotherapy, radiotherapy and immunotherapy. Surgery being the keystone treatment proves to be effective with the use of chemotherapy or radiotherapy to a lesser extent as adjuvant therapy.

Melanoma of head and neck region has a poor prognosis, review by **Nandapalan et al [5]** with 257 mucosal melanomas of the head and neck region showed that amelanotic melanomas had a 20% survival whereas pigmented melanoma had a 58% survival at 3 years. The present case highlights OAMM of hard palate extending upto floor of maxillary sinus in a 17 year old female which was successfully managed surgically followed by adjuvant radiotherapy and to discuss the clinical and pathological features, treatment and outcomes of this rare clinical variant.

## II. Case Report

A 17 year old female patient presented with the history of asymptomatic growth of size 3x3cms approx in palate since 6 months. The growth was small 6 months back and had rapidly increased to present size with no history of associated pain. On examination, intra orally a diffuse growth was seen in palate measuring 3x3cms approximately, extending from upper left 2<sup>nd</sup> premolar to upper right 2<sup>nd</sup> premolar mediolaterally and from lower left central incisor to midpalatine region anteroposteriorly, roughly oval in shape, irregular surface, diffuse borders, overlying mucosa was ulcerated. On palpation, the growth was soft to firm in consistency and non-tender (Fig 1). A single left submandibular lymph node was palpable of size 1x0.5cms approximately, roughly oval in shape, mobile, firm in consistency and non-tender in nature. Based on clinical examination provisional diagnosis was suspected to be squamous cell carcinoma.

Contrast enhanced computed tomography (CECT) was done (Fig 2). CECT revealed a single ill-defined hypodense soft tissue attenuating lesion of approximately size 3.8x2.7x1.8cms noted in the region of hard palate in the midline and extending to the left with destruction of the maxilla with displacement of the upper incisors and canines of left side which was abutting the floor of the left maxillary sinus and the ala of the nose with intact wall of left maxillary sinus was seen. Squamous cell carcinoma or sarcoma was considered as differential diagnosis, to rule out the final diagnosis incisional biopsy was performed which was suggestive of Malignant Melanoma. Preoperative evaluation was performed and based on the clinical, histological and radiographic diagnosis surgical excision of lesion, bilateral neck dissection and reconstruction with microvascular free fibula flap was planned under General Anesthesia and patient was taken for surgery.

A vestibular incision was given from upper right 2<sup>nd</sup> molar to upper left 2<sup>nd</sup> molar region. High level Le Fort I osteotomy was performed and wide local excision of lesion taking 2 cm of safe margin was done (Fig 3 & 4). MRND on left side, SND on right side and reconstruction with osteomyocutaneous free fibula flap harvested from left side was done. The specimen obtained was sent for histopathological examination. The H & E stained tissue sections revealed presence of spindle cells with large ovoid vesicular to hyper chromatic nucleus with eosinophilic to clear cytoplasm. Round cells with round to ovoid hyper chromatic nucleus and scanty eosinophilic cytoplasm to clear cytoplasm. A population of clear cells with hyperchromatism nuclear shifted to periphery. All the cells showing nuclear and cellular pleomorphism, altered nuclear cytoplasmic ratio and significant mitotic activity. (Fig 5)

**IHC Markers:-** Vimentin, S-100 and HMB-45 were positive. All features were suggestive of **Amelanotic malignant melanoma**.

Patient then underwent 30 cycles of radiotherapy. Patient was followed for 4 years with no evidence of node positivity.

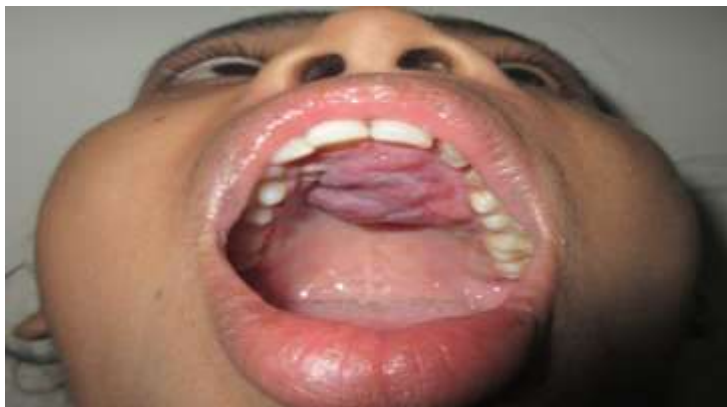

Figure 1

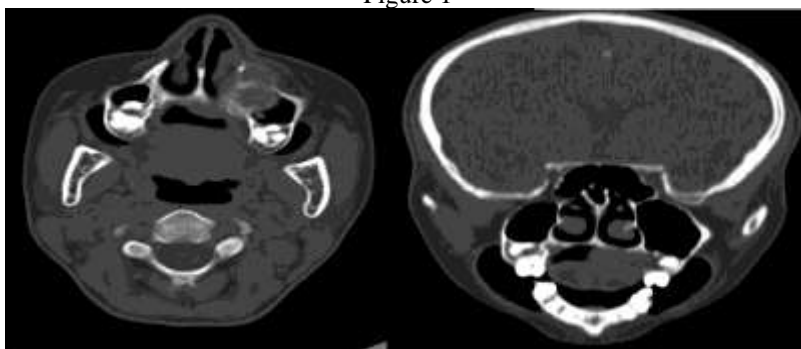


Figure 2

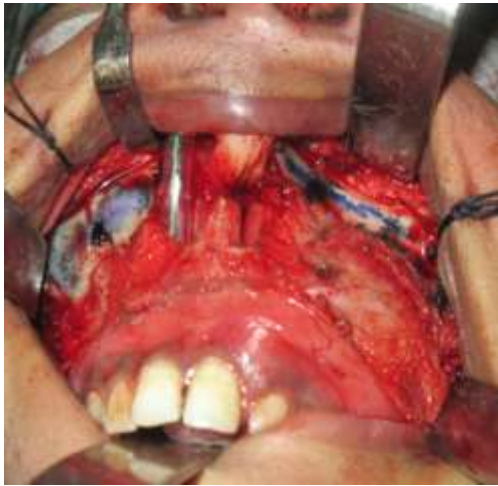

Figure 3

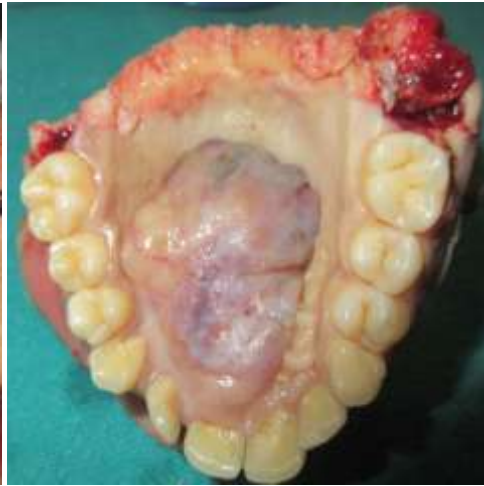


Figure 4

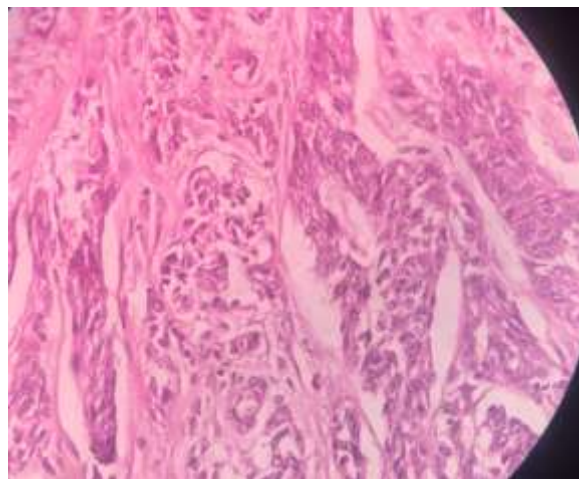


Figure 5

**Figure 1:** Intraoral photograph showing proliferative growth, **Figure 2:** CECT axial & coronal cut showing lytic destruction of the maxilla on left side, **Figure 3:** Marking for high Le Fort I osteotomy cut, **Figure 4:** Resected specimen, **Figure 5:** 40X view of H & E stained tissue section showing spindle cells with large ovoid vesicular to hyper chromatic nucleus and clear to eosinophilic cytoplasm.

### III. Discussion

Primary malignant mucosal melanoma of the head and neck is a rare entity. In 1856 (Germany), **Weber** first described mucosal melanoma. [6] It is commonly found in 3<sup>rd</sup> to 8<sup>th</sup> decade of life with male predilection. The most frequent site of occurrence is the hard palate, maxillary gingiva, mandible, tongue, buccal mucosa and lips. Etiological factor includes familial and environmental factors such as exposure to UV radiation and precursor lesions like atypical nevi. OAMM accounts for 5-35% of all the oral melanomas, which appears as a white, mucosa-coloured or red mass. Lymph nodes, liver and lung being common sites of metastasis with a widespread involvement occurring in advanced disease. Amelanotic melanoma has a worse and poorer prognosis than that of pigmented melanomas because of the delay in establishing the correct diagnosis, histological misdiagnosis and delay in the initiation of the treatment. According to **Pfister DG et al** [7] treatment of stage IVA lesion involving oral cavity is wide surgical excision with 1.5-2 cm of visible and palpable normal mucosa for clear margin with neck dissection and post operative radiotherapy. In the present case we performed a wide local excision of lesion with 2 cm of safe margin. **Rogers and Gibson** [8] reported that half of all patients with oral melanoma had regional lymph node metastases. Present case was classified under Stage IVA according to AJCC-TNM [3] classification for the mucosal melanoma of the head and neck for which MRND type III on left side and SND upto level III on right side was performed. Tumour are composed of variable cell types like epithelioid, spindled, plasmacytoid, rhabdoid, or multinucleated morphology in combination or alone in an organoid arrangement with round, vesicular nuclei

and central, prominent, eosinophilic nucleolus are important histological markers for melanomas. Intracellular melanin helps in identification of melanoma, which is absent in amelanotic variant making it difficult to diagnose. [2]

**Leong et al [9]** found immunohistochemical profile of oral malignant melanoma to be similar to cutaneous melanoma, with the exception that oral melanomas were negative for cytokeratin & **Barbosa de Paulo LF et al [2]** stated that HMB-45 is the most utilized melanoma marker for OAMM. In present case HMB- 45, Vimentin & S-100 was positive whereas cytokeratin was negative in immunohistochemical profile. Radiotherapy plays a palliative role, as on its own it was reported to be ineffective since the lesion is not very radiosensitive, however **Tanaka et al [10]** found radiotherapy to be more successful than surgery for oral melanoma. In present case patient then underwent 30 cycles of post operative radiotherapy. Other adjuvant treatment includes chemotherapy, 20% response rate as a single agent was reported by using dacarbazine as chemotherapy agents. [11] OAMM have poor prognosis as compared to pigmented melanoma, the overall 1, 2, and 5-year survival rate of OAMM was 70.0, 59.5 and 34.4 % respectively with a median survival time of 29 months. [2] This may be due to the fact that amelanotic lesion tend to exhibit vertical growth pattern while pigmented lesion showed a more radial growth pattern. **Milton [12]** stated that fast-growing melanomas often have relatively less pigment than slow-growing ones. However, **Umeda et al [13]** stated a 63.6% 5-year cumulative survival and concluded that the prognosis of oral melanoma was not as poor as reported previously. In present case patient was followed for 4 years with disease free survival.

#### IV. Conclusion

Primary OAMM is a rare and aggressive malignancy for which early diagnoses by histological examination together with immunochemistry are the keys to improve the survival rate. Since the oral cavity is the common site of involvement, one should include amelanotic melanoma as a differential diagnosis for a rapid, non-pigmented gingival enlargement.

#### References

- [1]. Haiducu ML, Hinek A, Astanehe A, Lee TK, Kalia S. Extracutaneous melanoma epidemiology in British Columbia. *Melanoma Res.* 2014; 24: 377-380. PMID: 24722196.
- [2]. Luiz Fernando Barbosa de Paulo, João Paulo Silva Servato, Roberta Rezende Rosa, Maiolino Thomaz Fonseca Oliveira, Paulo Rogério de Faria. Primary amelanotic mucosal melanoma of the oronasal region: report of two new cases and literature review. *Oral Maxillofac Surg* 20 April 2015.
- [3]. Olga Warszawik-Hendzel, Monika Słowińska, Małgorzata Olszewska, Lidia Rudnicka. Melanoma of the oral cavity: pathogenesis, dermoscopy, clinical features, staging and management. *J Dermatol Case Rep* 2014 3, pp 60-66.
- [4]. Tomicic J, Wanebo HJ. Mucosal melanomas. *Surg Clin North Am.* 2003; 83: 237-252. PMID: 12744608.
- [5]. Nandapalan V, Roland NJ, Helliwell TR, Williams EM, Hamilton JW, Jones AS. Mucosal melanoma of the head and neck. *Clin Otolaryngol Allied Sci* 1998; 23: 107–116.
- [6]. Bansal S, Desai RS, Shirsat P. Amelanotic melanoma of the oral cavity: A case report and review of literature. *Int J Oral Maxillofac Pathol* 2012;3:31-6.
- [7]. David G. Pfister, Kie-Kian Ang, David M. Brizel, Barbara Burtness, Anthony J. Cmelak. A. Dimitrios Colevas. Mucosal Melanoma of the Head and Neck. *Journal of the National Comprehensive Cancer Network | Volume 10 Number 3 | March 2012.*
- [8]. Rogers RS, Gibson LE. Mucosal, genital, and unusual clinical variants of melanoma. *Mayo Clin Proc* 1997; 72: 362–366.
- [9]. Leong AS, Milios J. An assessment of a melanoma- specific antibody (HMB- 45) and other immunohistochemical markers of malignant in paraffin- embedded tissue. *Surg Pathol* 1989; 2:137- 45.
- [10]. Tanaka N, Amagasa T, Iwaki H et al. Oral malignant melanoma in Japan. *Oral Surg Oral Med Oral Pathol* 1994; 78: 81–90.
- [11]. Balch CM, Houghton A, Peters L. Cutaneous melanoma. In De Vita VT Jr, Hellman S, Rosenberg SA, eds. *Cancer: Principle & Practice of Oncology*, 3rd edn. Philadelphia: Lippincott, 1989: 1499–1542.
- [12]. Milton GW. Melanoma of the nose and mouth. In: Milton GW, ed. *Malignant melanoma of the skin and mucous membrane.* Edinburgh: Churchill Livingstone, 1977; 157–164.
- [13]. Umeda M, Shimada K. Primary malignant melanoma of the oral cavity, its histological classification and treatment. *Br J Oral Maxillofac Surg* 1994; 32: 32–47.

\*Dr. Manan Gupta. "Amelanotic Malignant Melanoma of Maxilla: A Rarity- Case Report ." IOSR Journal of Dental and Medical Sciences (IOSR-JDMS) 16.9 (2017): 86-89