

## A Comprehensive Study of Clinical And Radiological Outcome of Core Decompression in Avascular Necrosis Stage 1 And 2 (Ficat & Arlet Classification) in Femur Head

\*Dr. Srinivas Bachu<sup>1</sup>, Dr Premanandam Talari<sup>2</sup>, Dr Amar Babu bonike<sup>3</sup>  
Associate Professor, Department Of Orthopaedics, Government Medical College Nizamabad, India.  
Assistant Professor, Department Of Orthopaedics, Government Medical College Nizamabad, India.  
Senior Resident, Department Of Orthopaedics, Government Medical College Nizamabad, India  
Corresponding Author: \* Dr Premanandam Talari

---

### Abstract

**Background:** Avascular necrosis (AVN) is a relatively common disease characterized by death of cellular elements of bone or marrow. The hip (femoral head) is the most commonly affected site for clinically significant AVN. The classification system introduced by Ficat & Arlet is possibly the most commonly used. Aim is to study functional outcome of core decompression in avascular necrosis of femoral head (Ficat & Arlet and Arlet stage I and II) using The Harris Hip Score & to evaluate the radiological progress after core decompression of femoral head.

**Methodology:** A Prospective Study done in Department of Orthopaedics in Government Medical College Nizamabad, with a sample size of 35 hips in 26 patients during period from September 2014 to August 2017. Patients diagnosed to be suffering from AVN type 1 and type 2 are admitted, their history, clinical features and investigations reports are reviewed. Their Core decompression is carried out and the outcome is evaluated at 3 months and 6 months using HARRIS HIP SCORE.

**Results:** Out of the 26 patients 10(38.5%) patients showed EXCELLENT and 13(50%) patients showed GOOD result with improvement in HHS and 3(11.5%) patients showed FAIR result (with 2 hips showing progression of the disease) at 6 months follow up.

**Conclusion:** Core decompression is recommended in Stage I & II avascular necrosis of femoral head as it does not preclude additional operative intervention.

**Keywords:** Avascular necrosis, Core decompression, femoral head, Ficat & Arlet classification

---

Date of Submission: 11 -09-2017

Date of acceptance: 22-09-2017

---

### I. Introduction

Avascular necrosis (AVN), also known as osteonecrosis, aseptic necrosis and ischemic bone necrosis, is a relatively common disease characterized by death of cellular elements of bone or marrow. Most of the people who develop AVN annually are between the ages of 20 and 50 years. In Central India, sickle cell disease has a very high prevalence and is the most common associated condition with osteonecrosis followed by alcohol abuse and corticosteroid use. [1] The hip (femoral head) is the most commonly affected site for clinically significant AVN. The most commonly identified causative factors are high doses of corticosteroids and chronic and excessive alcohol intake. In most series, approximately 15% of the cases are considered to be idiopathic. It has recently been shown that in approximately 70% of idiopathic cases, subtle coagulopathies are present. The classification system introduced by Ficat & Arlet is possibly the most commonly used. However, in the literature, this classification system has been criticized because of great inter- as well as intra-observer variability. Moreover, the Ficat & Arlet classification does not take the size and location of the necrotic area into account. For appropriate consideration of the missing parameters the ARCO (Association Research Circulation Osseous) classification system was introduced. [2]

Operative treatments include fusion, osteotomy, hemi resurfacing, hemiarthroplasty, core decompression with or without grafting, as well as total hip arthroplasty. [3] Phemister [4], Bonfiglio and Bardenstein and Boettcher et al. [5] were used core decompression to examine the pathologic changes in femoral heads of patients who were suspected of having AVN in their studies. Present study started with objectives to study functional outcome of core decompression in avascular necrosis of femoral head (Ficat & Arlet and Arlet stage I and II) using The Harris Hip Score and to evaluate the radiological progress after core decompression of femoral head.

## II. Material & Methods

**Study setting:** Department Of Orthopaedics, Government Medical College Nizamabad.

**Study design:** An Observational Prospective Study.

**Sample Size:** During this study period 26 patients with 35 hips were studied.

**Period of study :** September 2014 to August 2017

**Inclusion Criteria:** Type 1 and type 2 AVN according to Ficat & Arlet classification, both unilateral and bilateral cases & all adults older than 18 years & both males and females included

**Exclusion Criteria:** Type 3 and Type 4 of Ficat & Arlet classification for AVN of hip, Patients with mental retardation or drug dependency, Severe systemic illness (active cancer, chemotherapy, insulin-dependent diabetes mellitus, renal failure, hemophilia, or medical contraindication for surgery) & Patients who refused to participate in the study or were lost to follow-up. Method of conducting study and follows ups: Patients diagnosed to be suffering from AVN type 1 and type 2 are admitted, their history, clinical features and investigations reports are reviewed. Preoperative radiological staging of osteonecrosis is done according to Ficat & Arlet classification. Their Core decompression is carried out and the outcome is evaluated at 3 months and 6 months using HARRIS HIP SCORE. The primary evaluation criteria is functional outcome and is considered as good if there is improvement in Harris hip score and the radiological appearance is considered good if the hip remained in stage I or stage II and poor if the disease progressed. Statistical Analysis: Data entered in Microsoft Excel and analysis was done by using SPSS software version 16. Categorical variables were represented as percentages and Chi-square test was done for finding out the significance. P value < 0.05 is considered as statistical significance at 95% confidence intervals.

## III. Results

Table 1: Distribution of various characteristics of study participants

Variable	Category	Number of patients (n)	Percentage (%)
Gender	Male	18	69.2 %
	female	8	30.8 %
Age groups (yrs)	21-30	13	5 %
	31-40	10	38.5 %
	41-50	3	11.5 %
Side of hip involved	Right side	19	54.2 %
	Left side	16	45.8 %
Stage of disease	Stage I	8	22.8 %
	Stage II	27	77.2 %
Laterality of disease	Unilateral	17	65.4 %
	Bilateral	9	34.6 %
Etiology of disease	Idiopathic	17	65.4 %
	Alcohol&smoking	5	19.2%
	Long term steroids	4	15.4%

Out of the 26 patients in the present study 22(84.6%) patients had a pre-operative HHS ranging from 70 – 79 and 3(18.6%) patients had a HHS ranging from 60-69 and 1(3.8%) case 80-89. Out of the 17 unilateral cases in 16(94.1%) patients had a HHS ranging from 70 – 79 and 1(5.9%) case 80-89. Out of the 9 bilateral cases 6(66.7%) patients had a HHS ranging from 70-79 and 3(33.3%) cases had an HHS ranging from 60-69.

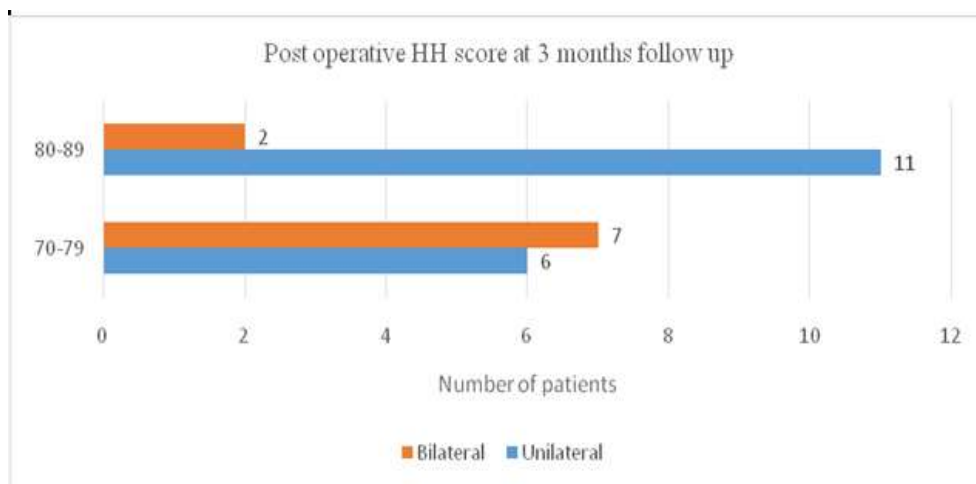


Fig 1. Post operative harris hip scores at 3 months follow up.

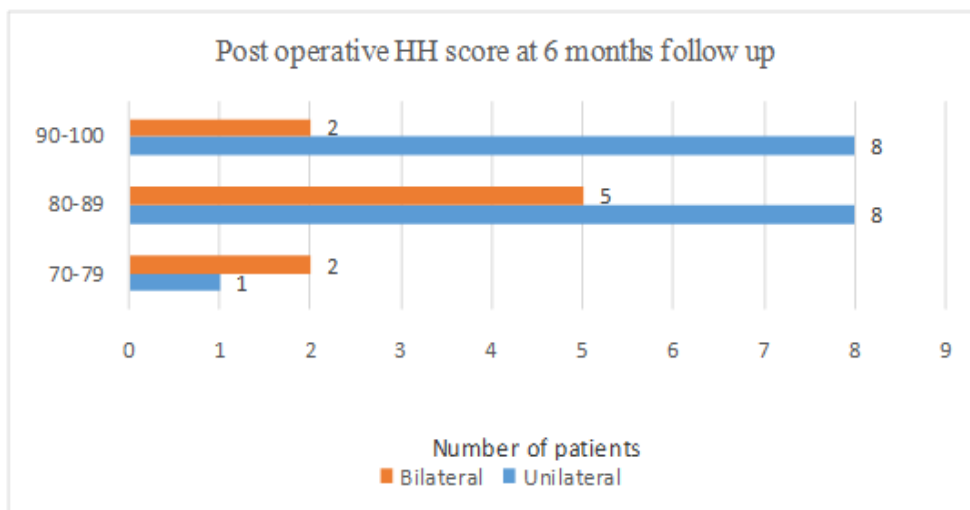


Fig 2. Post operative harris hip scores at 6months follow up

Out of the 17 unilateral cases 8(47%) patients showed EXCELLENT result with improvement in HHS and other 8(47%) patients showed GOOD result with improvement in HHS other 1(6%) patient showed FAIR result at 6 months follow up. Out of the 9 Bilateral cases 2(22%) patients showed EXCELLENT result with improvement in HHS and 5(56%) patients showed GOOD result with improvement in HHS 2(22%) patients showed FAIR result at 6 months follow up.

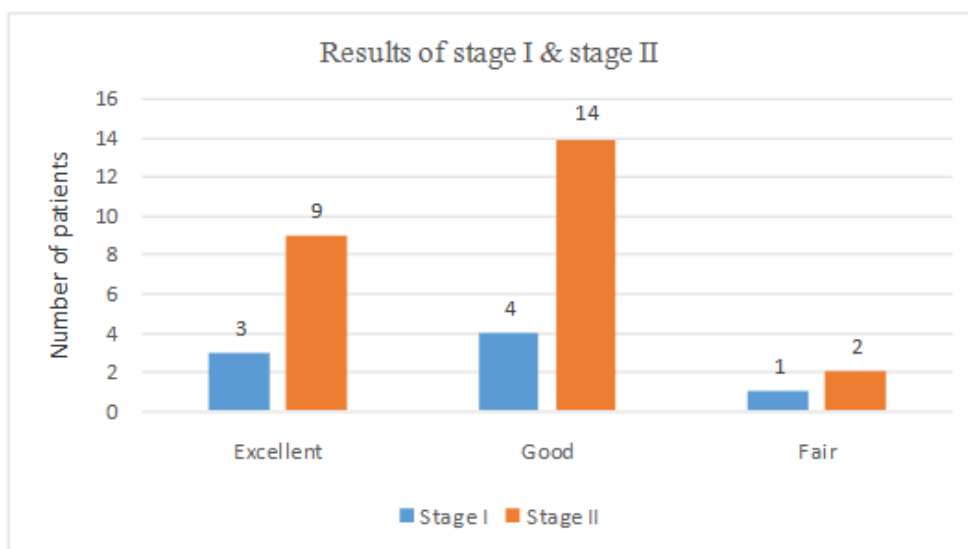


Fig 3: Results in Stage 1 & stage II of the disease

#### IV. Discussion

Need to treat ischemia of femoral head is becoming more common since many cases are detected in early stages in young patients. One must consider the possibility of osteonecrosis if a young individual has pain in the vicinity of hip that had history of chronic alcoholism, corticosteroid usage, associated disease like sickle cell, Gaucher's, Gout etc. [6]. Barring exceptional circumstances, there is hardly any role of conservative treatment of osteonecrosis of femoral head and surgery is inevitable. Steinberg *et al.* [7, 8] reported that progression occurred in 92% of 48 hips that had undergone non-operative management. While observing the patients with protected weight bearing, more than 85% patients had collapse of femoral head at 2 years when symptomatic hips with stage I and II were treated conservatively. More studies have shown that non-operative treatment yields poor results. In our series, we had a good functional outcome of 92.3% patients operated with core decompression of femoral head. The core track in core decompression may promote the formation of healthy bone by reducing bone marrow pressure as well as inducing neo-vascularization. The clinical efficacy of core decompression was reported to closely associate with the stage and the size of necrotic lesion. [9] Mont, Carbone and Fairbank, in 1996, In a comprehensive review of the literature published, reviewed 42 separate

reports involving 2,025 hips and concluded that, compared to non-operative or symptomatic management, core decompression with or without a bone graft was a safe and effective procedure for the treatment of early stages of avascular necrosis [10]. Steinberg et al (2001) reviewed the results of a prospective study of 406 hips in 285 patients treated by one surgeon with core decompression and bone grafting. He stated that patients who underwent core decompression and bone grafting have a very low complication rate. In patients treated before femoral head collapse, the outcome is significantly better than in patients who received symptomatic treatment [11]. According to a previous systematic review conducted by Mont et al [12], stratification of the core decompression group into Ficat stages revealed better results for treatment of osteonecrosis in its early stages. Femoral head survival rate (clinical success) was 84% (190 of 227 hips) for Stage I, 65% (155 of 239 hips) for Stage II, and 47% (40 of 86 hips) for Stage III. Stratification by other etiologic and demographic factors did not influence overall percentages.

Ficat [13] reviewed the results of core decompression in 133 patients with avascular necrosis of femoral head and reported a successful clinical result in 90% of patients with no radiographic progression in 79% of them. The failure rate was 6% for stage I hips and 18% for stage II hips. In our study group, we had a successful clinical result in 88.4% of patients with no radiographic progression in 92.3% of them. Failure rate was nil in stage I hips and 7.6% (2 cases) in stage II hips. Camp and Colwell (18) reported the results of core decompression in 25 hips. At an average follow up of 18 months, the success rate for stage I was 37.5% and stage II was 45.5%. They also reported a high complication rate of 14% among their cases. The most common complication is a fracture (Subtrochanteric fracture or Intertrochanteric fracture). The combination of very high stresses in the proximal femur with a large, unsupported defect in the lateral cortex greatly increases the likelihood of fracture with weight bearing. Multiple surgeons and different surgical techniques were attributed for high complication rates in their study. However, we had a complication rate of 7.6% (superficial infection in two patients and no case of post operative fracture) in our study group. Our results demonstrate an important relationship with steroid usage and progression of avascular necrosis. Two of the three cases reported to have fair functional outcome had Stage II disease and history of steroid usage was the aetiological factor identified among them. Carlos et al [14] reported that alcohol consumption as an important factor in progression of disease. In our study, no case with alcohol consumption as aetiological factor had disease progression.

## V. Conclusion

Although Avascular necrosis of femoral head is a well-known disease, its pathogenesis remains enigmatic. The ultimate goal of treatment is to preserve the joint by early diagnosis and proper intervention. Considering the good results obtained with surgical treatment of osteonecrosis of femoral head with core decompression in early stages of Avascular Necrosis of Femoral Head (Stage I & II Ficat & Arlet), it is justifiable that osteonecrosis should be operated by this method. Core decompression, when performed before onset of sub-chondral collapse is capable of interrupting disease process. We recommend core decompression in Stage I & II avascular necrosis of femoral head as it does not preclude additional operative intervention.

## References

- [1]. Babhulkar S.S. Osteonecrosis of the femoral head (in young individuals). *Indian J Orthop.* 2003; 37(2):2.
- [2]. Sen R.K. Management of avascular necrosis of femoral head at pre-collapse stage. *Indian J Orthop.* 2009; 43(1): 6–16.
- [3]. Shannon BD, Trousdale RT. Femoral osteotomies for avascular necrosis of the femoral head. *Clin Orthop Relat Res.* 2004 Jan; 418:34-40.
- [4]. Pheemister DB. Treatment of the necrotic head of the femur in adults. *J Bone Joint Surg.* 1949; 31:55–66.
- [5]. Boettcher WG, Bonfiglio M, Smith K. Non-traumatic necrosis of the femoral head: II. Experiences in treatment. *J Bone Joint Surg [Am].* 1970; 52-A: 322-329.
- [6]. Jones JP Jr. Fat embolism, intravascular coagulation and osteonecrosis. *Clin Orthop Relat Res* 1993;292:294-308.
- [7]. Steinberg ME, Brighton CT, Hayken GD, Tooze SE, Steinberg DR. Electrical stimulation in the treatment of Osteonecrosis of the femoral head: A 1 year follow-up. *Orthop Clin North Am* 1985;16:747-56.
- [8]. Steinberg ME, Hayken GD, Steinberg DR. The conservative management of avascular necrosis of the femoral head. In: Arlet A, Ficat RP, Hungerford DS, editors. *Bone circulation.* Baltimore: Williams and Wilkins; 1984. pp. 334–7.
- [9]. Vulpiani MC, Vetrano M, Trischitta D, Scarcello L, Chizzi F, Argento G, Saraceni VM, Maffulli N and Ferretti A. Extracorporeal shock wave therapy in early osteonecrosis of the femoral head: prospective clinical study with long-term follow-up. *Arch Orthop Trauma Surg* 2012; 132: 499-508.
- [10]. Mont MA, Carbone JJ, Fairbank AC. Core decompression vs. non-operative management for avascular necrosis of the femoral head. *Clin Orthop Relat Res.* 1996; 324:169–78.
- [11]. Steinberg ME. Diagnostic imaging and role of stage and lesion size in determining outcome in osteonecrosis of the femoral head. *Tech Orthop.* 2001;16: 6–15.
- [12]. Camp, J.F., C.W. Colwell: Core decompression of the femoral head for osteonecrosis. *JBJS.* 1986; 68-A: 1313-1319.
- [13]. Ficat RP. Idiopathic bone necrosis of the femoral head: Early diagnosis and treatment. *J Bone Joint Surg Br.* 1985; 67: 3–9.
- [14]. Carlos JL, Rafael JS. Core decompression in traumatic osteonecrosis of the hip. *The Journal of Arthroplasty.* 2000; 15(2).

\* Dr Premanandam Talari “A Comprehensive Study of Clinical And Radiological Outcome of Core Decompression in Avascular Necrosis Stage 1 And 2 (Ficat & Arlet Classification) in Femur Head.” *IOSR Journal of Dental and Medical Sciences (IOSR-JDMS)* , vol. 16, no. 09, 2017. pp. 59–62.