

Analysis of Female Breast Fine Needle Aspiration Cytology

*Godstime I Irabor,¹ Ejemen G. Aigbe,² Dominic Akpan,³ Edoise M. Isiwele,⁴
Kenneth Omoruyi,⁵ Martin A Nnoli.⁵

¹Department of Pathology, Saba University School of Medicine, Saba, Netherlands

²Irrua specialist Teaching Hospital, Irrua, Edo State, Nigeria.

³Department of Laboratory Medicine and Pathobiology, University of Toronto, Ontario, Canada.

⁴Department of Surgery, University of Calabar Teaching Hospital, Calabar, Nigeria

⁵Department of Pathology, University of Calabar Teaching Hospital, Calabar, Nigeria

Corresponding Author: Godstime I Irabor

Abstract

Background: The adult female breast consists of a series of ducts, ductules, and lobular acinar units embedded within a stroma that is composed of varying amounts of fibrous and adipose tissue in contrast to the epithelial elements of the male breast which consist of branching ducts without lobule formation. Breast lesions could result from diseases affecting any of these anatomical structures of the breast. Fine needle aspiration cytology (FNAC) of the breast is a rapid and safe method for the diagnosis of breast lumps with an impressively short turnaround time.

Aim: To determine the analysis of female breast fine needle aspiration cytology in Calabar from January, 2012 to December, 2016.

Methodology: This study is a retrospective study on the prevalence of the different diagnosis of fine needle aspiration cytology of the female breast done the department of Pathology, University of Calabar Teaching Hospital from January, 2012 to December, 2016. Information including patient sociodemographic data, clinical information and diagnosis were obtained from the cytology register and laboratory request form. The FNAC samples were reported using the 5-tier system: C1 (unsatisfactory), C2 (benign), C3 (suspicious probably benign), C4(suspicious probably malignant) and C5 (malignant).

Results: . In this study, the 974 FNAC specimens were analysed. The age range of the patient is between 11 and 79 years of age. The mean age of the subjects is 41.4 ± 1.7 years. The group of patients with the highest proportion of samples is age group 21 - 30 years making up 22.4% of all the FNAC samples analyzed. In all, 476 of the lumps were in the right breast making up 48.9% of the total samples analyzed, the 454 were in the left breast comprising 46.6% of the patients, while 44 were bilateral making up 4.5% of the patients. The group of patient with the highest frequency of diagnosis is C2 (benign) making up 41.3% of the cases, followed by C5 constituting 28.2%, C3 (13.8%), C4 (13.%) and then C1 (3.7%).

Conclusion: The rapid diagnosis of a breast lump through an FNAC is of great help in making decisions on patients' management. An accurate and reliable FNAC goes a long way in helping patient care worldwide.

Keywords: Breast, Fine Needle, Aspiration, Cancer and Tumour.

Date of Submission: 11-01-2018

Date of acceptance: 25-01-2018

I. Background

The breast rests on a bed that extends transversely from the lateral border of the sternum to the midaxillary line and vertically from the 2nd through 6th ribs. Two thirds of the bed of the breast are formed by the pectoral fascia overlying the pectoralis major; the other third, by the fascia covering the serratus anterior. The breast consists of glandular tissue and fibrous and adipose tissue between the lobes and lobules of glandular tissue, together with blood vessels, lymphatic vessels, and nerves.¹ The histology of the breast varies according to gender, age, menopausal status, phase of the menstrual cycle, pregnancy, and lactation, among other factors. Whether a given breast specimen is normal or shows pathologic alterations must take these variables into consideration. The adult female breast consists of a series of ducts, ductules, and lobular acinar units embedded within a stroma that is composed of varying amounts of fibrous and adipose tissue in contrast to the epithelial elements of the male breast which consist of branching ducts without lobule formation.² Most lymph (> 75%) from the breast, especially from the lateral quadrants, drains to the axillary lymph nodes, initially to the anterior nodes and some lymph may drain directly to other axillary nodes or even to interpectoral, deltopectoral, supraclavicular, or inferior deep cervical nodes.^{1,2}

Cancer of the breast is one of the most common human neoplasm, accounting for approximately one quarter of all cancers in females. It is associated with the Western lifestyle, and incidence rates are therefore highest in countries with advanced economies. Additional risk factors include early menarche and late childbirth. Breast cancer is further characterized by a marked genetic susceptibility. Early detection and advances in treatment have begun to reduce mortality rates in several countries. Discovering a breast lump can be a significant cause of anxiety in a patient. This is because of the fear of the possibility of such lump being a cancer. Fine needle aspiration cytology (FNAC) of the breast is a rapid and safe method for the diagnosis of breast lumps with an impressive short turnaround time.^{3,4} FNAC is a known type of interventional cytology. It is a procedure involving the collection of cells from lesion/lumps using a fine needle and syringe. It has been used for the diagnosis of breast lesions over the years.^{5,6} FNAC is complementary to the conventional surgical histopathology.⁷ Fine needle aspiration cytology should be interpreted in correlation with the clinical and imaging findings in the patient. However since imaging studies can be difficult to come by in poor resource settings, with experienced cytopathologist the precision of the diagnosis is much higher.⁸

II. Materials And Method

This study is a retrospective study on the prevalence of the different diagnosis of fine needle aspiration cytology of the female breast done the department of Pathology, University of Calabar Teaching Hospital from January, 2012 to December, 2016. The sociodemographic data, clinical information and diagnosis were obtained from medical records (including the cytology register and laboratory request form). The samples were obtained using 23G needle and syringe from the breast lump and any palpable axillary lymph node. At least, 4 smeared slides were made from the aspirate and stained with Papanicolaou stain for samples fixed in 95% alcohol and May Grunwald Geimsa stain for air dried smears. The FNAC samples were reported using the 5-tier system: C1 (unsatisfactory), C2 (benign), C3 (suspicious probably benign), C4 (suspicious probably malignant) and C5 (malignant). Cases with missing data and male breast FNAC were excluded from this study. The data was analysed using simple inferential statistics

III. Result

A total of 1,159 FNAC specimen were received and analysed in the department of Pathology, University of Calabar Teaching Hospital Calabar during the study period of which 974 were female breast FNAC samples. In this study, the 974 FNAC specimens were analysed. The female breast FNAC comprises 84% of all the FNAC samples processed during the study period (January 2012 to December 2016) The age range of the patient is between 11 and 79 years of age. The mean age of the subjects is 41.4 ± 1.7 years. Total FNAC specimens: 1,159 Total FNAC female breast: 974 which constitute 84% of the total FNAC specimens

Table 1: Socio-Demographic Data

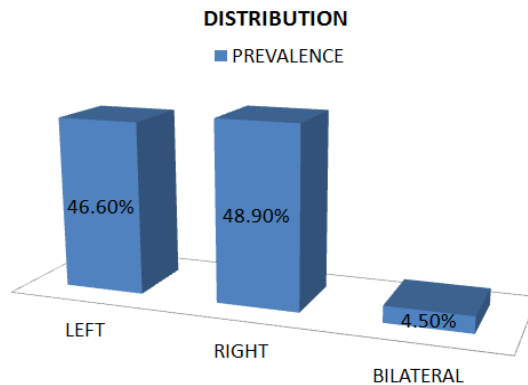
S/N	Age Group(Years)	Frequency	Prevalence (%)
1	11 – 20	111	11.4
2	21 – 30	218	22.4
3	31 – 40	141	14.5
4	41 – 50	166	17.1
5	51 – 60	172	17.7
6	61 – 70	138	14.2
7	71 – 80	30	3.1
Total		974	100

Age range: 11 to 79 years

Mean age \pm SD: 41.4 ± 1.7 years

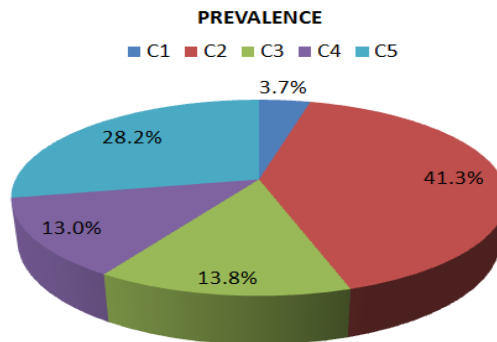
The group of patients with the highest proportion of cases is age group 21 to 30 years making up 22.4% of all the FNAC samples analyzed in this study. This is followed by the age group 51 to 60 years which makes up 17.7% of the total female breast FNAC samples and then the age group 41 to 50 years which made up 17.1% of the total sample, 61-70 years (14.2%), 11-20 years (11.4%) and then 71-80 years (3.1%).

FIGURE 1: DISTRIBUTION OF SPECIMEN BY SIDE



In all, 476 of the lumps were in the right breast making up 48.9% of the total samples analyzed, the 454 were in the left breast comprising 46.6% of the patients, while 44 were bilateral making up 4.5% of the patients.

FIGURE 1: FNAC DIAGNOSIS



C1= Unsatisfactory, C2 = Benign, C3 = Suspicious, probably benign, C4 = Suspicious probably malignant, C5 = Malignant Figure 2 above shows the prevalence of the cytological diagnosis amongst the patients. The group of patient with the highest frequency of diagnosis is C2 (benign) making up 41.3%(402) of the cases, followed by C5 which constitute 28.2%(275), C3 constituting 13.8%(134), C4 comprising 13.0%(127) and then C1 constituting 3.7%(36) of the total specimen.

Table 2: Mean Age For Each Diagnosis

DIAGNOSIS	MEAN AGE (YEARS)
C1	38.2
C2	33.9
C3	45.3
C4	46.7
C5	43.1

C1= Unsatisfactory, C2 = Benign, C3 = Suspicious, probably benign, C4 = Suspicious probably malignant, C5 = Malignant The table 2 above shows the mean age of each cytological diagnosis amongst the patients. The group of patient with the highest mean age is C4 (46.7yrs), followed by C3 (45.3yrs), C5 (43.1yrs), C1 (38.2yrs) and then C2 (33.9yrs)

IV. Discussion

Breast cancer is the commonest malignancy in females and fine needle aspiration of the breast is a procedure that helps in the rapid diagnosis of malignant and benign breast lesions before histology is done.

In this study, 974 female breast FNACs were analysed. This represented 84% of the total FNACs done during the study period (January, 2012 to December, 2016). This definitely shows that the majority of FNAC done in this centre is for the breast. The age range of the patients is between 11 and 79 years, which is similar to the findings by Yu et al in 2012.⁹ The mean age of the patients is 41.4 years which is similar to a finding by Shah et al in 1998 where the mean age of patients who had FNAC of the breast for a breast lump was 42 years.¹⁰ These findings are also similar to the findings by Siddig et al with an age range of 15 to 78 years and a mean age of 44 years.¹¹ The age group with the highest proportion of cases is 21 to 30 years constituting 22.4% of all the samples analyzed during the study period. This is followed by the age group 51 to 60 years which makes up 17.7% of the cases and then 41 to 50 years which made up 17.1% of the total sample. The age group with the least proportion of cases is 71 to 80 years. These may be attributed to the relative corresponding peak of both benign and malignant breast tumour as demonstrated in the study done by Anderson et al.¹² The distribution of the breast lesions is represented in figure 1. In this study, there were slightly more right sided breast lumps compared to left sided ones with a prevalence of 48.9% and 46.6% respectively, while 4.5% of the breast lumps were bilateral. This finding is slightly different from that by Sankaye et al in India which shows an almost equal prevalence of left and right sided breast lumps.¹³ However, this is in contrast to the findings by Reddy et al and Meena et al which show a slightly higher proportion of left breast lumps than the right.^{14, 15} Figure 2 shows the prevalence of each FNAC diagnosis. Benign (C2) has the highest prevalence of 41.3% which is consistent with the findings in the study done by Siddig et al with a prevalence of 82.1%, Yeoh et al with a prevalence of 73.1%, Park et al with a prevalence of 57.4%, Rocha et al with a prevalence of 76%, Dominguez et al with a prevalence of 77.8% and Sankaye et al in India with a prevalence of 58.2%, though these studies had a higher prevalence of C2.^{16,17,18,19} The diagnosis with the second highest prevalence is C5 with a prevalence of 28.2%. This is similar to the findings by Siddig et al with a prevalence of 15.8%, Vala et al with a prevalence of 28.5%, Mohammed et al (24.2%), Sankaye et al (28.9%) and Park et al (12.7%).^{11,13, 17, 20,21} The diagnosis third highest prevalence is C3 with prevalence of 13.8% and this is followed by C4 with a prevalence of 13.0%. The unsatisfactory sample, C1 had the least prevalence (3.7%) of all the diagnosis which is slightly higher than the findings by Mohammed et al with a prevalence of 1.9% but lower than that by Park et al (25.3%) and Dominguez et al (10.15%).^{17,19,21}

The table 2 show that malignant, C5 and suspicious for malignancy, C4 has the highest mean age of 43.1 and 46.65 years respectively. The mean age of the C2 diagnosis is 33.9 years this is expected since benign breast lesions are commoner in the younger age group. This may be explained by the fact that malignant breast lesions are more common in older females when compared to the younger females. The C3 has a mean age of 45.25 years.

V. Conclusion

Breast cancer is significant cause of morbidity and mortality in females being the most common cancer in females. The rapid diagnosis of a breast lump through an FNAC is of great help in making prompt decisions on patients' management. An accurate and precise FNAC reliably goes a long way in improving patient care.

References

- [1]. Moore KL, Dalley AF. Clinically Oriented Anatomy. Lippincott Williams & Wilkins; 2006. p. 106–12.
- [2]. Stenberg SS. Histology for Pathologists, Lippincott-Raven, 2nd edition, 1997; Chapter 46: 900 - 902.
- [3]. McManus DT, Anderson NH. Fine needle aspiration cytology of the breast. *Curr Diagnostic Pathol.* 2001;7 (4):262–71.
- [4]. Wypij JM. Getting to the point: Indications for fine-needle aspiration of internal organs and bone. *Topics in Companion Animal Medicine.* 2011. p. 77–85.
- [5]. Westenend PJ, Jobse C. Evaluation of fine-needle aspiration cytology of breast masses in males. [Internet]. *Cancer.* 2002. p. 101–4. Available from: <http://www.ncbi.nlm.nih.gov/pubmed/11954020>
- [6]. Unit CE, Kingdom U. Ovarian cancer and body size: individual participant meta-analysis including 25,157 women with ovarian cancer from 47 epidemiological studies. *PLoS Med* [Internet]. 2012;9(4):e1001200. Available from: <http://www.pubmedcentral.nih.gov/articlerender.fcgi?artid=3317899&tool=pmcentrez&rendertype=abstract>
- [7]. Kocjan G. Fine needle aspiration cytology: Diagnostic principles and dilemmas. *Fine Needle Aspiration Cytology: Diagnostic Principles and Dilemmas.* 2006; 1-239.
- [8]. Irabor GI, Akpan D, Isiwele E.M, Omosoto AJ, Ebughe GA, Nnoli MA. Fine needle aspiration cytology of the breast, component of a triple test: A review. *Med. Res. Chron.*, 2017, 4 (5), 495-500.
- [9]. Ying-Hua Yu, Wie Wie and Jian-Lun Liu. Diagnostic value of fine-needle aspiration biopsy for breast mass: a systematic review and meta-analysis. *BMC Cancer* 2012; 12:41.
- [10]. Shan SH, Kayani N, Hussan SH, Soomro IN, Pervez S, Hussainy. Diagnostic Evaluation of Fine Needle Aspiration Cytology in the Management of Palpable Breast Lesions.
- [11]. Siddig EE, Siddig AE, Edri AMM, Fahal AH. Fine Needle Aspiration Cytology: A diagnostic tool for breast lesions in low resource areas. *ResearchGate.* Available from <https://www.researchgate.net/publication/301765409>. Accessed on the 24/09/2017.
- [12]. Anderson WF, Reiner AS, Matsuno RK, Pfeiffe RM. Shifting Breast Cancer Trends in the United States. *Journal of Clinical Oncology* 2007; 25(25): 3923-9.

- [13]. Sankaye SB, Dongre SD. Cytological study of palpable breast lumps presenting in an Indian rural setup. *Indian Journal of Medical and Paediatric Oncology: Official Journal of Indian Society of Medical & Paediatric Oncology*. 2014;35(2):159-164. doi:10.4103/0971-5851.138993.
- [14]. Meena SP, Hemrajani DK, Joshi N. A comparative and evaluative study of cytological and histological grading system profile in malignant neoplasm of breast — An important prognostic factor. *Indian J Pathol Microbiol*. 2006;49:199–202.
- [15]. Reddy DG, Reddy CRR. Carcinoma of the breast, its incidence and histological variants among South Indians. *Indian J Med Sci*. 1958;12:228–34
- [16]. Yeoh GP, Chan KW. Fine needle aspiration of breast masses: An analysis of 1533 cases in private practice. *Hong Kong Med J*. 1998;4:283–88.
- [17]. Park IA, Ham EK. Fine needle aspiration cytology of palpable breast lesions. Histologic subtype in false negative cases. *Acta Cytol*. 1997;41:1131–8.
- [18]. Rocha PD, Nadkarni NS, Menezes S. Fine needle aspiration biopsy of breast lesions and histopathologic correlation. *Acta Cytol*. 1997;41:705–12.
- [19]. Domínguez F, Riera JR, Tojo S, Junco P. Fine needle aspiration of breast masses. An analysis of 1,398 patients in a community hospital. *Acta Cytol*. 1997;41:341–7.
- [20]. Vala MT, Goswami A, Suri SK. Comparative study of cytological and histopathological finding in breast lesion. *IOSR- JDMS* 2014;13(7): 05 – 07.
- [21]. Mohammed AZ, Edino ST, Ochicha O, Alhassan SU. Value of fine needle aspiration biopsy in preoperative diagnosis of palpable breast lumps in resource-poor countries: A Nigerian experience. *Ann Afr Med*. 2005; 4:19–22.

Godstime I Irabor Analysis of Female Breast Fine Needle Aspiration Cytology.” *IOSR Journal of Dental and Medical Sciences (IOSR-JDMS)*, vol. 17, no. 1, 2018, pp. 01-05