

To Establish Normal Smile Pattern Using Smile Analysis In Ethnic Chhattisgarh Female Population.

Dr. Bhawana Chandraker, Dr. Amit Chandraker

Maitri College of Dentistry and Research Centre Anjora, Durg Chhattisgarh, Department of orthodontics and dentofacial orthopedics

Abstract: Esthetics has become the primary consideration for the patients seeking orthodontic treatment. Orthodontics, the photographic record is an essential tool for diagnosis, pre, mid and post treatment assessment & communication. It is necessary for a clinician to have good knowledge about photographic armamentarium and skills by following some standard guidelines of lighting, composition, orientation, retraction and mirror use for representation of extra-oral and intra-oral structures with greater details. This study was conducted to evaluate common and normal smile patterns in Chhattisgarh females by using smile analysis. The study was conducted in 100 Chhattisgarh females with an age group of 15-35 years by using Adobe Photoshop 7 software. The following parameters of smile were noted in all the subjects: Position of upper lip while smiling, alignment of upper incisal edge to lower lip, Tooth-lower lip position. The present study will provide baseline data of an esthetic smile in Chhattisgarh females. The baseline data may serve as a guideline for restoration or enhancement of esthetics for the anterior component of the dentition.

Keywords: Esthetics, Adobe Photoshop, smile analysis

Date of Submission: 11-01-2018

Date of acceptance: 29-01-2018

I. Introduction

Our face determines the physical and dental attractiveness. Smile is one of the most important expressions contributing to facial attractiveness. An attractive or pleasing smile enhances the acceptance of an individual in the society by improving interpersonal relationships. In recent years, esthetics has become the primary consideration for patients seeking orthodontic treatment. Although ideal occlusion should be the primary functional goal of orthodontics, the esthetic outcome is also critical for patient satisfaction and therefore essential to the overall treatment objectives. Hence, orthodontic treatment must incorporate various esthetic elements of smile to achieve desirable results. With patients becoming increasingly conscious of a beautiful smile, smile esthetics has become the primary objective of orthodontic treatment. Modern orthodontics deals not only with the traditional dental and skeletal aspects, but also with the face as a first priority. The most important esthetic goal in orthodontics is to achieve a balanced smile, which can be best described as an appropriate positioning of teeth and gingival scaffold within the dynamic display zone.¹⁹ The smile is one of the most important facial expressions and is essential in expressing emotions. The subject of smile and facial attractiveness as they relate to communication and expression of emotion is of great interest to the orthodontist. An attractive or pleasing smile enhances the acceptance of an individual in the society by improving the interpersonal relationships. The importance of beauty and attractiveness in today's society has been well established. Physically attractive people are perceived to be more kind, sensitive, interesting, strong, poised, modest, sociable, outgoing, exciting and responsive. The reemergence of the soft-tissue paradigm in clinical orthodontics has made smile analysis, a key element in diagnosis and treatment planning along with cephalometry and study models. Much attention is given in clinical examination to the display zone of smile, which is determined by intercommissural width, interlabial gap, smile index, display of gingiva, smile arc. Analyzing the smile and obtaining averages for various smile components give an idea about a standard of normalcy to serve as a guideline for the creation of an esthetic smile. Therefore, smile measurement and establishment of different smile components that help in the establishment of a beautiful smile.⁴⁵

II. Material and Methods

The sample for the present study included 100 subjects, which consisted of 100 female subjects. The study was to evaluate normal smile in Chhattisgarh females in the age group of 15-35 years. The sample was screened from the general OPD of Maitri Dental College, Anjora, Durg as well as from students of Maitri Dental College. Camps were set up in Maitri Nursing College and students diagnosed with orthodontic problems and various other alignments were called to the OPDs for treatment.

Inclusion criteria:-

To Establish Normal Smile Pattern Using Smile Analysis In Ethnic Chhattisgarh Female Population.

- a. They were ethnic Chhattisgarhi females.
- b. The age group were 15-35years.
- c. The eruption of last molar were ignored in the subjects as its eruption is variable and is not a dependable

Exclusion criteria:-

- a. Subjects with deformity criteria , injury ,trauma, malformation ,surgical scar and congenital abnormalities of the lips , and palate are excluded.
 - b. Subjects who are from Chhattisgarh were included and other places were e excluded.
- The photographs were clicked with the digital camera with high resolution. The following parameters of smile were established-

- 1.Position of upper lip while smiling depending on the extent and exposure of maxillary anterior teeth and gingival mucosa , will be categorized as one of the following three types:- High smile, Average smile, Low smile.
- 2.Smile line according to the alignment of upper incisal edge to lower lip, the smile line will be categorized depending on the alignment of upper incisal edge to lower lip: convex smile line, straight smile line . concave smile line .
3. Position of incisal curve relative to touching the lower lip:-The position of contact between the lower lip and incisal edge will be studied under:- Non-contact position , Contact position, Covered position .

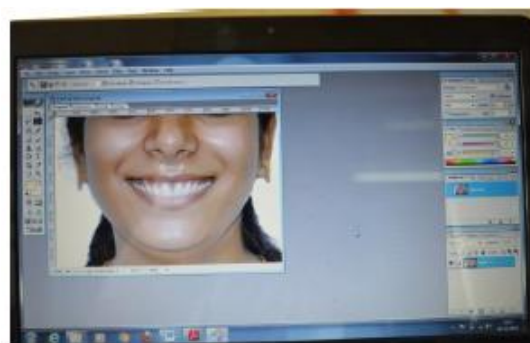Natural Head Position - In order to assess smile proportions patient must be examined in natural head position .Natural head position is a standardized and reproducible position of the head in space when the subject is focusing on a distant point at eye level. In natural head position the visual axis is horizontal. This allows an extra cranial vertical and a horizontal Perpendicular to that vertical to be used as references lines for facial aesthetic analysis. The procedure to obtain a clinical facial photograph in natural head position is with the subject standing upright and looking straight ahead into the image of his/her own eyes in a small mirror located at a distance at the level of the eyes.

Smile Capture Method

A Nikon video camera (3200D) is set on a tripod 4 feet away from the standing subject. The subjects were instructed to hold their head in natural head position by looking straight into an imaginary mirror. The camera lens was adjusted parallel to the apparent occlusal plane and the camera focused only on frontal smile face to capture the smile while protecting persons identity. The focal distance of all the photos was also standardized by fixing the focus in the beginning of the procedure in such way that there was a fixed distance between the camera and the face in all the pictures ,and between the camera and the volunteers' smile.



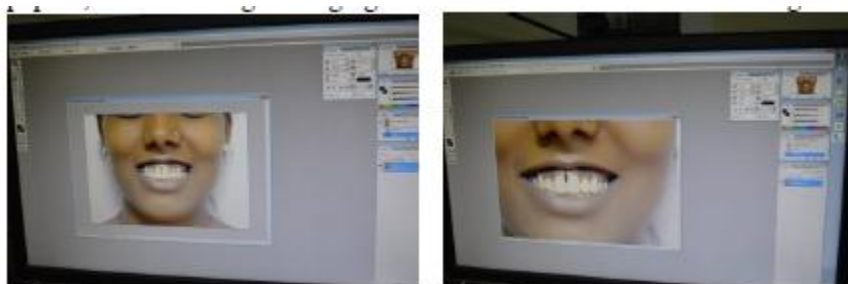
Standardization of image The photographs was cropped nose to chin and then transferred to Adobe photoshop 7 then evaluate criteria.Camera settings auto mode without ring flesh Focus 3.5 and shuuter speed 1/60 with 35-24 zoom. Settings are same for all photographs.



To Establish Normal Smile Pattern Using Smile Analysis In Ethnic Chhattisgarh Female Population.

Position of upper lip while smiling- Depending on the extent of exposure of maxillary anterior teeth, interdental papilla, gingival and mucosa during smile, the smiles were categorized as one of the following three types-

High smile (Mucosa smile): Full exposure of labial surface of teeth, interdental papilla, free marginal gingiva and labial mucosa during smile.



Average smile (Papilla smile/ gingival smile): An about 75% to 100% exposure of the maxillary anterior teeth and the interproximal gingiva.

Low smile (Tooth smile): Exposure of less than 75% of the anterior teeth. Failure to expose the upper anterior teeth gives a negative smile.

Alignment of upper incisal edge to lower lip –

There should be harmony between the curvatures of the incisal edge of anterior maxillary teeth with the curvature of the upper edge of the lower lip during voluntary smiling. This relationship between the incisal edges of canines and maxillary incisors with the lower lip is called the smile arch. Generally three types of smile lines are observed, the convex, straight and concave. All these smile lines were categorized depending on the alignment of upper incisal edge to lower lip.

- i) **Convex smile line:**-when the incisal margin of the maxillary central incisors appears below the canine cusps.(fig.1)
- ii) **Straight smile line:**-when the incisal curve is not there, all the maxillary incisors and canine are in a straight line.(fig.2)
- iii) **Concave smile line:**- when the canine cusps appear more occlusal than maxillary central incisor tip margin.(fig .3)



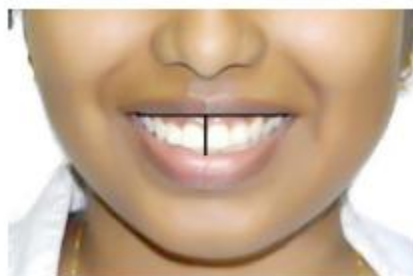Position of incisal curve relative to touching the lower lip:- The position of contact between the lower lip and incisal edge was noted. Maxillary teeth may remain apart (non-contact position)(occasionally touch the lower lip (contact position) or else be covered by the lip (covered position).

Smile mesh



Ackerman et al. developed Smile mesh, computer software to analyze photographs of posed smiles and test the reproducibility and reliability of the smile. Three smile images of the patient are taken and the software measures 15 attributes of the smile such as the upper lip drape, maxillary incisor display, interlabial gap, buccal corridor ratio, maxillary midline offset, and intercommissure width in the frontal plane direct biometric measurement static records include photographs, radiographs, and study casts. Digital photography captures the facial images like frontal at rest, frontal smile, oblique facial smile (for evaluation of occlusal plane, palatal cant, overjet etc.), close-up oblique smile (for assessment of crown height, gingival architecture), and profile smile.

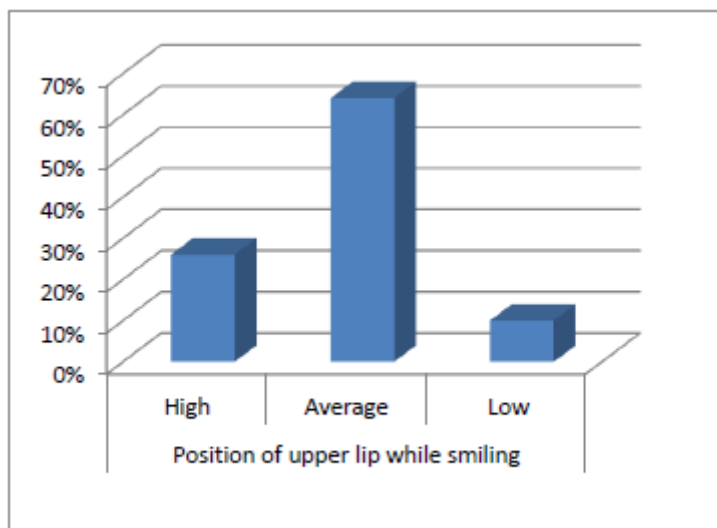
Smile index- To visualize and quantify the frontal smile ,Ackerman and Ackerman developed a ratio called smile index that describes the area framed by the vermilion border of lips during the social smile. Smile index is determined by dividing the intercommissure width by the interlabial gap during smile.



III. Result

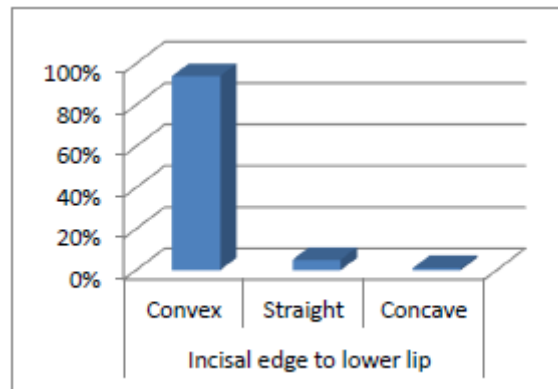
1. Average incidence of exposure of labial surface of teeth , interdental papilla , free marginal gingiva and labial mucosa during smile is maximum in Chhattisgarh Females. More females have average smile , than ,high and low smile.

| Position of upper lip while smiling | High | Average | Low |
|-------------------------------------|------|---------|-----|
| Percentage | 26% | 64% | 10% |



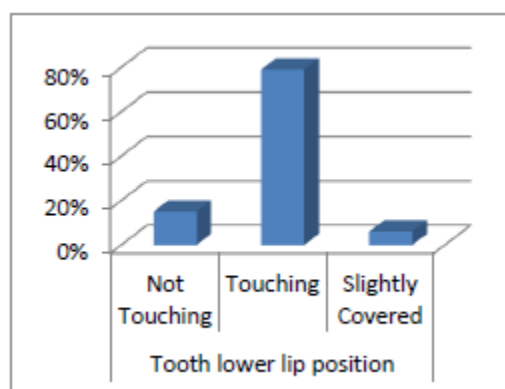
2.The incisal curvature of the maxillary anterior teeth parallel to the inner curvature of the lower lip is maximum. Convex smile line is maximum in chhattisgarh females then straight and Concave .

| Position of incisal edge to lower lip | Convex | Straight | Concave |
|---------------------------------------|--------|----------|---------|
| Percentage | 94% | 5% | 1% |



3. Incisal curvature are mostly touching the lower lip. Mildly not touching and slightly covered. More females have touching position of incisal curve relative to touching the lower lip than not touching and slightly covered.

| Tooth lower lip position | Touching | Not touching | Slightly covered |
|--------------------------|----------|--------------|------------------|
| percentage | 79% | 15% | 6% |



IV. Discussion

This study was done in Chhattisgarh females by using smile analysis. Previous study similar to this study is done by Garg et al, Tjan et al, Zachrisson, and Yoon et al. The establishment of norms is important in orthodontic diagnosis and treatment planning. This study is done to provide following norms in Chhattisgarh females-

- a. Position of upper lip while smiling,
- b. Allignment of upper incisal edge,
- c. Tooth lower lip position while smiling in Chhattisgarh females.

a. Position of upper lip while smiling

Average position (64%) was found the most common in Chhattisgarh females then high (26%) and low (10%) position. Garg et al found 56% high position was most common in Haryanvi female.¹⁹ Our result is different due to regional and genetic difference. Tjan et al (73.71%), Zachrisson (69%), Yoon et al (45%) found the average position to be most common. Tjan et al⁵² and Zachrisson conducted study on American population where as Yoon et al¹⁹ studied in Korean population. Patnik and Goel (44.5%)¹⁹ and Kaur et al⁵¹ (65.5%) also found the average position to be most common in Punjabi population.¹⁹ Our study supports this. The result with study conducted by patnaik and Goel and Kaur et al could be explained on regional basis as both studied Punjabi population. Our study is same as Tjan et al., Yoon et al, Patnik and Goel et al. Our result is same as those studies. The smile line can be regarded as a determining factor in the evaluation of mouth esthetics. It is not uncommon for the conclusion of orthodontics treatment to be compromised by the smile line. Either high or low smiles can compromise the result. Sheldon Peck examine the nature of gingival smile line, a specific dentolabial configuration characterized by the exposure of maxillary anterior gingiva during the full smile.²⁰ The smile can be regarded as a determining factor in the evaluation of mouth esthetics. It is not uncommon for the conclusion of orthodontic treatment to be compromised by the smile line. Either high smile line or low smiles can compromise the result. They found high smile line is most common. Our study not support those study, because our result is different due to different type of method is used and due to regional and genetic differences. I have done this study only on 100 females, so further studies is done in future in Chhattisgarh population. Maurakamiet

al reported a higher percentage of gummy smile, high smile line that related to the younger age of subjects observed. Our result found higher percentage of average smile line. Peck et al found gummy smile is predominant in females.¹⁵ Our study result is different is due to regional and genetic basis. Tjan et al and Dong et al⁴⁵ both reported that most patients had average anterior smile height. Both study used static photographs.¹ Brisman evaluated the shape symmetry and proportions of drawings and photographs of maxillary central incisors.⁴⁷ Christopher Maulik and Ravindra Nanda reported 56.9% average smile height. They had used dynamic smile analysis. The difference between those study and our study is different method is used but result are same.¹ Ackerman et al. found flatter smile arc in orthodontically treated vs nontreated patients

b. Alignment of upper incisal edge to lower lip

This study shows the alignment of incisal edge to lower lip was convex (94%) is most common in Chhattisgarh Females, followed by straight (5%) and concave (1%). Convex alignment of upper incisal edge to lower lip is most common. This study result was similar to Garg et al, Tjan et al and Zachrisson and Yoon et al. They also found convex smile line. The ideal is for the curvature of incisal edges to be parallel to the lower lip. In order to achieve a pleasing effect, it is necessary that dental and labial structures be symmetrical.¹⁹ Tjan et al reported that most subjects had parallelism of maxillary incisal curve with the lower lip but there was statistically difference in the convex curve. According to Tjan et al only a minority of population had a straight incisal curvature, 5% found in our study and concave incisal curvature was practically non-existent in their study population. 1% is found in our study. Our result is comparable with this. The ideal is for the curvature of incisal edges to be parallel to the lower lip.¹⁹ Ackerman et al. found flatter smile arc in orthodontically treated vs nontreated patients. Christopher Maulik¹ found orthodontically treated patients showed a greater percentage of parallel smile arc compared with nontreated patients.¹ They also found flat smile arc commonly. We found convex smile arc. The different result found because different method is used and due to difference in population group. Ling-Zhi Liang et al validated an objective method for recording spontaneous smile process and to categorize the smile and upper lip curvature of Chinese Han nationality youth.¹⁵ They found that subjects with commissure smile displayed predominantly either upward or straight curvature of the upper lip contour and downward curvature of their upper lips in both cuspid and gummy type of smiles. This study was found more convex position of upper incisal edge to lower lip in Chhattisgarh females. They compare upper lip curvature to cuspid, commissural and gummy smile. Our comparison is different. Our study is done only the regional basis, therefore our result are different. Sercan Akyalcin found harmonious smile arc relationship and less gingival display during a smile are significantly associated with smile attractiveness in orthodontically treated patients¹⁸.

c. Tooth lower lip position while smiling

The present study reveals that the most common tooth lower lip position while smiling is touching (79%) followed by not touching (15%) and slightly covered (6%). These results were comparable to a study conducted in California population by Tjan et al. This situation can vary among individuals or even in the same person depending on mouth opening. The muscle contractions of the lower lip can also alter this relationship. The ideal is for the curvature of incisal edges to be parallel to the lower lip and the incisal edges slightly apart or softly touching the lip.¹⁹ This study result was similar to this. Developing standards of normalcy for guidelines for orthodontist to have better treatment result. Consideration of criteria of a smile obtained from this study in Chhattisgarh Females may serve as a guideline for enhancement of esthetics and cosmetic surgery.¹⁹ Patnaik and Goel and Kaur et al studied in North Indian population. They found teeth not touching lower lip while smiling. We found touching position of is most common in Chhattisgarh females. Our result is different due to difference in regional and genetic basis, in which we studied. Garg et al found 54% not touching position, 40% touching position, and 6% slightly covered position in Haryana females.¹⁹ Giullianare Panfiglio Soares et al found the relationship between the curve formed by the curved formed by the incisal line of anterior superior teeth and the curve of inferior lip. They found most of parallelism between incisal plane and the anterior superior line.⁴⁷ We also found most female has convex smile line. Which touching the lower lip. But they took two type of photographs smiling face and smile they used different type of method. Our study support those study. Pieter A. A.M. Vandergelt et al considered spontaneous smile and speech are valuable diagnostic criteria in addition to the posed social smile.¹⁷ We used posed and static smile for smile analysis in Chhattisgarh females.

V. Conclusion

Norms have been dynamically introduced for various components of the smile. We found that on smiling most subjects displayed average position of upper lip. Females show more convex smile arc and less concave smile arc and also female show more touching tooth lower lip position than not touching and slightly covered tooth lower lip position. The concept of the smile esthetics clearly impact on the facial and smile appearance can be quite dramatic. Smile analysis and smile design generally involve a compromise between two factors that are often contradictory:

- The esthetics desires of the patient and orthodontist and
- The patients anatomic and physiologic limitations.

This demands that we think some of our orthodontics mechanics and concepts of treatment to consistently built these factors into our diagnosis treatment planning and treatment regimens. This study involved 100 subject. The subjects were Chhattisgarh females. They had class I molar and class I occlusion. This study was conducted in an attempt to obtain norms for the various components of smile in Chhattisgarh females. We found that, on smiling:

- 64% Chhattisgarh females have average position of upper lip while smiling. The overall cervicoincisal length of maxillary incisor teeth are displayed. Gingiva does not show (except interproximal gingiva).
- 94% Chhattisgarh females have convex smile line. The incisal curvature of the maxillary anterior teeth parallels the inner curvature of the lower lip. They have consonant smile.
- 79% Chhattisgarh females have contact position of incisal curve relative to touching the lower lip and display the six anterior teeth and premolars. Consideration of the characteristics may be useful in improving the esthetic of restoration.

References

- [1]. Christopher Maulik and Ravindra Nanda .Dynamic smile analysis in young adults .Am J OrthodDentofacialOrthop 2007;132:307-15.
- [2]. VinodKrishnan ,SunishT.Daniel, Don Lazar, AbinAsok. Characteristics of posed smiles by using visual analog scale, smile arc, buccal corridor measures, and modified smile index. Am J OrthodDentofacial Orthop 2008;133:515-23.
- [3]. Theodore Moore, Karin A. Southard ,John S.Casko, Fang Qian and Thomas E. Southard. Buccal corridors and smile esthetics. Am J OrthodDentofacialOrthop 2005;127:208-13.
- [4]. Diana George, Prashanth Kamath, Arun Kumar BR, Rajat Scindhia, Raghuraj MB. Vertical Dimensional Change Analysis during Smile: A Survey Study. International Journal of Applied Dental Sciences 2015; 1(4): 152-155.
- [5]. Sanjay Manhar Parekh, Henry W. Fields, Michael Beck, Stephen Rosenstiel. Attractiveness of Variations in the Smile Arc and Buccal Corridor Space as Judged by Orthodontists and Laymen. Angle Orthod 2006;76:557-563.
- [6]. Hrushikesh Aphale, Sunil Kumar N, Prasad Gayake, Dipak Sahane, Harsha Mahajan. The Ideal Smile And Its Characteristics. JDPMS, Vol 1(1) Sep – Dec 2012.
- [7]. Vera Lúcia Cosendey1, Stephanie Drummond2, Jonas Capelli Junior. Capture, analysis and measurement of images of speech and smile dynamics. Dental Press J Orthod. 2012 Sept-Oct;17(5):151-6.
- [8]. David M .Sarver and Marc B. Ackerman .Dynamic smile visualization and quantification : part 1. Evolution of the concept and dynamic records for smile capture. Am J OrthodDentofacialOrthop 2003;124:4-12.
- [9]. David M. Sarver and Marc B. Ackerman. Dynamic smile visualization and quantification :Part 2. Smile analysis and treatment strategies. Am J OrthodDentofacialOrthop 2003;124:116-27.
- [10]. Marc Ackerman and James Ackerman. Smile analysis and Design in the digital era. JCO 2002 volume XXXVI number 4.
- [11]. Brian J Schabel, Lorenzo Franchi , Tiziano Baccetti and James A. McNamara. Subjective vs objective evaluations of smile esthetics. Am J OrthodDentofacialOrthop 2009;135:S72-9.
- [12]. Erdal Isikal, Serpil Hazar and Sercan Akyalcin. Smile esthetics : perception and comparison of treated and untreated smiles. Am J OrthodDentofacialOrthop 2006;129:8-16.
- [13]. Vicky V Tarantili , Demetrios J. Halazonetis and Meropi N . Spyropoulos. The spontaneous smile in dynamic motion. Am J OrthodDentofacialOrthop 2005;128:8-15.
- [14]. David M Sarver .The importance of incisor positioning in the esthetic smile : The smile arc. Am J OrthodDentofacialOrthop 2001 ;120:98-111.
- [15]. Ling-Zhi Liang, Wen-Jie Hu, Yang-Ling Zhang and Kwok -Hung Chung. Analysis of dynamic smile and upper lip curvature in young Chinese. International Journal of oral science 2013 (5) 49-53.
- [16]. Suraj Ganapati Durgekar, Nagaraj K, Vijay Naik. The ideal smile and its orthodontic implications. World J Orthod 2010;11:211-220.
- [17]. Pieter A.A.M. van der Geld , Paul Oosterveld, Marinus A.J. van Waas and Anne Marie Kuijpers-Jagtman. Digital videographic measurement of tooth display and lip position in smiling and speech: Reliability and clinical application. Am J OrthodDentofacialOrthop 2007;131:301.e1-301.e8.
- [18]. Sercan Akyalcin ; Leslie K Frels ; Jerry D. English ; Stephen Laman. Analysis of smile esthetics in American Board of Orthodontics patients. Angle Orthod .2014;84:486-491.
- [19]. Garg S, Rathee SK. Smile analysis in Haryana Females. IJMS July 2013;2(2). 20. Sheldon peck, Leena peck, and Matti Kataja. The gingival smile line. Angle orthodontist. Vol 62 No.2 1992.
- [20]. Bjorn Zachrisson. Esthetic Factors Involved in Anterior Tooth Display and the Smile: Vertical Dimension. JCO volume 32 : number 07 : pages (432-445) 1998.
- [21]. Chris D. Johnson , Donald J Burden and Michale .R Stevenson. The influence of dental to facial midline discrepancies on dental attractiveness ratings. European Journal of orthodontics .21(1999) 517-522.
- [22]. Jeff Morley and Jimmy Eubank. Macroesthetic element of smile design. JADA, Vol 132 , January 2001.
- [23]. Marc B. Ackerman, Colleen Brensinger, J. Richard Landis. An Evaluation of Dynamic Lip-Tooth Characteristics During Speech and Smile in Adolescents. Angle Orthod 2004;74:43-50.
- [24]. Luis A. Esper, ., Michyele C. Sbrana., Ingrid W.J. Ribeiro., Erick N. de Siqueira , Ana L.P.F. de Almeida. Esthetic Analysis of Gingival Components of Smile and Degree of Satisfaction in Individuals With Cleft Lip and Palate. Cleft Palate–Craniofacial Journal, July 2009, Vol. 46 No. 4.
- [25]. David C. Havens; James A. McNamara, Jr, Lauren M. Sigler, Tiziano Baccetti. The Role of the Posed Smile in Overall Facial Esthetics. Angle Orthod 2010;80:322-328.
- [26]. Hideki Ioi, Shunsuke Nakata and Amy L. Counts. Influence of gingival display on smile aesthetics in Japanese. European Journal of Orthodontics 32 (2010) 633-637.
- [27]. Andrea Fonseca Jardim da Motta, Margareth Maria Gomes de Souza, Ana Maria Bolognese, Clarice Júlia Guerra and José Nelson Mucha. Display of the incisors as functions of age and gender. Aust Orthod J 2010; 26: 27-32.
- [28]. Roy Sabri. The Eight Components of a Balanced Smile. JCO 2005. Volume XXXIX number 3.

To Establish Normal Smile Pattern Using Smile Analysis In Ethnic Chhattisgarh Female Population.

- [29]. VarunPratap Singh, J.N. Sharma. Principles of Smile Analysis in Orthodontics- A Clinical Overview. Health Renaissance, January-April 2011; Vol 9 (No.1);35-40.
- [30]. Larissa Suzuki, André Wilson Machado, Marcos Alan Vieira Bittencourt. An evaluation of the influence of gingival display level in the smile esthetics. Dental Press J Orthod 37.e1 2011 Sept-Oct;16(5):37.e1-10.
- [31]. Mark.NHochman, Stephen J.Chu, Dennis P. Tarnow. Maxillary anterior papilla display during smiling.A clinical study of the interdental smile line.International journal of periodontics and restorative dentistry. Volume 32 No.4 2012.
- [32]. Phillip Roe, KitichiRungcharassaeng,Joseph Y.K.Kan, Rishi D. Patil, Wayne V.Campagni,James S.Brudvik.The influence of upper lip length and lip mobility on maxillary incisal exposure. Am J Esthet Dent 2012;2:116–125.
- [33]. Luis Augusto Esper, MichyeleCristhianeSbrana,MerciaJusarra da silva, Guilherme Santos Moreira, and Ana Lucia pompeia , Fraga de Almeida. Esthetic composition of smile in individuals with Cleft lip ,Alveolas and palate: Visibility of the periodontium and the esthetics of smie.Plastic Surgery International Volume 2012 (2012), Article ID 563734, 7 pages.
- [34]. FahimehFarzen,Arezoo et al. Which has a Greater Influence on Smile Esthetics Perception: Teeth or Lips? Iran J Otorhinolaryngol. 2013 Oct; 25(73): 239–244
- [35]. Sohinderjit Singh, HemantGarg, Christy Ruchi Sharma, SaurabhDhiman ,DevashishSawai.Upper Lip Soft Tissue Changes And Gingival Display On Smiling: A Study Of Vertical Dimension. Indian Journal of Dental Sciences. March 2015, Issue:1, Vol.:7.
- [36]. Mohammad Alkhalaf and Rabab Al-Sabbagh. An Evaluation of Upper Lip Length and Thickness Changes on Smiling in Patients with Class I, Class II Div1, 2 of Malocclusion According to Angle's Classification.Journal of orthodontics and endodontics 2015 Vol1 No.2:16.
- [37]. GirishGalagali ,JagadeeshNaik, PrakashNidawani ,Sufiyan MK . Measurment of visible teeth surface area of the upper and lower anterior teeth during speech, using video Photographic method in young adults – A survey.Indo-European journal of orthodontics IEJDTR. 2015; 4(3): 294-296.
- [39]. NoshiSiddiqui; PradeepTandon; Alka Singh; JiteshHaryani. Dynamic smile evaluation in different skeletal patterns. Angle Orthodontist, Vol 00, No 00, 0000.
- [40]. Ke Zhang; Lan Huang; Lin Yang; Li Xu; ChaoranXue; Zichao Xiang; MengyuanZhao;Song Li; YuxingBai; Ding Bai. Effects of transverse relationships between maxillary arch, mouth, and face on smile esthetics. Angle Orthod. 2016;86:135–141.
- [41]. LuizaNayara Almeida LyraCorreia et al. Age-related changes in the Brazilianwoman's smile. Braz. Oral Res. 2016;30(1):e35.
- [42]. Shyam Desai, MadhurUpadhyay, and Ravindra Nanda. Dynamic smile analysis: Changes with age. Am J OrthodDentofacialOrthop 2009;136:310.e1-310.e10.
- [43]. ShvetaDuggal. The esthetic zone of Smile . Virtual Journal of Orthodontics 1996.\
- [44]. Pieter Van der Geld; Paul Oosterveld; Guus Van Heck; Anne Marie Kuijpers-agtman. Smile Attractiveness. Angle Orthodontist, Vol 77, No 5, 2007.
- [45]. HarshikParekh,Dolly Patel ,Falguni Mehta , Niyanta Joshi, Amit Bhattacharya. "Smile – A Diagnostic Tool: Photographic analysis in Adult Gujarati Population". IOSR Journal of Dental and Medical Sciences (IOSR-JDMS). Volume 12, Issue 4 (Nov.- Dec. 2013), PP 39-
- [46]. Michael Mah, Wei Chuan Tan, SimHengOng, YiongHuak Chan and Kelvin Foong. Three-dimensional analysis of the change in the curvature of the smiling line following orthodontic treatment in incisor class II division 1 malocclusion. European Journal of Orthodontics. June 14, 2013.
- [47]. GiullianaPanfiglioSoares,ThiagoAssunçãoValentino,DéboraAlvesNunesLeiteLima,LuisAlexandreMaffeiSartiniPaulilloFrederico Augusto Peixoto Silva ,José Roberto Lovadino. Esthetic analysis of the smile. Braz J Oral Sci. April-June 2007 - Vol. 6 - Number 21.
- [48]. Dustin RodenJohnson,RonaldGallerano and JerylEnglish.The effects of buccal corridor spaces and arch form on smile esthetics.Am J Orthod 2005;127:343-50.
- [49]. Ravindra Nanda. Biomechanics and Esthetic Strategies in clinical orthodontics .3rd Edition.
- [50]. Proffit W R. Contemporary Orthodontics. 5th Edition.
- [51]. GagandeepKaur ,PatnaikV.V.Gopichand, SubashKaushal.The anatomy of smile.Journal of Medical College Chandigarh, 2011. Volume 1 . No.1.
- [52]. TjanAHL,DentDr,MillarGD,TheJGP:Some esthetic Factors of smile. J prosthet Dent.1984;51:24-8.

Dr.BhawanaChandraker "To Establish Normal Smile Pattern Using Smile Analysis In Ethnic Chhattisgarh Female Population."IOSR Journal of Dental and Medical Sciences (IOSR-JDMS), vol. 17, no. 1, 2018, pp. 49-56.