

## Perianal Fistula Evaluation on Pelvic Mri: Our Experience

\*Dr. Paresh Kumar Sukhani<sup>1</sup>, Dr.Sanyukta Gupta<sup>2\*</sup>

<sup>1</sup>MD Radiodiagnosis, Associate Professor, Department of Radiodiagnosis, Mahatma Gandhi Medical College, Jaipur, Rajasthan, India

<sup>2</sup>Final year Post-graduate Resident, Department of Radiodiagnosis, Mahatma Gandhi Medical College, Jaipur, Rajasthan, India.

\*Corresponding author: . Paresh Kumar Sukhani

### Abstract

**objective:** Perianal fistula is an important condition that causes substantial morbidity. It occurs in 10 of 100,000 persons and has a tendency to recur despite seemingly adequate surgery. This study was undertaken to assess the role of MRI in the detection and classification of Perianal Fistula and correlation of preoperative MRI findings with the findings on surgery.

**Materials And Methods:** This prospective study contained 40, MRI were performed and the results were ensured by surgical results, sensitivity, specificity and predictive values of MRIs were determined. **RESULTS:** 36 patients with perianal sepsis were included in this study, eight cases grade 1 (simple linear intersphincteric fistula), five cases grade 2 (intersphincteric fistula with abscess or secondary track), nine cases grade 3 (trans-sphincteric fistula), twelve cases grade 4 (trans-sphincteric fistula and two cases grade 5 (supralelevator and translevator disease one case for each).

Axial and coronal T2W fat-saturated images and T1W fat-sat Post-GD images were found to be most accurate in evaluation of extent of perianal fistula. **CONCLUSION:** By using MRI as the first line imaging modality in the evaluation of Perianal Fistula one can percept best possible surgical management resulting in prevention of residual/ recurrent disease.

**Keywords:** intersphincteric, Magnetic Resonance Imaging, Perianal fistula, supralelevator, translevator

Date of Submission: 12-12-2017

Date of acceptance: 13-01-2018

### I. Introduction

Fistula-in-ano is a chronic abnormal communication which runs outwards from the ano-rectal lumen to an external opening on the skin of the perineum or buttock<sup>[1]</sup>. A fistulous track has a central core of acute on chronic inflammatory tissue surrounded by chronically inflamed fibrous tissue<sup>[2]</sup>. While most patients present with discharge (65%) and local pain<sup>[3]</sup>, some may be asymptomatic. Most authorities believe that the infection of anal intersphincteric glands is the initiating event in fistula-in-ano, in a process known as the "cryptoglandular hypothesis"<sup>[4]</sup>. Perianal fistulae may also be associated with Crohn's disease, tuberculosis, hydradenitis suppurativa, trauma during childbirth, pelvic infection, pelvic malignancy, and radiation therapy<sup>[5]</sup>. Management of idiopathic perianal fistulas is primarily surgical and involves a fistulotomy or fistulectomy of the tracts, combined with drainage of associated sites of infection<sup>[6]</sup>. To maximize success, the surgeon must assess the relationship of the fistula to the sphincter complex to best preserve anal continence and to identify secondary tracts or abscesses, which, when untreated, are the primary source of recurrence<sup>[7]</sup>. In the past, various imaging modalities including fistulography, anal endosonography and computed tomography have been used in assessing perianal fistula. Fistulography is unreliable and difficult to interpret as the sphincter complex is not directly visualized. Anal endosonography too has proved inferior to expert clinical assessment as infection may not be distinguished from fibrosis and its insufficient depth of penetration which may result in failure to identify secondary ramifications. Computed tomography, performed with rectally and intravenously administered contrast media, also showed some early promise. However, similar attenuation values for the sphincters, levatorani, fibrotic fistulous tracks, and active fistulae make characterization of these structures difficult on CT<sup>[2,6,8]</sup>. The advantage of MR imaging of perianal fistulae is the inherent high soft tissue contrast resolution and multiplanar display of pelvic anatomy<sup>[9]</sup>.

### II. Normal Anatomy

The anal canal is a cylindrical structure surrounded by two muscular layers, the internal and external sphincters. The external anal sphincter (a striated muscle) is hypointense on T1W, T2W, and fat-suppressed T2W images, and is bordered laterally by the fat in the ischioanal fossa. It merges proximally with the puborectalis muscle, which then merges with the levator plate of the pelvic floor.

The internal sphincter (a smooth muscle) is hypointense on T1W and T2W TSE images and is relatively hyperintense on fat-suppressed T2W images. It shows enhancement on post-gadolinium T1W images<sup>[6]</sup>. The coronal images depict the levator ani muscle (levator plane), the identification of which is important to distinguish supralelevator from infralevator infections. The internal and external sphincters are separated by the intersphincteric space, which is composed of loose fat containing areolar tissue and is the plane of least resistance. Surrounding the anal canal, are two contiguous pyramidal fat-containing spaces known as the ischioanal space cranially and the ischioanal space caudally.

Perianal fistulae can be classified based on MR imaging findings for which we use the St James's University Hospital classification which is as follows<sup>[6]</sup>:

- Grade 0 – Normal appearance
- Grade 1 – Simple linear intersphincteric fistula
- Grade 2 – Intersphincteric fistula with intersphincteric abscess or secondary fistulous tract
- Grade 3 – Trans-sphincteric fistula
- Grade 4 – Trans-sphincteric fistula with abscess or secondary tract within ischioanal or ischioanal fossa
- Grade 5 – Supralelevator and translevator disease.

The aim of our study was to assess the role of MRI in the detection and classification of Perianal Fistula and correlation of preoperative MRI findings with the findings on surgery Our experience in MRI evaluation of perianal fistulas

### III. Material And Methods

Fifty patients with clinical suspicion of Perianal fistula were referred to Radiology department from surgical outpatient department, Emergency room and indoor departments during July 2017 and September 2017. MRI was performed in all patients. 14 patients were excluded from the study with no evidence of pathology. MRI of Perianal region was performed in 36 patients with significant results. MRI was performed in our department on 1.5 T Ge Mri And 3t Philips Mri. 2.1 MRI Technique: The anal canal is tilted forward from the vertical by approximately 45° in the sagittal plane; thus, straight axial and coronal images will not allow correct evaluation of the source and the fistulous track. Therefore, it is necessary to obtain oblique axial and coronal images oriented orthogonal and parallel to the anal canal, respectively. In our institution we initially perform a sagittal T2W FSE sequence as a reference images it shows us the correct orientation of anal canal then we take Coronal oblique images parallel to the walls of the anal canal, then we perform Axial oblique images perpendicular to the coronal planes. 2.2 MRI Protocol (A) Plain / Non-contrast sequences 1. T1W FSE (Axial oblique and Coronal Oblique). 2. T2W FSE FS Axial oblique and coronal oblique. 3. Axial oblique and Coronal oblique STIR (B) Post-contrast sequences- T1W FSE FS with Omniscan Axial oblique and coronal oblique. Contrast agent: 0.1 mmol/kg of Omniscan (Gadodiamide) as contrast agent by manual injection.

MRI scans were interpreted in the light of following key features:

1. Primary fistulous tract & Secondary tracts / ramifications
2. Horse shoe feature / component
3. Abscess
4. Supra-levator extension
5. Internal opening visualized or not Site of the internal opening was decided with reference to the anal clock in the axial plane (6 o'clock posterior 12 o'clock anterior).

### IV. Results

Out of 50 patients in our study, 14 (28%) patients had normal study with no MRI evidences of fistula formation. Rest of 36 cases revealed perianal fistulas which were evaluated for the site of the primary tract and its ramifications, the presence and absence of external sphincter involvement, and the location of the internal openings. Out of 36 cases with perianal fistula 8 (22%) were females and 28 (78%) were male subjects. Youngest patient included in our study was 20 years of age and oldest 65 years of age. Patient's data was evaluated regarding presenting complaints which showed, 20 cases presented with pain, 2 cases with painless perianal swelling, while 6 cases had a history of discharge. Eight patients had more than one of the abovementioned complaints. Three patients had a perianal fistula associated with Crohn's disease and one of them showed horseshoe abscess formation. Two patients showed osteitis coccyx and sacrum. One patient came with associated urogenital disease and one with anovaginal fistula. Out of total 36 patients, 22 had multiple fistulae and abscess formation. Of the remaining, 14 patients had a single fistula. Ten patients had undergone one or more previous fistula surgeries and presented with recurrence. All of them wither underwent surgery without imaging or with conventional fistulogram. 36 patients with perianal sepsis were included in this study, eight cases grade 1 (simple linear intersphincteric fistula), five cases grade 2 (intersphincteric fistula with abscess or secondary

track), nine cases grade 3 (trans-sphincteric fistula), twelve cases grade 4 (trans-sphincteric fistula and two cases grade 5 (supralelevator and translevator disease one case for each).

**4.Tables Table 1. No. of cases of each grade at MRI and surgical results.**

Type of fistula	MR findings	Surgical findings
Grade 1: Simple Linear Inter-sphincteric Fistula	8	8
Grade 2: Intersphincteric Fistula with Abscess or Secondary Track	5	3
Grade 3: Trans-sphincteric Fistula	9	9
Grade 4: Trans-sphincteric Fistula with	Abscess	5
	Secondary Track within the Ischiorectal Fossa.	3
	Both	3
Grade 5:	Supralelevator	1
	Translevator	1
Total	36	32

**Table 2.** The sensitivity, specificity, positive and negative predictive values and overall accuracy of MRI in detection of perianal fistula.

	Sensitivity (%)	Specificity (%)	PPV (%)	NPV (%)
MRI	100	77.8	88.8	100

**V. Figures And Legends**

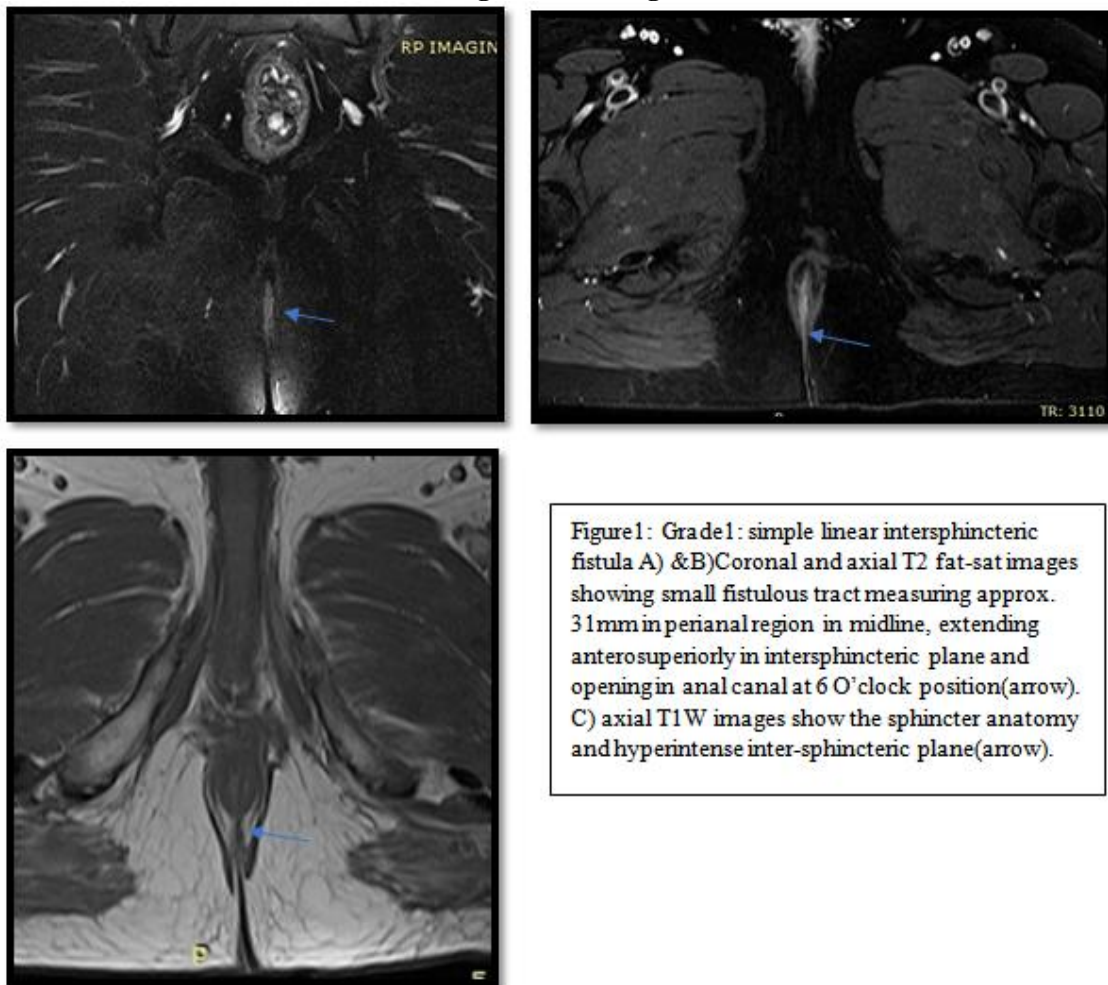
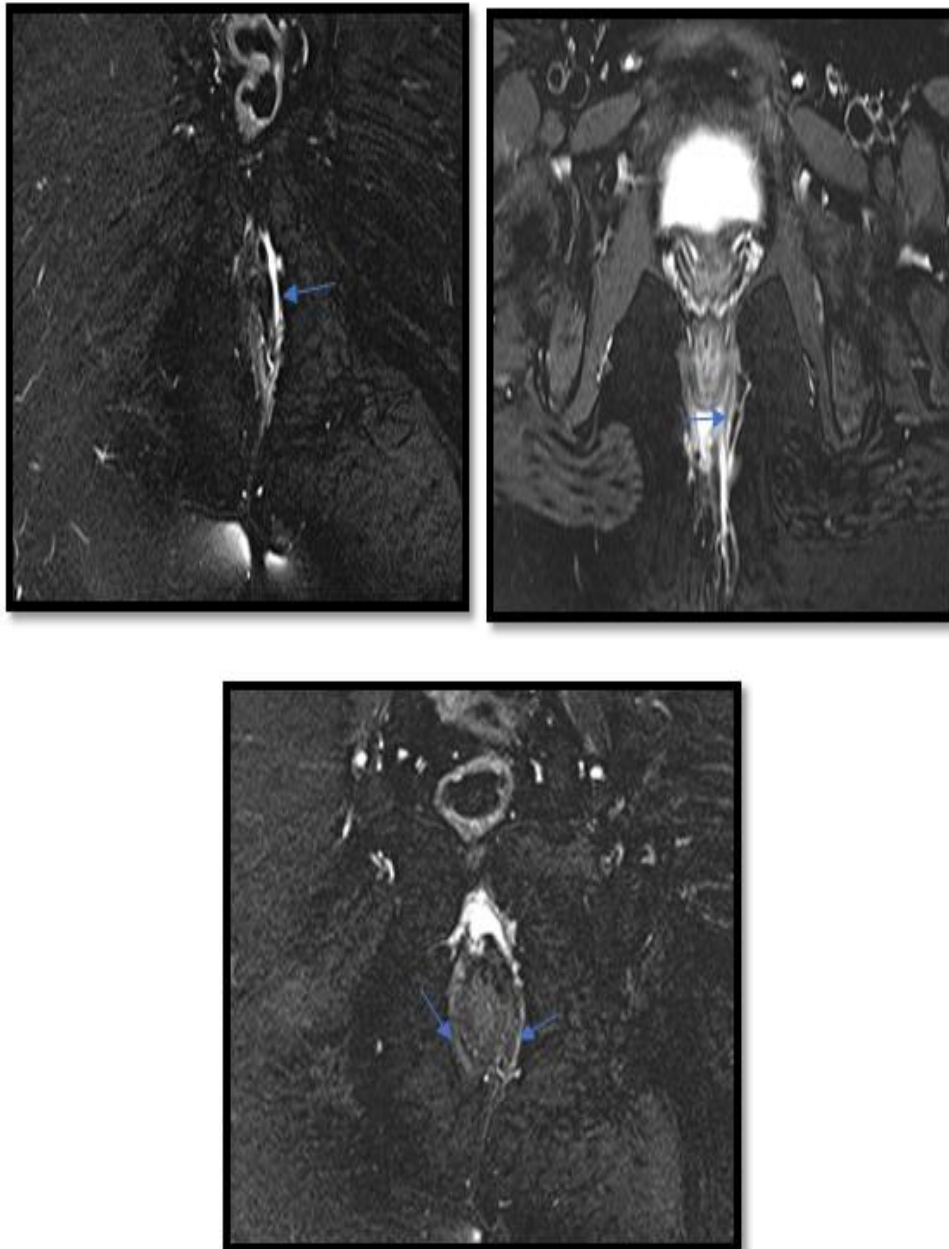
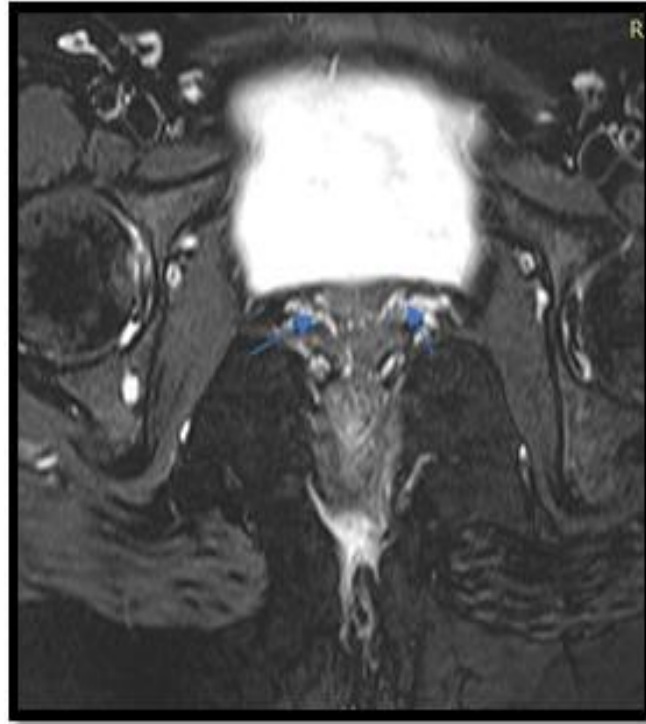

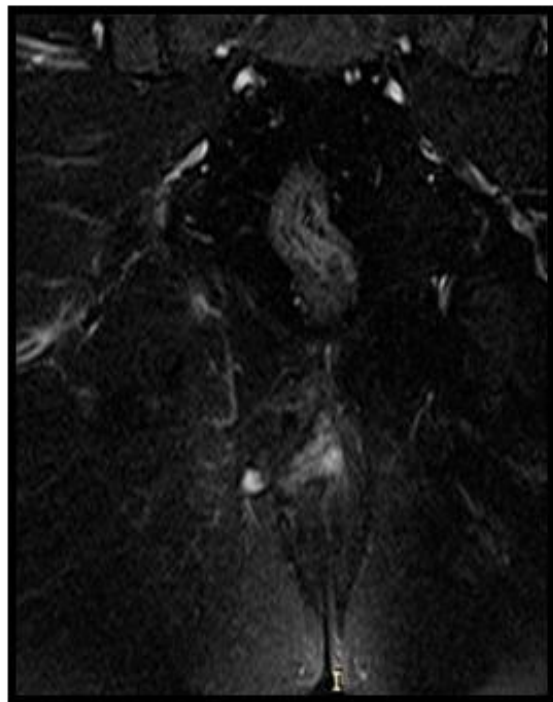
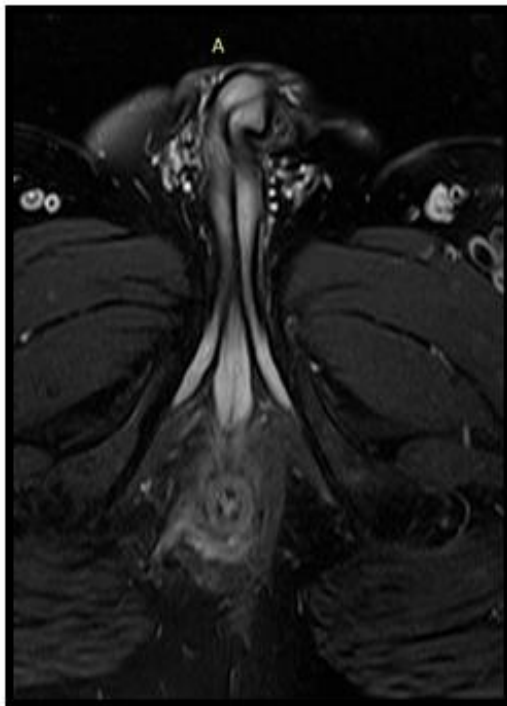
Figure 1: Grade 1: simple linear intersphincteric fistula A) & B) Coronal and axial T2 fat-sat images showing small fistulous tract measuring approx. 31mm in perianal region in midline, extending anterosuperiorly in intersphincteric plane and opening in anal canal at 6 O'clock position (arrow). C) axial T1W images show the sphincter anatomy and hyperintense inter-sphincteric plane (arrow).

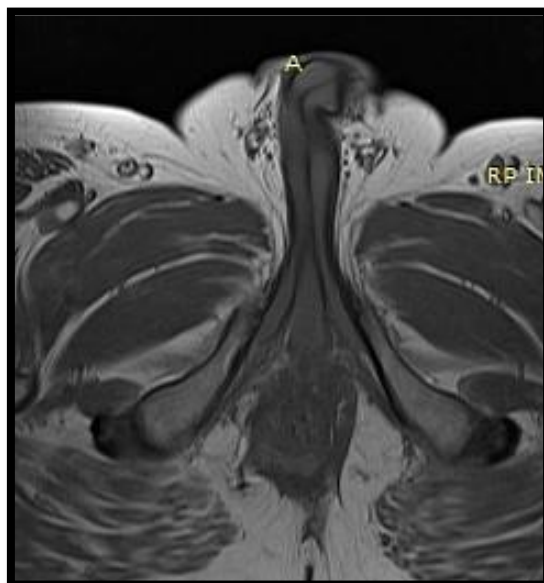


**Figure2:** Grade 2 intersphincteric fistula with secondary tracts, collection and horse-shoe tracts: A) Coronal & B) Axial T2W fat-sat images show long fistulous tract is in left gluteal perianal region, runs anterosuperiorly and on left lateral aspects of anal canal and is seen to open into small collection (arrow), located in posterior aspects of anal canal.

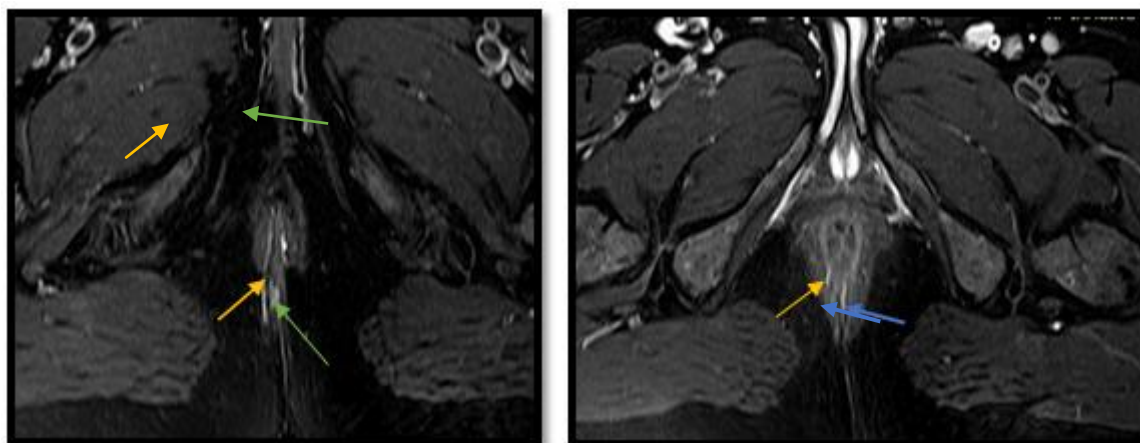


C) Coronal & D) Axial T2W fat-sat images show small secondary tracts are seen arising from this intersphincteric collection on both, left and right sides (horseshoe collection).





**Figure3:** Grade3:Trans-sphinctericfistula.A) Axial &B)coronal T2W fat-sat images show Fistulous tract, measuring approx. 17mm is seen in right gluteal region extending anterosuperiorly and medially coursing through the right ischioanal fossa and piercing external sphincter on right side.C) T1W axial images show the anatomy clearly in order to classify fistula correctly.



**Figure4:** Grade 4: Trans-sphincteric fistula with multiple secondary tracts & ramifications :A)&B) Axial T2W fat-sat images show. On right side – sinus tract(green arrow) is seen in right perianal gluteal region, it, pierces anal sphincters with internal opening at approx. 7 O'clock position. Branching tract(orange arrow) is seen from above tract, it traverses superiorly, right laterally in sphincter plane and open into anal canal lumen at approx. 8 O'clock position about 17mm cranial to above mentioned internal opening. On left side, sinus tract(blue arrow) is seen in left perianal gluteal region posteriorly, this traverses anteriorly, pierces anal sphincters with internal opening just above anal verge at 5 O'clock position. B) Shows internal opening in anal canal.C) Coronal T2W shows the same findings.



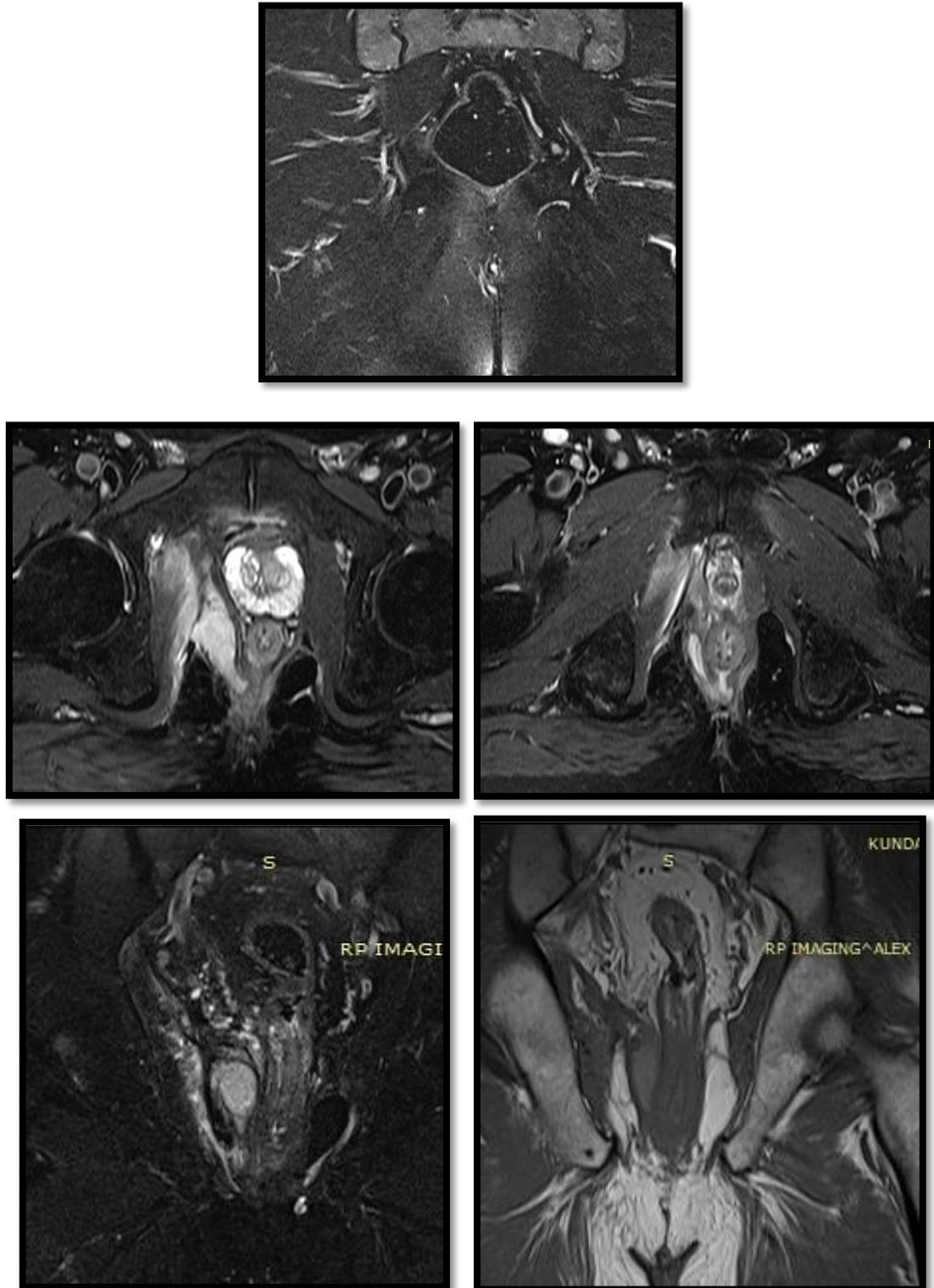


Figure5: Grade5: Supralelevator disease. A)&B)Axial T2W fat-sat images reveals elongated collection, in right ischioirectal fossa involving puborectalis muscle on right side, extending superolaterally towards right side of pelvis along right lateral pelvic wall involving obturator internus muscle which shows oedema and inflammatory stranding. Right levatorani muscle is also thickened and shows inflammatory stranding. B) shows internal opening at 6 O'clock position almost at anorectal junction. C) Coronal T2Wfat-sat &D) Coronal T1W images show translevator extension clearly.

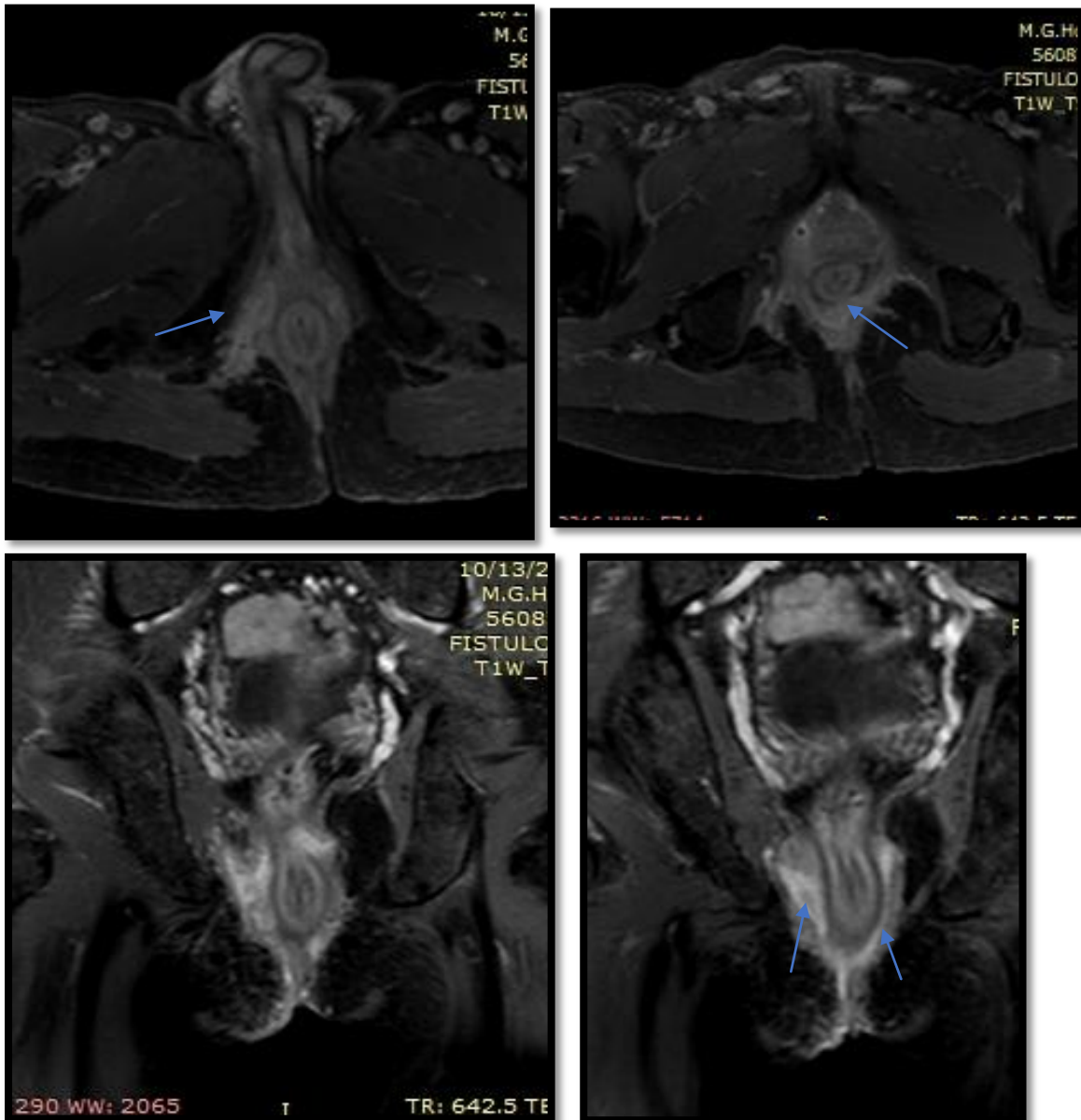


Figure 6: A) and B) Axial post-contrast images in a patient showing enhancing tract crossing levatorani and traversing intersphincteric plane to reach left side. C) &D) coronal post-GD images showing horseshoe collection.

## VI. Discussion

Halligan et al.<sup>[6]</sup>, stated that the disease predominantly strikes young adults, and men are more commonly affected. This was in agreement with our study where the majority of patients were in age group of 25-50years. Mullen et al.,<sup>[10]</sup> who study the indications and contribution of MR imaging of fistula in ano to surgical assessment, they studied on 40 cases and stated that MRI was considered helpful in 34 cases (85%) of all cases, while in our study MRI is helpful in -- cases. This can be contributed to inherent high soft tissue contrast resolution and the multi-planar display of anatomy by MRI modality<sup>[6,11]</sup>.

Rafal et al found that MRI adequately showed the extent of perianal fistulae as well as extra tracts not evident on physical examination<sup>1</sup> and EUA. It also distinguished actively inflamed and fibrotic fistulous tracts noninvasively without exposing the patient to ionizing radiation<sup>[12]</sup>. Beets-Tan et al reported upto 100% sensitivity for detecting the primary tract, 96% sensitivity for abscesses, 100% sensitivity for horseshoe extensions, and 96% sensitivity for internal openings<sup>[13]</sup>. The results of our study also depict the same. Charles



et al.<sup>[14]</sup> stated that T2W images (TSE and fat-suppressed) provide a good contrast between the hyperintense fluid in the tract and the hypointense fibrous wall of the fistula, while providing a good delineation of the layers of the anal sphincter.. This agrees with our study, axial T2W fat-suppressed images were the most useful for locating the fistulous tract. It is important to find the exact site of internal opening otherwise there will be inadequate treatment and rate of recurrence of fistula would be high. In our study, the most common location of internal opening was at 6 O'clock position, which is comparable to many studies.<sup>[15]</sup> In our study MRI detected internal opening in 47 out of 48 patients. Our results are nearly in accordance with the statistical results of Villa C et al<sup>[16]</sup> that MRI is highly accurate for depiction of both the primary tract (sensitivity, 100%; specificity, 86%) and abscesses (sensitivity, 96%; specificity, 97%).

## VII. Conclusion

Pelvic MRI offers the ability to obtain high-spatial-resolution images and multiplanar capabilities, offering exquisite details of the pelvis, making it the preferable imaging modality for detection and assessment of perianal fistulas.

## References

- [1]. Bailey H, Love M. The anus and anal canal. In: Williams NS, Bulstrode CJ, O'Connell PR, editors. Bailey and Love's Short practice of surgery. 25<sup>th</sup> ed. London: Edward Arnold (publishers) Ltd; 2008. p. 1262.
- [2]. Bartram C, Buchanan G. Imaging anal fistula. *Radiol Clin N Am* 2003;41:443-57.
- [3]. Practice parameters for treatment of fistula-in-ano: supporting documentation. The Standards Practice Task Force. The American Society of Colon and Rectal Surgeons. *Dis Colon Rectum* 1996;39:1363-72.
- [4]. Parks AG. Pathogenesis and treatment of fistula-in-ano. *Br Med J* 1961;5224:463-69.
- [5]. Hutan M, Hutan M Jr, Satko M, Dimov A. Significance of MRI in the treatment of perianal fistula. *Bratisl Lek Listy* 2009;110:162-5.
- [6]. Halligan S, Stoker J. Imaging of fistula in ano. *Radiology* 2006;239:18-33
- [7]. Jordán J, Roig JV, García-Armengol J, García-Granero E, Solana A, Lledó S. Risk factors for recurrence and incontinence after anal fistula surgery. *Colorectal Dis* 2010; 12:254-260
- [8]. Morris J, Spencer JA, Ambrose NS. MR imaging classification of perianal fistulas and its implications for patient management. *Radiographics* 2000;20:623-35.
- [9]. Khera PS, Badawi HA, Afifi AH. MRI in perianal fistulae. *Indian J Radiol Imaging* 2010;20:53-57.
- [10]. R. Mullen, S. Deveraj, S.A. Suttie, A.G. Matthews, S. Yalamarthy. MR imaging of fistula in ano: indications and contribution to surgical assessment *Acta Chir Belg*, 111 (6) (2011), pp. 393-397
- [11]. M. Siddiqui, H. Ashrafian, P. Tozer, N. Daulatzai, D. Burling, A. Hart, et al. A diagnostic accuracy meta-analysis of endoanal ultrasound and MRI for perianal fistula assessment *Dis Colon Rectum*, 55 (5) (2012), pp. 576-585
- [12]. Rafal RB, Nichols JN, Cennerazzo WJ, Kazam E, DeCosse JJ. MRI for evaluation of perianal inflammation. *Abdom Imaging* 1995;20:248-52
- [13]. R. Beets-Tan, G. Beets, D. Van, A. Hoop. Preoperative MR imaging of anal fistulas: does it really help the surgeon? *Radiology*, 218 (2001), pp. 75-84
- [14]. Charles P. Heise, Perry J. Pickhardt, MR Imaging Evaluation of Perianal Fistulas: Spectrum of Imaging Features *Radiographics* January-February 2012;32:(1) 194-197.
- [15]. Karban A, Hay M, Davidovich O, Le Shinsky Silver E, Kimmel G. Risk factors for perianal Crohn's disease; the Role of Genotype, Phenotype and ethnicity. *Am J Gastroenterol*. 2007 Aug;102(8):1702-1708.
- [16]. C. Villa, G. Pompili, G. Franceschelli, A. Munari, G. Radaelli, G. Maconi, et al. Role of magnetic resonance imaging in evaluation of the activity of perianal Crohn's disease *Eur J Radiol*, 81 (2011), pp. 616-622

Dr. Paresh Kumar Sukhani. "Perianal Fistula Evaluation on Pelvic Mri: Our Experience." *IOSR Journal of Dental and Medical Sciences (IOSR-JDMS)*, vol. 17, no. 1, 2018, pp. 38-46.