

Oral Submucous Fibrosis (OSMF)- A Review

Dr Falak Ashraf

MDS ORAL PATHOLOGY Daswani Dental College & research centre Kota Rajasthan

Corresponding Author: Dr Falak Ashraf

Date of Submission: 14-11-2018

Date of acceptance: 29-11-2018

I. Introduction:

According to Pindborg and Sirsat (1966), OSMF is an insidious chronic disease affecting any part of the oral cavity and sometimes the pharynx. Although occasionally preceded by and/or associated with vesicle formation, it is always associated with juxta-epithelial inflammatory reaction, followed by fibroelastic changes of the lamina propria with epithelial atrophy leading to stiffness of mucosa and causing trismus and inability to eat.¹ It is an insidious chronic disease affecting any part of the oral cavity and sometimes pharynx, although occasionally preceded by and/or associated with vesicle formation it is always associated with juxtaepithelial inflammatory reaction followed by fibroelastic changes of lamina propria, with epithelial atrophy leading to stiffness of oral mucosa and causing trismus and inability to eat.²

OSMF is a high risk premalignant condition and has grabbed millions of individuals predominantly Indians and is likely to reach an alarming proportion in near future. Its prevalence rate is 0.2 to 0.5% with higher percentage reported from southern states. The malignant transformation rate of OSMF ranges from 5 to 10%.³ Unlike other precancerous lesion, OSMF is insidious in origin and does not regress, either spontaneously or with cessation of habits. The condition may remain either stationary or become severe, leaving an individual handicapped both physically and psychologically. Majority of the affected individuals are young adults, usually presenting with pain, burning sensation on consumption of hot and spicy food, and progressive inability to open the mouth leading to difficulty in mastication and speech.⁴

CLASSIFICATION OF OSMF

Classification of oral sub mucous fibrosis

1. Classification Based on Clinical and Histologic Features

1.2 Classification Based On Clinical Features

JV Desa (1957) divided OSMF into three stages as follows:⁵

STAGE 1: Stomatitis and vesiculation

STAGE 2: Fibrosis.

STAGE 3: As its sequelae.

Pindborg JJ (1989) divided OSMF into three stages.⁶

Stage 1: Stomatitis includes erythematous mucosa, vesicles, mucosal ulcers, melanotic mucosal pigmentation and mucosal petechiae.

Stage 2: Fibrosis occurs in healing vesicles and ulcers, which is the hallmark of this stage.

Stage 3: Sequelae of OSMF are as follows:

Leukoplakia is found in more than 25% of individuals with OSMF. Speech and hearing deficit may occur because of involvement of tongue and the Eustachian tube.

Sk Katharia et al (1992) have given different scores assigned to the patients on the basis of mouth opening between upper and lower central incisors as follows:⁷

Score 0: Mouth opening is 41 mm or more.

Score 1: Mouth opening is 37 to 40 mm.

Score 2: Mouth opening is 33 to 36 mm.

Score 3: Mouth opening is 29 to 32 mm.

Score 4: Mouth opening is 25 to 28 mm.

Score 5: Mouth opening is 21 to 24 mm.

Score 6: Mouth opening is 17 to 20 mm.

Score 7: Mouth opening is 13 to 16 mm.

Score 8: Mouth opening is 09 to 12 mm.

Score 9: Mouth opening is 05 to 08 mm.

Score 10: Mouth opening is 0 to 04 mm.

1.2 Classifications Based on Histopathological Features of OSMF:

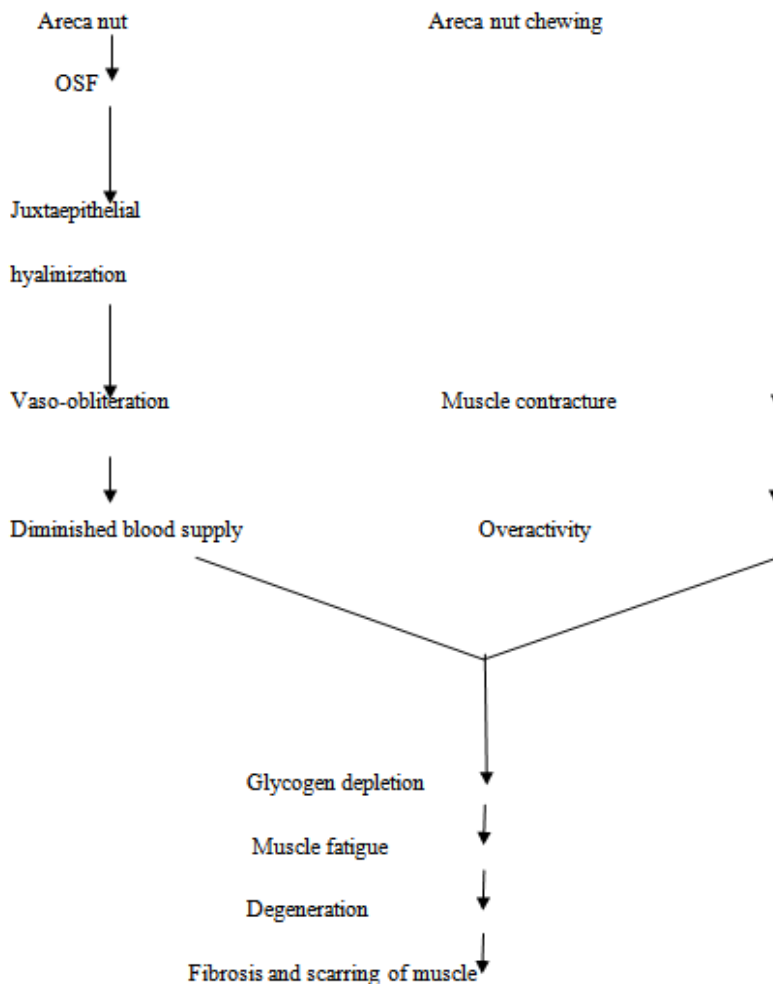
Pindborg JJ and Sirsat SM (1966)⁵ were the first to divide OSMF depending only on histopathological features alone are as follows

- **Very early stage:** Finely fibrillar collagen dispersed with marked edema. Plump young fibroblast containing abundant cytoplasm. Blood vessels are dilated and congested. Inflammatory cells, mainly polymorphonuclear leukocytes with occasional eosinophils are found.
- **Early stage:** Juxta-epithelial area shows early hyalinization. Collagen still in separate thick bundles. Moderate number of plump young fibroblasts is present. Dilated and congested blood vessels. Inflammatory cells are primarily lymphocytes, eosinophils and occasional plasma cells.
- **Moderately advanced stage:** Collagen is moderately hyalinized. Thickened collagen bundles are separated by slight residual edema. Fibroblastic response is less marked. Bloodvessels are either normal or compressed. Inflammatory exudate consists of lymphocytes and plasma cells.
- **Advanced stage:** Collagen is completely hyalinized. A smooth sheet with no separate bundles of collagen is seen. Edema is absent. Hyalinized area is devoid of fibroblasts. Blood vessels are completely obliterated or narrowed. Inflammatory cells are lymphocytes and plasma cells.

ETIOPATHOGENESIS

ARECA NUT

Areca alkaloids causing fibroblast proliferation and increased collagen synthesis;



Role of areca nut in pathogenesis of OSMF (muscle degeneration) (J. N. Khanna 1995).⁸

CLINICAL FEATURES

Oral submucous fibrosis typically affects the buccal mucosa, lips, retromolar areas and the soft palate. Occasional involvement of the pharynx and esophagus is seen. Early lesions present as a blanching of the mucosa imparting a mottled, marble like appearance. Later lesions demonstrate palpable fibrous bands running

vertically in the buccal mucosa and in a circular fashion around the mouth opening or lips. As the disease progresses the mucosa becomes stiff, causing difficulty in eating and considerably restricting the patient's ability to open the mouth (trismus).¹

The classification/grading of OSF is done according to the degree of trismus, which directly correlates with the degree of fibrosis, progression of the disease, and location of the lesion in the oral mucosa (Pindborg 1966).⁵

Wahi et al (1966)

Grade I-No symptom referable to mucosal involvement, affects one or more commonly involved anatomic site, focal in character, shows pallor or whitish coloration, wrinkling of mucosa and minimal induration.

Grade II- Symptoms of Soreness of mucosa or increased sensitivity to chillies. The lesion is diffuse, whitish, extensively; indurate involving on one or more anatomical sites

Grade III- Symptoms due to restricted mouth opening, stretching of angles of mouth, inability to protrude the tongue, presence of altered pronunciation and palpable firm submucosal bands.

HISTOPATHOLOGY

Structural changes in oral submucous fibrosis have been studied in detail both at the light and electron microscopic levels. Van Wyk et al. (1990) studied the patterns of distribution of different types of collagen in subjects with confirmed oral submucous fibrosis. Ultrastructural findings of muscle degeneration in oral submucous fibrosis were reported by Cannif (1985).⁹

Epithelial changes

Histological findings in OSMF cases were found to vary depending on the clinical severity of the cases and the site of biopsy. The observed epithelial changes are secondary to changes in connective tissue. The findings range from normal to atrophic and hyperplastic epithelium Pindborg and Sirsat (1966)⁵ observed marked changes in the form of atrophy of epithelium with loss of rete pegs in 90% of the cases as compared to normal oral mucosa.

Connective tissue changes

Characteristically the changes begin in connective tissue and vary with different stages of OSMF. Pindborg et al (1966)⁵ have described consecutive stages in submucous fibrosis cases based on sections stained with haematoxylin and eosin

The changes are based on following criteria

1. Presence or absence of oedema
2. Nature of the collagen bundles
3. Overall fibroblastic response
4. State of the blood vessels
5. Predominant cell type in the inflammatory exudates.¹⁰

Very early stage

In this stage, fine fibrillar collagen dispersed with marked oedema, with strong fibroblastic response showing plump young fibroblasts containing abundant cytoplasm will be observed. The blood vessels are occasionally normal, but more often they are dilated and congested. Inflammatory cells, mainly polymorphonuclear leukocytes with occasional eosinophils, are present.

Early stage

In this stage juxta-epithelial area shows early hyalinisation. The collagen is still seen as separate bundles which are thickened. Plump young fibroblasts are present in moderate numbers. The blood vessels are often dilated and congested. The inflammatory cells are mostly lymphocytes, eosinophils and the occasional plasma cells.

Moderately advanced stage

In this stage, the collagen is moderately hyalinised. The amorphous change starts from the juxta-epithelial basement membrane occasionally, thickened collagen bundles are still seen separated by slight residual oedema. The adult fibroblastic cells have elongated spindle shaped nuclei and scanty cytoplasm. Blood vessels are- either normal or constricted as a result of increased surrounding tissue. The inflammatory exudate consists of lymphocytes, plasma cells and occasional eosinophils.

Advanced stage

Here, the collagen is completely hyalinised and is seen as a smooth sheet with no distinct bundles or oedema. The hyalinised connective tissue becomes hypocellular with thin elongated cells with vestigial nucleus

at rare intervals along the bundles. Blood vessels are completely obliterated or narrowed. The inflammatory exudate consists of lymphocytes and plasma cells and occasional eosinophils, Interestingly the melanin-containing cells in the lamina propria are surrounded by dense collagen, which explains the clinically observed loss of pigmentation,

Lamina propria

The collagen in oral submucous fibrosis are reported as normally banded (sirsat & khandolkar 1987). Several histological and electron-microscopic studies reported that the collagen itself is abnormal. It shows hyaline degeneration, fragmentation, elastic degeneration (Sirsat & Pindborg 1967) and changed staining properties. The ultrastructural features were described as abnormal collagen fibrils, fragmented and bent at odd angles .

Adjacent to the basement membrane there was a thin zone relatively sparsely populated with individual collagen fibrils and loosely arranged groups of fibrils running parallel to the epithelial-connective tissue junction. Some fibrils lacked the typical periodicity of collagen and a similar pattern was seen in submucosa next to salivary glands and muscle bundles.¹¹

MANAGEMENT OF OSMF

Restriction of Habit behavioral therapy

Reduction or even elimination of the habit of areca nut chewing is an important preventive measure. At least in the early stages of OSMF, it could probably slow the progress of the disease

(a) Nutritional support- Supplementary diets administered to OSMF patients are mainly for high protein and calories and for vitamin B complex and other vitamins and minerals. These are commonly employed in combination with other more specific therapeutic agents like ingestion of iodinated salt and/or local applications .¹¹

Use of Steroids Local injections of dexamethasone, hyaluronidase and placental extract have been tried. In vitro, collagen from patients with OSMF, in contrast to normal collagen, is attacked rapidly by hyaluronidase.

Corticosteroids:

OSMF is always associated with juxta-epithelial inflammatory response. The use of corticosteroids suppresses inflammatory response by their anti-inflammatory action. It prevents fibrosis by decreasing fibroblastic proliferation and deposition of collagen. Corticosteroids can be administered as local injection (intralesional injection), topical applications or in the form of mouth washes. Widely used preparations are dexamethasone, 4 mg biweekly injection, for a period of 10 weeks. (Betnesol) 0.5 mg mouthwash is given to relieve pain and burning sensation, for topical application triamcinolone 0.1% is given for 37 relief of pain and burning sensation.¹¹

Hyaluronidase:

Experimental studies revealed that collagen altered in vivo is susceptible to fibrinolytic enzymes such as hyaluronidase, trypsin and elastase (Satyavathi, Sirsat). Hyaluronidase is known to break down hyaluronic acid, lower the viscosity of the intercellular cement substance and also decreases collagen formation. Intralesional injection of Hyalase (Rallis India) used in the dose of 1500 IU, Chymotrypsin (Waltor Bushnell India) 5000 IU. Fibrinolytic agents (Hyalase) were found to be acceptable by patients.¹¹

Placental Extracts (placentrex)

Such extracts, in the form of the local injections, have been tried with varied results. The combination of dexamethasone, hyaluronidase and placental extract were found to give better 62 results than with a single drug.¹¹

Surgical Technique

Surgical Treatment : Excision of fibrotic tissues and covering the defect with split thickness skin, fresh human amnion or buccal fat pad (BFP) grafts have been applied to treat OSMF.¹¹

SUPPORTIVE THERAPY

Along with medicinal and surgical management supportive measures should be used like

1. Physiotherapy
2. Microwave diathermy
- 3 Oral stents ¹¹

References

- [1]. Ashok L. Red and White Lesions. In Ongole R, Praveen BN. Editors. Textbook of Oral Medicine Oral Diagnosis and Oral Radiology. India: Elsevier. 2013; p 159.

- [2]. Ghom AG, Mhaske S. Premalignant lesions and conditions. In Ghom AG, Mhaske S. Editors. Text Book Of Oral Pathology. India: Jaypee. 2013; p 249.
- [3]. C.-Y. Yeh: Application Of The Buccal Fat Pad To The Surgical Treatment Of Oral Submucous Fibrosis. Int. J. Oral Maxillofac. Surg. 1996; 25: 130-133
- [4]. N. J. Mokal, R. S. Raje. Release Of Oral Submucous Fibrosis And Reconstruction Using Superficial Temporal Fascia Flap And Split Skin Graft-A New Technique, British Journal Of Plastic Surgery(2005) 58, 1055-1060
- [5]. Pindborg JJ, Sirsat SM. Oral Submucous Fibrosis. Oral Surg Oral Med Oral Pathol. 1966 Dec;22(6):764-79.
- [6]. Priyadarshini.B. classification system for oral submucous grading – A Review. Int J Health sci . 2014;740-743.
- [7]. S K. Katharia, S. P. Singh, V. K. Kulshreshtha , The Effects Of Placenta Extract In Management Of Oral Submucous Fibrosis. Indian Journal Of Pharmacology 1992; 24: 181-183.
- [8]. Khanna J. N., Andrade N. N. Oral Submucous Fibrosis: A New Concept In Surgical Management Report Of 100 Cases, Int. J. Oral Maxillofac. Surg. 1995: 24: 433-439
- [9]. Canniff J.P., Batchlor J.R Dodi I.A, Harvey W. Hla-Typing In Oral Submucous Fibrosis. Tissue Antigens. Aug 1985; 26 (2):138-42
- [10]. C.-Y. Yeh: Application Of The Buccal Fat Pad To The Surgical Treatment Of Oral Submucous Fibrosis. Int. J. Oral Maxillofac. Surg. 1996; 25: 130-133
- [11]. Savita JK, Girish HC, Murgod S, Kumar H. Oral Submucous Fibrosis- A Review. Int J Health Sci. 2011; 37-48

Dr Falak Ashraf. , “Oral Submucous Fibrosis (OSMF)- A Review..”. ” IOSR Journal of Dental and Medical Sciences (IOSR-JDMS), vol. 17, no. 11, 2018, pp 40-44.