

Primary thyroid like Follicular carcinoma of kidney: An egressing material

Dr. Jakkula Srikanth¹, Dr. Sri Harsha Muvva², Dr. Amith³
Dr. Kanmathareddy Amulya⁴.

^{1,2}(Post-Graduate General Surgery, SVS Medical college, KNR university of Health sciences, INDIA)

³(Consultant urologist –Department of urology, SVS Medical College, KNRUHS, INDIA)

⁴(Post-Graduate General Surgery, SVS Medical college, KNR university of Health sciences, INDIA)

Corresponding Author: Dr. Jakkula Srikanth

Abstract: Thyroid-like follicular carcinoma of the kidney (TLFCK), is a rare and recently described subtype of renal cell carcinoma (RCC) till now only 27 cases reported in the literature. An extremely rare tumor with low malignant potential and exhibits morphologic features that strikingly resemble primary follicular carcinoma of the thyroid gland. A 70 years old male presented to our department with complaints of left flank pain and nausea since 15 days. CECT abdomen and pelvis revealed a single well defined, large mildly enhancing mass lesion in the lower pole of left kidney with solid and cystic components. Radical nephrectomy was done. Microscopy and IHC confirmed the diagnosis of TLFCK.

Key Words: Follicular carcinoma like rcc, Fuhrman's grade, thyroidisation, metastasis, radical nephrectomy.

Date of Submission: 28-10-2018

Date of acceptance: 14-11-2018

I. Introduction

Incidence of renal cell carcinoma (RCC) is increasing worldwide which accounts for 2-3% of all cancers.⁽¹⁾ Thyroid-like follicular carcinoma of the kidney (TLFCK), is a rare and recently described subtype of renal cell carcinoma (RCC) not included in the 2004 World Health Organization (WHO) classification of renal tumors.⁽²⁾ Amin *et al* described 4 cases of TLFCK for the first time in 2004.⁽³⁾ This is an extremely rare tumor with low malignant potential and exhibits morphologic features that strikingly resemble primary follicular carcinoma of the thyroid gland, but characteristically negative for thyroid immunohistochemical markers.⁽²⁾ Only 27 cases have been described in the literature.⁽⁴⁾

We report a further case of this rare histological entity, discuss the clinical, histological and immunohistochemical findings and provide an update on the review of the literature.

II. Case Report

A 70 years old male presented to our department with complaints of left flank pain and nausea since 15 days. He had no history of urinary tract infections, haematuria, no relevant past medical or family history. General and physical examination is normal. No palpable mass per abdomen and no renal angle tenderness. Laboratory data including thyroid profile were within the normal limits. USG abdomen reveals a 9x10 cms heterogenous hypoechoic mass arising from lower pole of the kidney with variable solid and cystic components, probably a tumour arising from left lower pole of kidney.

CECT abdomen and pelvis revealed a single well defined, large mildly enhancing mass lesion in the lower pole of left kidney with solid cystic components and few peripheral calcifications approximately measuring 11x9 x8 cms suggestive of renal cell carcinoma, without evidence of renal vein involvement and lymphadenopathy (T2N0M0). Bilateral renal cortical cysts and staghorn calculus on left side were present. (figure 1 and 2)

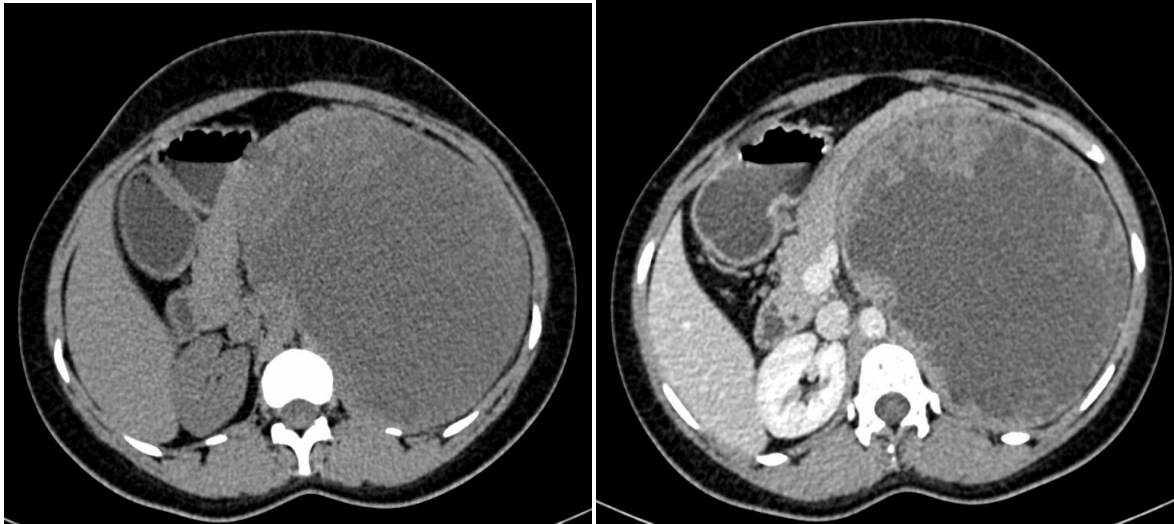

Fig 1 & 2 : CECT axial section showing well defined enhancing mass lesion in lower pole of kidney with solid and cystic components

Patient underwent left sided nephrectomy.(figure 3) specimen sent for Histopathological examination. Post op period uneventful. patient was discharged on fourth post operative day. Cut section of the specimen shows multiple small cystic spaces with greatest dimension being 9 cms, variegated appearance with marked haemorrhage and necrosis. Gerota's fascia and capsule were intact and adrenal gland was not found. 4 cms long ureter was excised along with renal vessels. microscopically tumour was limited to fibrous capsule, it consisted of follicles of varying sizes filled with colloid like material. follicles were lined by cuboidal to columnar cells. nuclei were round to ovoid. Histologic Grade: (Fuhrman's grade) G2: Nuclei slightly irregular, approximately 15 μ m; nucleoli evident. with above findings, diagnosis of thyroid follicular carcinoma like RCC was made with Primary Tumor (pT): pT2aNoMo with no Lympho-Vascular Invasion. Patient was kept on follow up for 10 months with no evidence of distant metastasis.(figure 4,5 and 6)

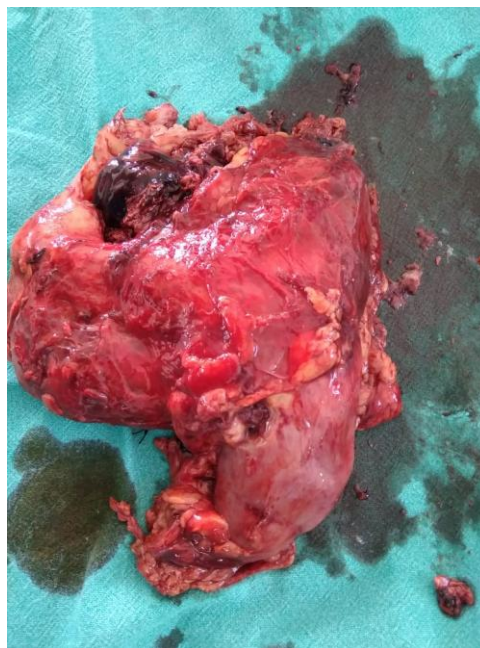


Fig 3 : intra-operative picture

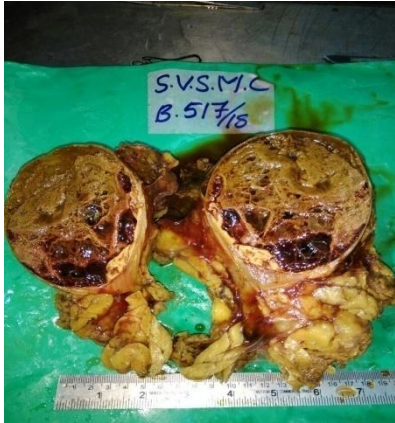

Fig 4 : Cut section image

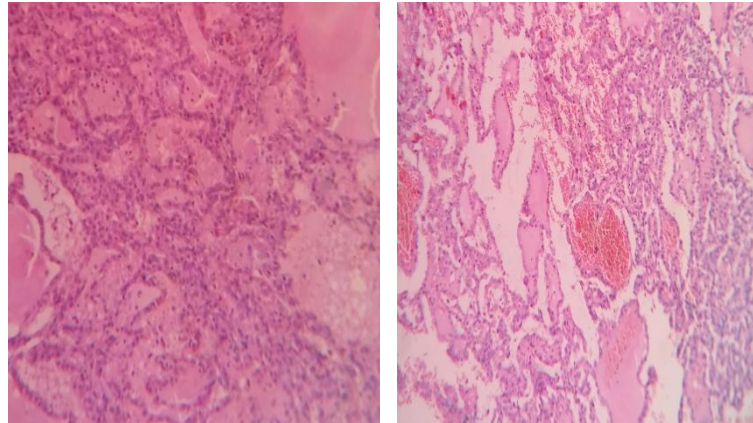


Fig 5 & 6 : HPE showing thyroid like follicles

III. Discussion

Renal cell carcinoma (RCC) accounts for 2-3% of all cancers. It is the commonest solid renal malignancy, accounting for approximately 90% of all renal cancers, and comprises a number of distinct pathological entities. Primary thyroid-like follicular carcinoma of the kidney (TLFCK) is a rare and recently described histologic variant of RCC that is not included in the current WHO classification of renal tumors.⁽²⁾

In patients with conditions such as chronic pyelonephritis, obstructive uropathy, or end-stage renal disease, thyroidisation of the kidney is noted in which renal tissue demonstrates a thyroid-like appearance characterised by atrophic distal tubules and colloid-like hyaline casts.^(5,6) It is a benign phenomenon that is typically bilateral and widespread, as opposed to TLFCK which is well circumscribed and occurs in patients without renal disease. TLFCK are usually found in middle-aged patients (mean: 41.8 years; range: 19–83 years), with 15 women and 11 men affected.⁽⁴⁾ Four cases of TLFCK were first described in abstract format by Amin et al. in 2004 and later expanded in 2009 to include 6 cases.⁽⁸⁾

More than half of the patients with TLFCK were asymptomatic. If symptomatic they present with hematuria and abdominal/flank pain. Rare symptoms such as weight loss⁽⁸⁾ and hypertension⁽⁹⁾ have also been reported. Though being a low grade with an indolent course, renal hilar lymph node involvement was noted in one case⁽⁷⁾ other had widespread retroperitoneal lymph node and lung metastases at presentation.⁽¹⁰⁾ Another case had skull and meningeal metastasis at presentation.⁽⁴⁾ This emphasizes the low but distinct malignant potential of these tumors.

The differential diagnosis for TLFCK includes the metastasis from a primary thyroid carcinoma, carcinoid tumor involving the kidney, and metastatic follicular carcinoma arising in struma ovarii in females.^(11,12) Follicular carcinoma of the thyroid very rarely metastasizes to the kidney, metastases being usually localized in the lung and bone.⁽¹³⁾ Only twenty cases of follicular thyroid carcinoma metastasizing in the kidney have been reported in the literature. In all most all these cases, a primary tumor was present in the thyroid gland, and metastases were widespread, involving other organs.^(14,15) More than 90% were symptomatic at presentation due to the renal (75%) or extrarenal involvement (25%),⁽¹⁶⁾ Furthermore, all these tumors demonstrated positive immunoreactivity for the thyroid-specific markers thyroid transcription factor (TTF-1) and thyroglobulin (Tg).

Renal carcinoids are also rare neoplasms with approximately 60 cases reported in literature; as they commonly occur in the horseshoe-shaped kidney.⁽¹²⁾ Though carcinoid tumors may show focal immunoreactivity with CK7, they can be distinguished from TLFCK by carcinoid tumor's consistent immunoreactivity for synaptophysin and chromogranin. Struma ovarii, an ovarian teratoma composed mainly of thyroid tissue,⁽¹⁷⁾ they are rarely malignant and only metastasize to liver and peritoneum in 5% of cases.⁽¹⁸⁾ till date there are no cases of struma ovarii metastasizing to the kidney.

Microscopically, TLFCK are composed of variably sized follicular structures lined by a single layer of cuboidal to columnar cells with moderate amphophilic to eosinophilic cytoplasm. Marked lymphocytic infiltration may be present. They may occasionally contain lymphoid follicles with reactive germinal centres.⁽¹⁹⁾ Most of the tumours are Fuhrman nuclear grade 2-3 with rare mitotic activity. Most important factor in the TLFCK diagnosis is the negativity for TTF-1 and TG. Some cases may be positive for CD-10, PAX-2, EMA, CK-7.

With more extensive use of imaging for intra-abdominal disease, there is an increase in detection of incidental renal mass lesions.⁽²⁰⁾ CECT abdomen and CT KUB are useful in the diagnosis of renal malignancy. Surgery is the main modality of treatment for thyroid-like follicular carcinoma of kidney. The role of radiotherapy and chemotherapy has not yet been proven.

IV. Conclusion :

Primary thyroid-like follicular carcinoma of the kidney (TLFCK) is a rare and recently described histologic variant of RCC that is not included in the current WHO classification of renal tumors. Most of the tumours are Fuhrman nuclear grade 2-3 with rare mitotic activity. Most important factor in the TLFCK diagnosis is the negativity for TTF-1 and TG. Surgery remains the mainstay of treatment. The role of radiotherapy and chemotherapy has not yet been proven.

References

- [1]. B. Ljungberg, N. Cowan, D. C. Hanbury, H. Mora, M. A. Kuczyk, A. S. Merseburger et al., "Guidelines on Renal Cell Carcinoma," Uroweb, 2012, [http://www.uroweb.org/gls/pdf/NEW09 Renal Cell Carcinoma LR.pdf](http://www.uroweb.org/gls/pdf/NEW09_Renal_Cell_Carcinoma_LR.pdf).
- [2]. J. N. Eble, G. Sauter, J. I. Epstein et al., Pathology and Genetics of Tumours of the Urinary System and Male Genital Organs, World Health Organization Classification of Tumours, IARC Press, Lyon, France, 2004.
- [3]. Amin MB, Michal M, Radhakrishnan A, et al. Primary thyroid-like follicular carcinoma of the kidney: a histologically distinctive primary renal epithelial tumor. Mod Pathol. 2004;137A
- [4]. Liang Dong, MD, Jiayu Huang *et al.*, Thyroid-Like Follicular Carcinoma of the Kidney in a Patient with Skull and Meningeal Metastasis. Medicine clinical case reports. Volume 95, Number 15, April 2016. DOI: 10.1097/ MD.00000000000003314
- [5]. H.G.Laberke, Klingebiel Th., and G. Quack, "A contribution to the morphology and pathogenesis of thyroid-like lesions in the kidney," Pathology Research and Practice, vol. 176, no. 2-4, pp. 284-296, 1983.
- [6]. T. Nadasdy, Z. Laszik, K. E. Blick, D. L. Johnson, and F. G. Silva, "Tubular atrophy in the end-stage kidney: a lectin and immunohistochemical study," Human Pathology, vol. 25, no. 1, pp. 22-28, 1994.
- [7]. M. B. Amin, R. Gupta, H. Ondrej et al., "Primary thyroidlike follicular carcinoma of the kidney: report of 6 cases of a histologically distinctive adult renal epithelial neoplasm," The American Journal of Surgical Pathology, vol. 33, no. 3, pp. 393-400, 2009
- [8]. Khoja HA, Almutawa A, Binmahfooz A, et al. Papillary thyroid carcinoma-like tumor of the kidney: a case report. Int J Surg Pathol. 2012;20:411-415.
- [9]. Wu XZ, Liu M, Feng HH. Clinicopathological study of thyroid follicular carcinoma-like renal tumor. Zhonghua Mi Niao Wai Ke Za Zhi. 2013;34:14-16.
- [10]. J. Dhillon, N. M. Tannir, S. F. Matin, P. Tamboli, B. A. Czerniak, and C. C. Guo, "Thyroid-like follicular carcinoma of the kidney with metastases to the lungs and retroperitoneal lymph nodes," Human Pathology, vol. 42, no. 1, pp. 146-150, 2011.
- [11]. Gupta R, Viswanathan S, D'Cruz A, et al. Metastatic papillary carcinoma of thyroid masquerading as a renal tumour. J Clin Pathol. 2008;61:143.
- [12]. Hansel DE, Epstein JI, Berbesu E, et al. Renal carcinoid tumor: a clinicopathologic study of 21 cases. Am J Surg Pathol. 2007;31:1539-1544.
- [13]. Jung SJ, Chung JI, Park SH, Ayala AG, Ro JY: Thyroid follicular carcinoma-like tumor of kidney: a case report with morphologic, immunohistochemical, and genetic analysis. Am J Surg Pathol 2006, 30:411-415.
- [14]. Abe K, Hasegawa T, Onodera S, Oishi Y, Suzuki M: Renal metastasis of thyroid carcinoma. Int J Urol 2002, 9:656-658.
- [15]. Garcia-Sanchis L, Lopez-Aznar D, Oltra A, Rivas A, Alonso J, Montalar J, Mateo A: Metastatic follicular thyroid carcinoma to the kidney: a case report. Clin Nucl Med 1999, 24:48-50.
- [16]. Liou MJ, Lin JD, Chung MH, et al. Renal metastasis from papillary thyroid microcarcinoma. Acta Otolaryngol. 2005;125: 438-442.
- [17]. J.D. Woodruff, J.T. Rauh, and R.L. Markley, "Ovarian struma," Obstetrics & Gynecology, vol. 27, pp. 194-201, 1996.
- [18]. Berghella, S. Ngadiman, H. Rosenberg, S. Hoda, and R. E. Zuna, "Malignant struma ovarii. A case report and review of the literature," Gynecologic and Obstetric Investigation, vol. 43, no. 1, pp. 68-72, 1997.
- [19]. Srigley JR, Delahunt B: Uncommon and recently described renal carcinomas. Mod Pathol 2009, 22:S2-S23.
- [20]. Kunkle DA, Egleston BL, Uzzo RG. Excise, ablate or observe: the small renal mass dilemma—a meta-analysis and review. J Urol. 2008;179:1227-1233; discussion 1233-1224.

Dr. Jakkula Srikanth. "Primary thyroid like Follicular carcinoma of kidney:An egressing material. " IOSR Journal of Dental and Medical Sciences (IOSR-JDMS), vol. 17, no. 11, 2018, pp 06-09.