

## Mucormycosis of anterior chest wall in an immunocompetent patient: A rare case report

Prachi Kukreja<sup>1</sup>, Sunanda Joshi<sup>2</sup>, Nalini Mittal<sup>3</sup>, B K Verma<sup>4</sup>

<sup>1</sup>(Department of Pathology, Babujagjivan ram memorial hospital, Jahangirpuri, Delhi, India)

<sup>2</sup>(Department of Microbiology, Babujagjivan ram memorial hospital, Jahangirpuri, Delhi, India)

<sup>3</sup>(Department of Microbiology, Babujagjivan ram memorial hospital, Jahangirpuri, Delhi, India)

<sup>4</sup>(Department of Pathology, Babujagjivan ram memorial hospital, Jahangirpuri, Delhi, India)

Corresponding Author: Prachi Kukreja

**Abstract:** Mucormycosis is caused by fungi of order mucorales. Rhizopus is a medically important fungi of this order as it is known to cause invasive disease with a fatal outcome. It is commonly seen in immunocompromised individuals like uncontrolled diabetes mellitus, organ transplant, corticosteroids intake, neutropenia or any other condition known to compromise the immune system. Mucormycosis in immunocompetent individuals is extremely rare. We present a rare case of cutaneous mucormycosis of anterior chest wall in an immunocompetent individual therefore emphasizing the need to consider it as a differential diagnosis in patients with cutaneous chronic granulomatous lesions.

**Key-words:** Mucormycosis, Rhizopus, Chest wall, Cutaneous

Date of Submission: 05-12-2018

Date of acceptance: 21-12-2018

### I. Introduction

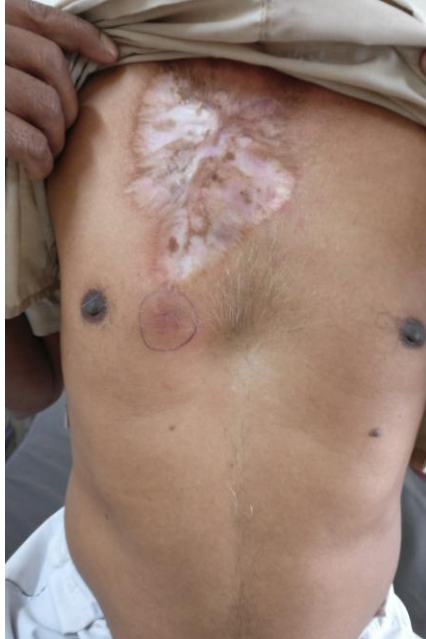Fungi in the class zygomycetes cause zygomycosis.<sup>1</sup> Mucorales was a part of Zygomycota but has now been reclassified into the phylum Glomeromycota, subphylum Mucoromycotina.<sup>2</sup> Rhizopus belongs to the mucoraceae family which are known to cause majority of the invasive diseases.<sup>3</sup> They are characterized by septate or pauci-septate hyphae, asexual reproduction with nonmotile sporangiospores and sexual reproduction by zygospores.<sup>3</sup> Mucormycosis usually presents in immunocompromised individuals as an opportunistic infection.<sup>4</sup> We report a case of mucormycosis caused by Rhizopus species in a completely healthy individual therefore making this case of higher clinical significance and interest.

### II. Case History

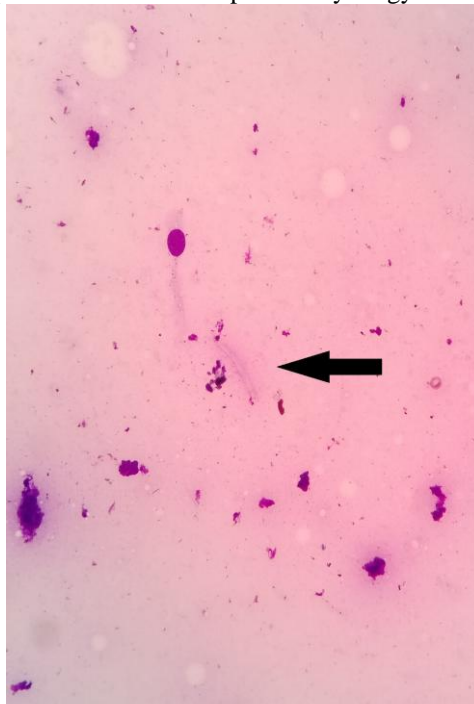
A 60 year old male patient was referred to our department with a swelling on anterior chest wall (right side) near nipple for the past two months. The clinical diagnosis offered was cold abscess and the patient was sent to the pathology department for fine needle aspiration cytology. The patient complained that the swelling was progressively increasing accompanied by itching. He gave past history of a surgery performed seven years ago of a similar mass just above the existing swelling, however no records of previous surgery were available with the patient. There were no histories of local trauma/ fever/ diabetes/ tuberculosis/ drug addiction/ drug intake or similar complaints in family. The patient was farmer by occupation. On examination the swelling was well defined, non-tender, firm in consistency, measuring three by three centimeters. There was big scar of previous surgery just above the present swelling extending from the clavicle till the nipple (figure 1). Fine Needle Aspiration Cytology (FNAC) was performed by a 24 gauge needle without aspiration technique. It yielded serosanguinous aspirate. The smears were air dried and stained with Giemsa stain. Ziehl-Neelsen stain was also performed due to clinical suspicion of cold abscess. On microscopy, smears showed epithelioid cell granulomas with few foreign body type of giant cells in the background of cellular debris and necrotic material. There was seen an occasional degenerated fungal hyphae type of structure which raised the suspicion of fungal infection (Figure 2). Stain for acid fast bacilli was negative. The cytology report was given as chronic granulomatous lesion. Repeat FNAC was performed and part of the material was sent to microbiology department for fungal culture. It was inoculated on Sabourauds dextrose agar medium and kept at 37 degrees celcius and 25 degree celcius. On fourth day of incubation the culture plate showed cotton wool type of colonies completely filling the plate which was incubated at 37 degree celcius (figure 3a). KOH and Lactophenol cotton blue preparations showed sporangiospores and pauci-septate large diameter hyphae with acute angle branching (figure 3b). There were also seen rhizoids at places (figure 3c). It was finally reported as rhizopus species at seventh day of incubation. All routine laboratory investigations done to see the immune status of the patient were within normal limits. Hemoglobin was 14.4gm/dl, Total leucocyte count- 6200 cells/cu mm with

Neutrophils-50%, Lymphocytes- 45%, Eosinophils- 05%, platelet count- 1, 50,000. Liver and kidney function tests were normal. Random blood sugar was 98gm/dl, HBsAg and HIV were non-reactive. The patient was then referred to higher center for further workup. Culture for mycobacterium there was negative and fungal culture report confirmed the diagnosis of Mucormycosis. The patient was treated successfully and is presently asymptomatic.

**Figure 1:** A well defined swelling on anterior chest wall with a scar just above present swelling



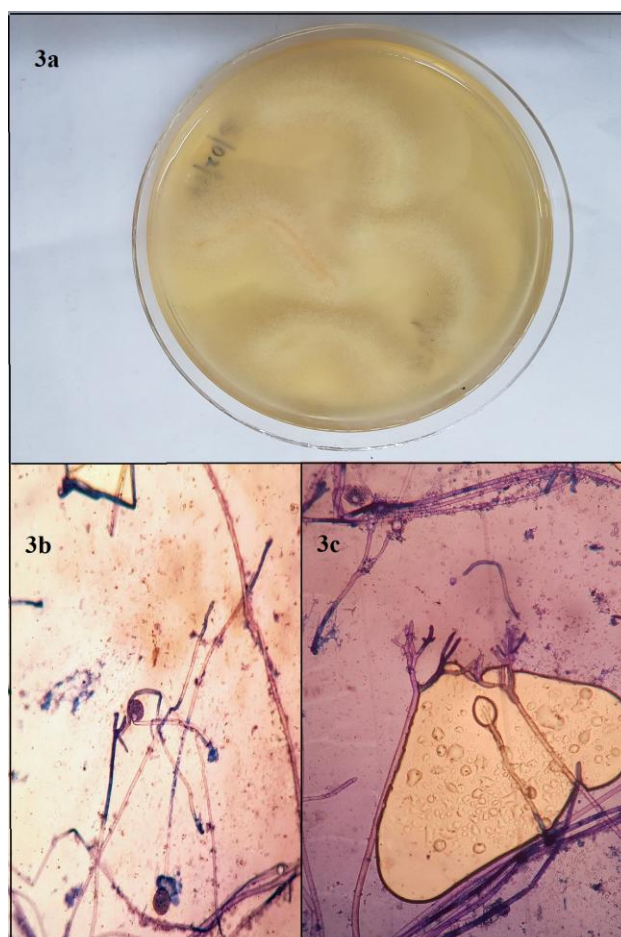
**Figure 2:** Degenerated fungal hyphae in Fine needle aspiration cytology smear (arrow) (Giemsa 400x)



**Figure 3a:** Cotton wool type of colonies on Sabarauds dextrose agar completely filling the plate.

**Figure 3b:** Lactophenol cotton blue preparations showing pauciseptate large diameter hyphae with acute angle branching and sporangiospores

**Figure 3c:** Rhizoids seen in Lactophenol cotton blue preparations



### III. Discussion

Zygomycosis is an infection caused by phycmycetes. These are large, thin-walled and nonseptate fungi. Zygomycetes comprises of order Mucorales and Entomophthorales, which contain many fungus of medical importance. Fungi of the order mucorales are distributed into six families. Among the family Mucoraceae, *Rhizopus arrhizus* (*Rhizopus oryzae*) is the most common cause of infection.<sup>5</sup> Based on clinical presentation and the involvement of a particular anatomic site, mucormycosis can be divided into at least six clinical categories: (i) rhinocerebral, (ii) pulmonary, (iii) cutaneous, (iv) gastrointestinal, (v) disseminated, and (iv) miscellaneous.<sup>6</sup> Mucormycosis is less common than other opportunistic fungal infections, such as those caused by *Candida* and *Aspergillus* spp.<sup>6</sup> It is more common in immunocompromised patients ,immunocompetent patients account for only a small number of cases of mucormycosis. In the year 2003 Kumar A et al reported a similar case of primary cutaneous mucormycosis in a 50 year old immunocompetent patient of the anterior abdominal wall.<sup>7</sup> There are no confirmatory serologic, PCR-based, or skin tests for mucormycosis. Diagnosis can be made by biopsy. The biopsy shows the characteristic wide, ribbon-like, aseptate hyphal elements that branch at right angles. Many fungi including *Aspergillus*, *Fusarium*, or *Scedosporium* spp, may look similar to the Mucorales on biopsy. Culture of the specimen can help in confirming the diagnosis.<sup>6</sup> In a worldwide review of 929 cases of zygomycosis by Roden et al, cutaneous zygomycosis was found to be the third most common (19%) form after sinus (39%) and pulmonary (24%) zygomycosis. It was more common in male patients with a mean age of 38. 8 years.<sup>8</sup> Literature survey showed that there is no effective antifungal medication available for preventing mucormycosis (till date).

Primary mucormycosis of the skin and wounds has been associated with burns, traumatic disruption of skin, persistent maceration of skin and with use of contaminated elasticized surgical bandages.<sup>6</sup> In our case the most probable source of infection is accidental/occupational which cannot be prevented. El Deeb Y et al in the

year 2005 also reported a case of cutaneous mucormycosis in a 20 year old male patient who got the infection after being involved in a road traffic accident.<sup>9</sup>

Cutaneous mucormycosis can be locally invasive and can penetrate the cutaneous and subcutaneous tissues into the adjacent fat, muscle, fascia and even bone. Vascular invasion may lead to infection of the deep organs. In the year 1992, Cocanour et al did a study on Mucormycosis in trauma patients in which 4 out of 11 biopsy or culture proven patients of mucormycosis died.<sup>10</sup> If surgical debridement is done then cutaneous mucormycosis has good prognosis and a low mortality rate.<sup>11</sup>

#### IV. Conclusion

Timely diagnosis of fungal infections like mucormycosis in an immunocompetent patient, is possible by better awareness in the clinicians and cooperation between pathologists and microbiologists.

#### References

- [1]. Spellberg B, Edwards J, Jr, Ibrahim A. Novel perspectives on mucormycosis: pathophysiology, presentation, and management. *ClinMicrobiol Rev* 2005;18:556-69.
- [2]. D. S. Hibbett, M. Binder, J. F. Bischo et al. A higher-level phylogenetic classification of the Fungi. *Mycological Research* 2007;111(5):509-47.
- [3]. Morace G, Borghi E. Invasive Mold Infections: Virulence and Pathogenesis of Mucorales. *Int J Microbiol* 2012, Article ID 349278, 5 pages doi:10.1155/2012/349278.
- [4]. M Pieters, CL Barrett, J Goedhals, L Badenhorst, WC Viljoen, MGL Spruyt. An unusual case of fatal gastrointestinal *Rhizopus oryzae* infection in a diabetic patient. *South Afr J Epidemiol Infect* 2008;23(3):18-20.
- [5]. Ribes JA, Vanover-Sams CL, Baker DJ. Zygomycetes in human disease. *ClinMicrobiol Rev* 2000;13:236-301.
- [6]. Spellberg B, Edwards J, Ibrahim A. Novel Perspectives on Mucormycosis: Pathophysiology, Presentation, and Management. *Clinical Microbiology Reviews*. 2005;18(3):556-69. doi:10.1128/CMR.18.3.556-569.2005.
- [7]. Kumar A, Khilnani GC, Aggarwal S, Kumar S, Banerjee U, Xess I. Primary cutaneous mucormycosis in an immunocompetent host: Report of a case. *Surg Today* 2003;33:319-22.
- [8]. Roden MM, Zaoutis TE, Buchanan WL, Knudsen TA, Sarkisova TA, Schaufele RL, et al. Epidemiology and outcome of zygomycosis: A review of 929 reported cases. *Clin Infect Dis* 2005;41:634-53.
- [9]. El Deeb Y, Al Soub H, AlmaslamaniM, AlKhuwaiter J, Taj-Aldeen SJ. Post traumatic cutaneous mucormycosis in an immunocompetant patient. *Ann Saudi Med* 2005;25(4):343-5.
- [10]. Cocanour CS, Miller-Crotchett P, Reed RL 2nd, Johnson OC, Fischer RP. Mucormycosis in trauma patients. *J Trauma* 1992; 32(1):12-5.
- [11]. Chawla R, Sehgal S, Ravindra Kumar S, MishraB. A rare case of mucormycosis of median sternotomy wound caused by *Rhizopus arrhizus*, *Indian J Med Mycol* 2007;25 :419-21.

Prachi Kukreja. "Mucormycosis of anterior chest wall in an immunocompetent patient: A rare case report." *IOSR Journal of Dental and Medical Sciences (IOSR-JDMS)*, vol. 17, no. 12, 2018, pp 60-63.