

Management and outcome of penetrating ocular trauma with intraocular foreign bodies at tertiary centre.

Dr. Aliya Sultana MS, FVR,

Assistant Professor, Sarojini Devi Eye Hospital, Hyderabad, Telangana, India.

Abstract

AIM: Aim of our study is to know the management and outcome of various open globe injuries with different types of intraocular foreign bodies at our tertiary centre.

Materials And Methods: 21 patients of open globe injuries with intraocular foreign bodies (IOFB) who presented to our institute were reviewed retrospectively by collecting data from medical records. Best corrected visual acuity, wound integrity, slit lamp and fundus examination were done in all patients. Patients with hazy media due to vitreous opacities were advised B Scan. Patients with intraocular foreign bodies detected on B Scan were advised CT Scan for proper location, size, shape and material of the foreign body. Wound repair/exploration, prophylactic scleral buckle, pars plana vitrectomy, Intra ocular foreign body removal after endolaser and silicone oil tamponade was done.

Date of Submission: 09-02-2018

Date of acceptance: 23-02-2018

I. Introduction

Ocular injuries are common in young male individuals. Most of the posterior segment injuries are work related. Ocular injuries with intra ocular foreign body (IOFB) have poor visual prognosis, need to be managed as early as possible. Risk of Endophthalmitis is high. Patients with ocular trauma should be treated as an ocular emergency.

II. Results:

All patients were male except two females, age group was between 12 to 35 years, most of the patients had work related injuries, only 2 had road traffic accident. Patients with clear anterior segment underwent early intervention. Delayed intervention was done in cases where the media was not clear. Patients with intra retinal IOFB had poor prognosis. Patients with metallic and glass IOFB had good prognosis compared to patient with wooden IOFB. Incidence of endophthalmitis was high with wooden IOFB. Two patients with retained metallic IOFB had panophthalmitis and no perception of light.

III. Conclusion

Open globe injuries with IOFB have poor prognosis, if associated with retinal incarceration, retinal detachment, endophthalmitis then anatomical as well as functional outcome becomes poor. Management of posterior segment IOFB is a challenging condition. Time of surgery, method of surgery, prophylactic intraocular antibiotics, long term follow up are important measures for a favourable outcome.

Study Design:

Retrospective study done in our institute at Sarojini Devi Eye Hospital. All cases of penetrating ocular trauma with IOFB presented to our vitreo retina department data collected from medical records. Patients who presented to our department from June 2016 to June 2017 were reviewed. All patients with different types of IOFB are included in the study. Penetrating ocular trauma with posterior segment involvement without IOFB excluded from this study.

IV. Materials and Methods

21 cases of penetrating ocular trauma with different types of IOFB were examined and managed based upon the clinical status. All patients underwent detailed ocular examination. Proper history included nature of trauma, working area or road traffic accident, BCVA, Slit lamp examination, fundus examination, if media is hazy B scan, X-ray orbit and CT Scan orbit 1.5mm slices, axial coronal views, plain scans to know the location

and size of IOFB. Management planned based upon the IOFB size, location and also associated factors like traumatic cataract, retinal detachment, endophthalmitis, vitreous incarceration in wound.

V. Results:

19(90%) patients were male, two(9.5%) were female, mean age of presentation was 18 years.

16(76%) patients presented with metallic IOFB, 14 patients were male and 2 patients were female, most of these patients were injured while stone cutting and striking metal with metal, these patients had work related injuries.

FIG 1 Bscan shows metallic IOFB with after shadow effect.

5(23%) patients had vitreous haemorrhage with IOFB, these patients underwent vitrectomy with IOFB removal and endolaser. All these patients had 6/60 to 6/36 after surgery. One patient developed giant retinal tear so underwent re-vitrectomy with silicone oil tamponade, after three months patient developed complicated cataract, cataract extraction with PC IOL implantation and silicone oil removal done. After 3 months of silicone oil removal his BCVA was 6/60.

6 (28%) patients had VH, IOFB and localised retinal detachment, all these patients underwent vitrectomy, IOFB removal, endolaser and silicone oil endotamponade. Silicone oil was removed after 3 months, BCVA in this patients after removal of silicone oil was 3/60 to 6/60.

3 (14%) patients had VH, 7mm metallic IOFB, subtotal retinal detachment, IOFB was intra retinal, patients underwent lensectomy, vitrectomy, limbal approach for IOFB removal, endolaser before removal of IOFB and silicone oil tamponade. Immediate post operative period retina was on after 4 weeks patient came with retinal folds at foreign body site, retina was elevated, patients with folds near disc and posterior pole had poor anatomical and visual outcome. Second procedure done to unfold retina under silicone oil, visual outcome was 1/60 in one patient and CFCF in patient with macular scar. One patient had retinal incarceration in infero temporal area with folds in posterior pole, after realising this incarceration, macular folds were disappeared, his BCVA was 1/60. These three patients had silicone oil in eye for more than 9 months.

One male boy, 2 years old presented with vitreous haemorrhage and IOFB, history of trauma with iron rod, alleged to sustain injury at home due to accidental fall on iron rod. Patient underwent vitrectomy with IOFB removal, post operative period fundus examination revealed temporally pale disc and pale retina.

Patients with wooden IOFB were four (19.0%), all patients were male and had history of trauma in fields they were involved in agriculture related work, they were middle age men, these patients presented with vegetative material in eye on retina and severe endophthalmitis. These patients underwent vitrectomy with IOFB removal and intravitreal antifungals, in this patients anatomical outcome was good but the visual outcome was in two patients 3/60 after 12 weeks. On examination disc was pale. Other two patients had 6/60 to 6/24.

One young boy 16 yrs old presented with glass piece nasal to optic disc, VH, and traumatic cataract, patient underwent lensectomy, vitrectomy and IOFB removal after 3 months SFIOL was implanted, his BCVA was 6/18. 2 young male patients presented with panophthalmitis and retained IOFB, BCVA in these patients was no perception of light, advised destructive procedure (FIG 2 and 3 clinical photo showing signs of endophthalmitis)

VI. Discussion:

40 % of penetrating ocular trauma associated with intraocular foreign bodies, mostly metallic and less commonly vegetable material and glass.¹

In our study also 16 (76%) patients had metallic IOFB, 14(66%) patients had vitreous haemorrhage and 2(9.5%) patients endophthalmitis. Metallic IOFB will enter with high speed and they are sterile due to heat, so less likely to cause endophthalmitis, in our study two cases had severe endophthalmitis, one patient progressed to panophthalmitis. Endophthalmitis in these cases was due to delayed wound repair, so most important thing is wound integrity, immediate wound repair can prevent endophthalmitis. Patients with delayed presentation have poor prognosis.

Patient with vegetable material had severe endophthalmitis, these patients had good anatomical outcome but the visual outcome was not good. Due to severe endophthalmitis risk of endophthalmitis retinopathy is high.

Ocular imaging is very important to plan the surgery, approach for removal of IOFB, all cases underwent b scan and ct scan for the location, size and type of IOFB. (FIG 4 Axial section of CT Scan showing IOFB).

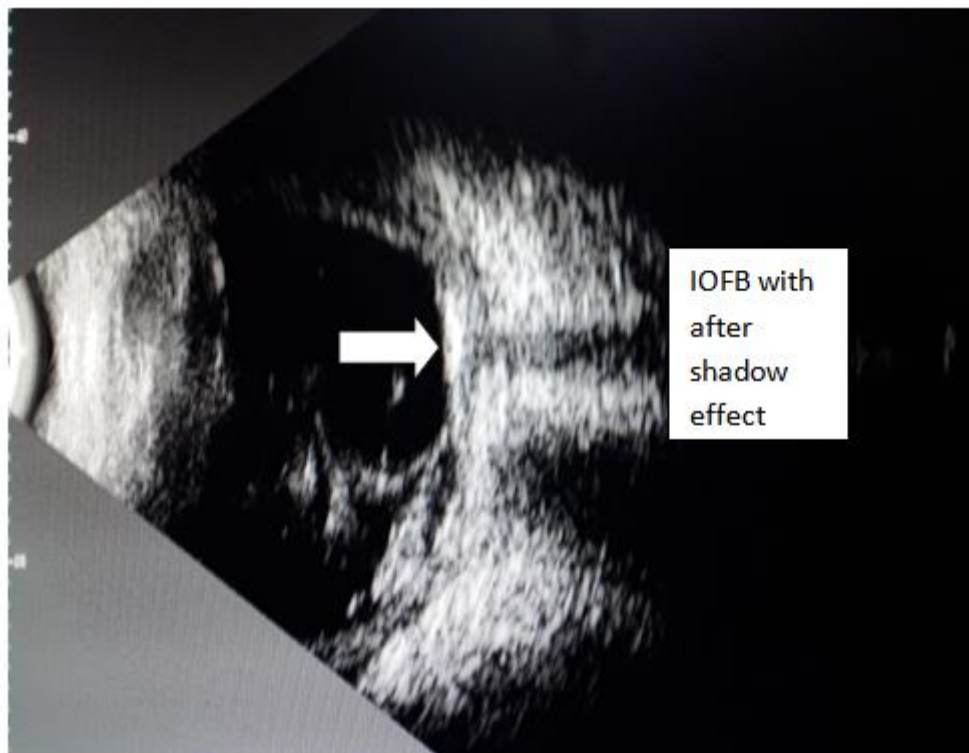
One patient underwent vitrectomy and silicone oil tamponade, patient had IOFB nasally with retinal detachment not involving macula, silicone oil removal was done after 3 months, his BCVA was 6/6, in this case good anatomical and visual outcome was due to early presentation, retinal detachment not involving macula and also early management. Early management will prevent the risk of retinal siderosis, tissue reaction which occurs due to iron deposits from the metallic piece can cause proliferation and gliosis on retina. Degenerative changes on retina due to ferrous deposits can cause scarring and fibrosis. Residual ferrous deposits will cause toxicity in these cases, ERG should be done in these patients with poor visual acuity to detect the toxicity in retinal layers.

VII. Conclusion:

- Management of posterior segment IOFB is challenging condition . Time of surgery , method of surgery , prophylactic intraocular antibiotics , long term follow up are important measures for the favourable outcome.

References:

- [1]. **An overview of penetrating ocular trauma with retained intraocular foreign body**
- [2]. Awwadh Al-Thowaibi, □ Mohan Kumar, and Ibrahim Al-Matani
- [3]. Saudi J Ophthalmol. 2011 Apr; 25(2): 203–205.
- [4]. Published online 2011 Nov 1. doi: 10.1016/j.sjopt.2011.01.0
- [5]. de Juan, E. Jr, Sternberg, P. Jr, and Michels, R.G. Penetrating ocular injuries. Types of injuries and visual results. Ophthalmology. 1983; 90: 1318–1322
- [6]. Pieramici, D.J., MacCumber, M.W., Humayun, M.U. et al. Open-globe injury. Update on types of injuries and visual results. Ophthalmology. 1996; 103: 1798–1803
- [7]. Slusher, M.M., Sarin, L.K., and Federman, J.L. Management of intraretinal foreign bodies. Ophthalmology. 1982; 89: 369–373



Bscan showing optic nerve shadow and above that metallic IOFB on retina with after shadow effect.

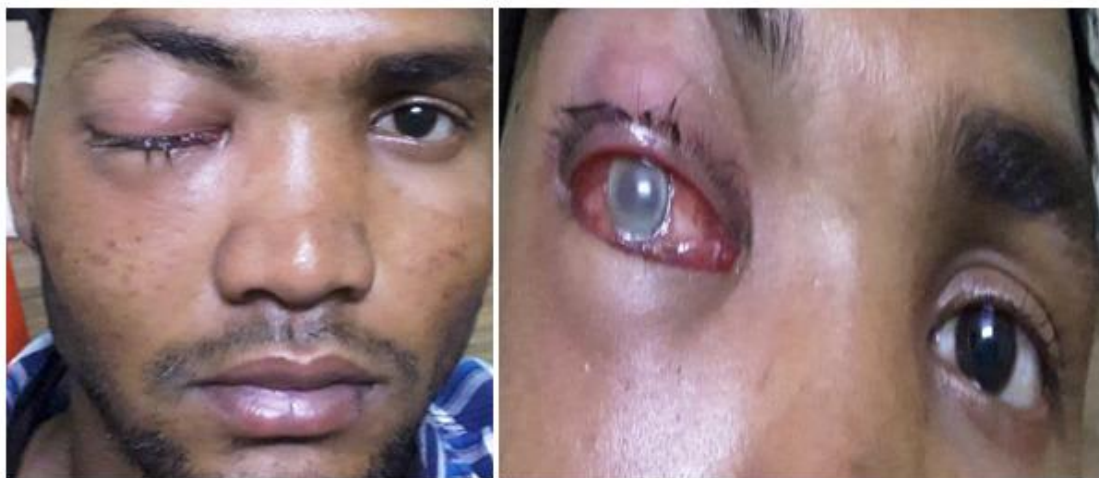

FIG Clinical photo showing signs of endophthalmitis.

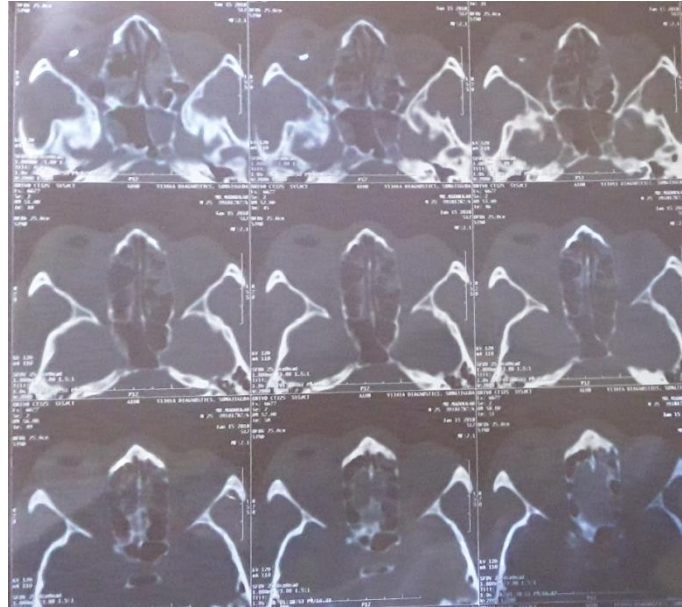

FIG CT Scan showing IOFB.

Dr.Aliya Sultana MS. “Management and outcome of penetrating ocular trauma with intraocular foreign bodies at tertiary centre.”. “IOSR Journal of Dental and Medical Sciences (IOSR-JDMS), Volume 17, Issue 2 (2018), PP 54-57.