

Novel Method to Assess Fetal Head Station in Labour Correlation between clinical method of determination of fetal head station and transperineal ultrasound method of determination of fetal head station

Dr. A. Archana¹, Dr. Usha Rani. G²

¹(Junior Resident, Department of Obstetrics and Gynecology, Sri Ramachandra Medical College/ Deemed University, Chennai, India)

²(Professor and Head of Department, Department of Obstetrics and Gynecology, Sri Ramachandra Medical College/ Deemed University, Chennai, India)

Corresponding Author: Dr. A. Archana

Abstract: Current obstetric practice strives to avoid difficult vaginal deliveries. Digital vaginal examination remains the “gold standard” for identifying the fetal head station and it is highly subjective, experience dependent and has poor reproducibility in determining the position of the fetal head particularly when it is associated with caput succedaneum and asynclitism. Failure of descent is one of the most common indications for performance of surgical deliveries. With advances in ultrasound technology intrapartum transperineal ultrasound has been used to study the progress of labour and to predict vaginal delivery. This removes the problems of poor reproducibility and the difficulties associated with caput and moulding. The aim of our study is to correlate the fetal head station determined by intrapartum transperineal ultrasound and fetal head station determined by digital vaginal examination during full dilation of cervix.

Keywords: Digital vaginal examination, Fetal head station, Transperineal ultrasound

Date of Submission: 16-01-2018

Date of acceptance: 05-02-2018

I. Introduction

Current obstetric practice strives to avoid difficult vaginal deliveries. Digital vaginal examination remains the “gold standard” for identifying the fetal head station. Digital vaginal examination of assessment of progress of labour is highly subjective, experience dependent and has poor reproducibility in determining the progression and position of the fetal head particularly when it is associated with caput succedaneum and asynclitism.

The diagnosis of obstructed labour during the second stage remains a difficult challenge. Failure of descent is one of the most common indications for performance of surgical deliveries. There are difficulties during digital vaginal examination, principally attributed to the fact that the presence of caput or moulding may distort the assessment of fetal head station. With advances in ultrasound technology intrapartum transperineal ultrasound has been used to study the progress of labour and to predict vaginal delivery. This removes the problems of poor reproducibility and the difficulties associated with caput and moulding.

II. Materials and Methods

- 1.1 **Type of study** - Prospective observational study
- 1.2 **Place of study** - Sri Ramachandra Medical College and research centre
- 1.3 **Period of study** - August 2015 to August 2017.
- 1.4 **Sample size** – 300 parturients
- 1.5 **Inclusion criteria** – Nulliparous women, term gestation, singleton pregnancies, occipito anterior and transverse position, Cesarean section done for arrest of descent.
- 1.6 **Exclusion Criteria** – Multiple gestation, multifetal gestation, occipito posterior position, Cesarean sections done for other than arrest of descent.
- 1.7 **Aim of the study** - The aim of our study is to correlate the fetal head station determined by intrapartum transperineal ultrasound and fetal head station determined by digital vaginal examination during full dilation of cervix.
- 1.8 **Method of study** - Institutional review board approval was obtained for the study. Three hundred low risk women with singleton pregnancies, in active labour, were recruited into the study after informed consent. Routine maternal and fetal monitoring was performed as in all other patients. Progress of labour was

monitored by digital evaluation and active management of labour was done with amniotomy and oxytocin infusion when indicated. Transperineal ultrasound was done at full dilation of cervix. Using the convex transabdominal transducer, with patient in lithotomy position, with an empty bladder, the presenting part was confirmed by transabdominal scan. Then trans-perineal ultrasound was performed to determine the fetal head station [fig 1]. Correlation between ultrasound determined fetal head station and clinically determined fetal head station was studied.

1.1 **Fetal head station** - Fetal head station is defined as the relationship of most distal point on fetal head to the ischial spines. A perpendicular line is dropped from the inferior edge of the pubic symphysis making 90° with the axis of the symphysis pubis. Ischial spine is at 3 cms caudal to this line

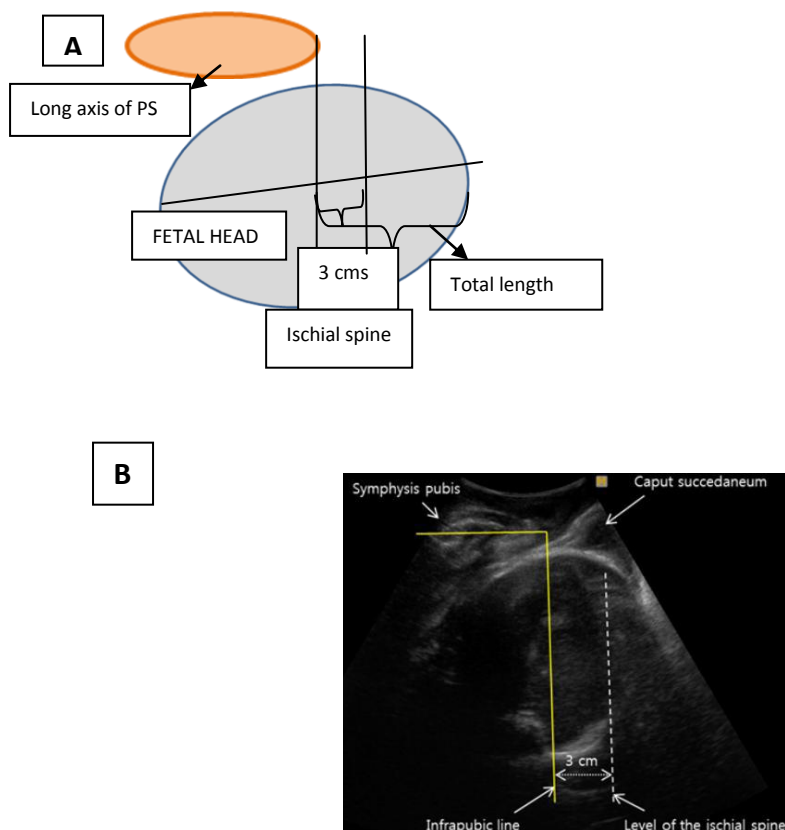


Fig 1: Fetal head station - Correlation between the infrapubic line and ischial spine: the parallel line running through the projected level of the ischial spines (dotted line) lies 3 cm caudal to the infrapubic line. Fig A – Schematic representation of fetal head station. Fig B – 2D ultrasound depicting the measurement of fetal head

III. Results

In our study the correlation of transperineal ultrasound determined fetal head station and clinically determined fetal head station was assessed. A total of 300 low risk primiparae women with singleton pregnancies at term were included in the study. The station of the fetal head was determined during full dilation of the cervix by vaginal examination and by transperineal ultrasound method. Scatter plot was used to find out the statistical correlation between clinical and ultrasound determined fetal head station and it showed good correlation between the two variables [fig 2]. Of the 300 parturients who were examined clinically at full dilation, 254 parturients were at +2 station, 16 were in +1 station, 14 were in 0 station and 16 were in +3 station. Of the 254 women who were in +2 station by clinical evaluation 201 were found to be +2 by ultrasound examination. In the remaining 53 women who were in +2 station by clinical examination, 49 of them were at +3 station by USG and 4 were in +1 station by USG., The distribution of fetal head station during 9 – 10 cms of cervical dilation is described in the table below (table 1).

Of the 300 parturients, 286 women delivered vaginally, 14 parturients underwent caesarean section for arrest of descent. These 14 women who underwent LSCS had station of) at full dilation both by clinical and by USG evaluation.

Pearson correlation was analysed to determine the correlation between two variables (ultrasound and clinically detected fetal head station) which showed good correlation.

In our study 17/300(5.6%) had caput during evaluation at full dilation of cervix. We also observed that when there is associated caput or moulding, the vaginal examination was difficult to determine the station of the fetal head. Ultrasound evaluation of fetal head station had no difficulty in determining the head station. This is because the caput or moulding could be easily delineated from the fetal skull.

The ROC curve for determination of head station when associated with caput showed an area under curve of 0.782 for vaginal and 0.792(P <0.05) for ultrasound detected fetal head station[fig 4].

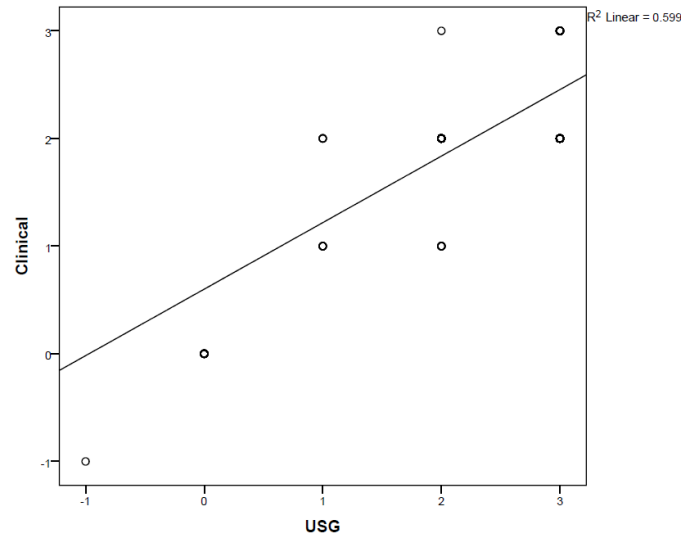


Fig 2: Scatter plot illustrating the correlation of fetal head station determined by intrapartum transperineal ultrasound and clinical method

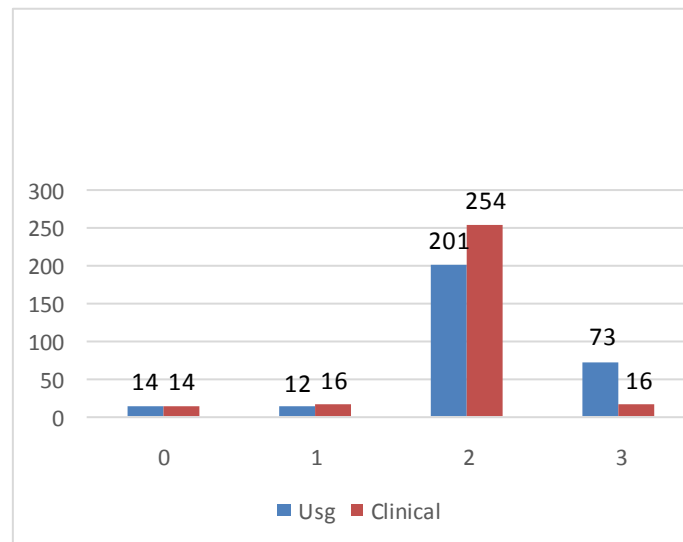


Fig 3: Bar diagram representing the various range of fetal head station at 9 – 10 cms of cervical dilation determined by clinical and ultrasound method

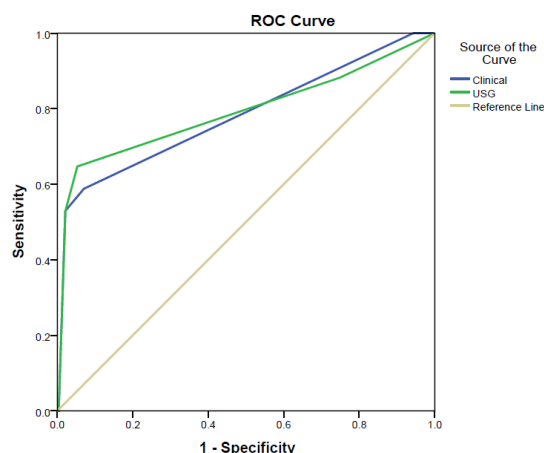


Fig 4: ROC curve to determine the significance of intrapartum transperineal ultrasound in presence of caput succedaneum.

IV. Conclusion

Digital examination for cervical assessment is inexpensive and very useful expert hands. However it is experience dependent, highly subjective and not recordable. Trans-perineal ultrasound is a useful objective evaluation for determination of fetal head station. In the presence of caput, intrapartum transperineal ultrasound was helpful in determining the fetal head station. Ultrasound evaluation fetal head station has a place in obstetric armamentarium whenever there is a dilemma in deciding between a caesarean section and instrumental delivery. In our study the ultrasound and the clinically determined fetal head station is well correlating with each other and was statistically significant(pearson correlation).

References

- [1]. Dupuis.o, Silveina. R, Zenter A, Birth simulator: Reliability of transvaginal assessment of fetal head station as defined by AICOG 2005.
- [2]. Buchmann E – Interobserver agreement in intrapartum estimation if fetal haed station, International Journal of gynaecology and obstetrics, 2008.
- [3]. T. Ghi, Diagnosis of station and rotation of the fetal head in the second stage of labour with intrapartum translabial ultrasound, J ultrasound obstetrics and gynaecology, 2009.
- [4]. B Tutschek, T Braun, A study of progress of labour using intrapartum translabial ultrasound, assessing head station, direction and angle of descent. 2010.
- [5]. Lewin D, Sdoul G, Beuret T, Measuring the height of a cephalic presentation: an objective measurement of station, Europe journal of obstetrics and gynaecology, 1977.

Dr. A. Archana "Novel Method to Assess Fetal Head Station in Labour Correlation between clinical method of determination of fetal head station and transperineal ultrasound method of determination of fetal head station." IOSR Journal of Dental and Medical Sciences (IOSR-JDMS), vol. 17, no. 2, 2018, pp. 01-04.