

## Pediatric cataract-Etiology and clinical diagnosis

Dr. Jitendra kumar<sup>1</sup>, Dr. Arti Kushwaha<sup>2</sup>

<sup>1</sup>(Department of Ophthalmology, MLB Medical college / Bundelkhand University, India)

<sup>2</sup>(Department of Ophthalmology, MLB Medical college/ Bundelkhand University, India)

Corresponding author: Dr. Jitendra kumar

**Abstract:** *Cataract is a significant cause of visual disability in the pediatric population worldwide and can significantly impact the neurobiological development of a child. Early diagnosis and prompt surgical intervention is critical to prevent irreversible amblyopia. Thorough ocular evaluation, including the onset, duration, and morphology of a cataract, is essential to determine the timing for surgical intervention. Detailed assessment of the general health of the child, preferably in conjunction with a pediatrician, is helpful to rule out any associated systemic condition. Although pediatric cataracts have a diverse etiology, with the majority being idiopathic, genetic counseling and molecular testing should be undertaken with the help of a genetic counselor and/or geneticist in cases of hereditary cataracts. Advancement in surgical techniques and methods of optical rehabilitation has substantially improved the functional and anatomic outcomes of pediatric cataract surgeries in recent years. However, the phenomenon of refractive growth and the process of emmetropization have continued to puzzle pediatric ophthalmologists and highlight the need for future prospective studies. Posterior capsule opacification and secondary glaucoma are still the major postoperative complications necessitating long-term surveillance in children undergoing cataract surgery early in life. Successful management of pediatric cataracts depends on individualized care and experienced teamwork. We reviewed the etiology, preoperative evaluation including biometry, choice of intraocular lens, surgical techniques, and recent developments in the field of childhood cataract.*

**Keywords:** *children, pediatric cataract, infantile cataract, aphakia, pseudophakia*

Date of Submission: 21-01-2018

Date of acceptance: 05-02-2018

### I. Introduction

Pediatric cataract is one of the major causes of preventable childhood blindness, affecting approximately 200,000 children worldwide, with an estimated prevalence ranging from three to six per 10,000 live births.<sup>1-3</sup> Pediatric cataracts may be congenital if present within the first year of life, developmental if present after infancy, or traumatic. Early diagnosis and treatment are of crucial importance to prevent the development of irreversible stimulus-deprivation amblyopia. The management of pediatric cataract should be customized depending upon the age of onset, laterality, morphology of the cataract, and other associated ocular and systemic comorbidities.

Recent advances in surgical techniques, intraocular lens (IOL) composition and designs, increased understanding about the neurobiology of visual development, and early postoperative use of contact lenses for optical rehabilitation have contributed to improved outcomes after pediatric cataract surgery. Furthermore, early diagnosis can be achieved by genetic counseling and testing in cases of hereditary cataracts.<sup>4</sup>

However, certain issues specific to pediatric eyes, such as increased postoperative inflammation, axial growth after cataract extraction, implant-power calculation, secondary glaucoma, posterior-capsule opacification (PCO), and amblyopia management are still major obstacles to achieving good visual outcomes in childhood cataract surgery.<sup>5-9</sup>

### II. Genetics

The eye starts developing at 22 days of gestation. Fibroblast growth factor (FGF) induces migration, differentiation, and is also responsible for the polarity of the lens.<sup>10</sup> Bone morphogenetic protein interacts with FGF during lens induction. The proteins encoded by genes Pax6, Pitx3, c-Maf, and Foxe3 are transcription factors which are crucial for lens development.<sup>11</sup> The mutations are most commonly autosomal dominant, and absence of the function of one copy has a severe effect on lens development.<sup>12</sup> The timing of insult results in involvement of the part of lens developing during that period. Congenital cataract is hereditary in 8.3%–25% of cases, with 75% being autosomal dominant inheritance.<sup>13</sup> Autosomal-dominant cataracts have varying amounts of penetrance. Autosomal dominant cataract includes hyperferritinemia cataract syndrome, Coppock-like, Volkmann-type congenital, zonular with sutural, posterior polar, anterior polar, cerulean, zonular pulverulent, crystalline aculeiform, and myotonic dystrophy 1-like cataracts. Autosomal-recessive cataract

includes Warburg micro syndrome, Hallermann-Streiff syndrome, Martsolf syndrome, Smith-Lemli-Opitz syndrome, Rothmund-Thomson syndrome, Marinesco-Sjogren syndrome, Wilsons disease, and congenital cataract facial dysmorphism and neuropathy. X-linked recessive cataract includes Nance Horan syndrome (NHS) and Norrie’s disease.<sup>14,15</sup> Crystallin and Connexin gene mutations are the most commonly described nonsyndromic inherited cataracts. Alpha-crystallin gene mutation results in nuclear, lamellar, zonular, and posterior polar cataracts.<sup>16</sup> Crystallin gene mutation presents with variable phenotypic presentations. Anterior polar cataracts are seen with PAX6 mutations whereas PITX3 mutations mainly cause posterior polar cataracts.<sup>17</sup> Other genes responsible for major syndromic cataracts include OCRL (Lowe syndrome),<sup>18</sup> GALK117q (galactosemia),<sup>19</sup> GLA (Fabry’s disease),<sup>20</sup> and NHS (Nance-Horan cataract-dental syndrome).<sup>21</sup>

**Morphology of pediatric cataract: specific diagnostic**

A detailed description of the morphology of a pediatric cataract may not only help in the diagnosis of a specific condition but also in planning the management with regard to surgical as well as nonsurgical treatment. Morphologically, pediatric cataracts can be broadly classified into the cataracts involving the entire lens, central cataracts, anterior cataracts, posterior cataracts, punctate lens opacities, coralline cataracts, sutural cataracts, wedge-shaped cataract, and cataracts associated with PFV.<sup>22</sup> In this review, we want to highlight cataracts with typical morphology specific to certain systemic conditions or syndromes that may be helpful to diagnosis.

Total cataracts can be sporadic or hereditary in nature (Figure 1); they can also be seen in Down’s syndrome and congenital rubella syndrome (Figure 2).<sup>22</sup> Zonular cataract is the commonest type of congenital cataract (figure 3)

Early surgical intervention is mandatory to prevent the development of amblyopia.

Anterior polar cataracts are not pathognomonic of any particular condition, but are commonly seen in patients with aniridia (Figure 4A). They can appear as dot-like, plaque-like, or in the form of a pyramid. Pyramidal cataracts are the severe form of anterior capsulolenticular opacities in the form of a pyramid protruding into the anterior chamber, and have also been described in children with retinoblastoma and Ehlers–Danlos syndrome (Figure 4B).<sup>23,24</sup>

Anterior subcapsular cataracts are associated with uveitis, trauma, irradiation, and atopic dermatitis. Anterior lenticonus is a bilateral condition seen in Alport syndrome, and rarely in Waardenburg syndrome.<sup>25,26</sup>

Oil-droplet cataracts are the nuclear opacities typically seen in infants with galactosemia (Figure 5). However, other forms of cataract, such as posterior subcapsular or small nuclear and cortical opacification, are also described in galactosemia.<sup>27</sup> The changes are reversible with early dietary modification.

Sunflower cataract is a type of anterior subcapsular cataract almost only seen in Wilson’s disease, an autosomal-recessive condition with a defect in the metabolism of copper leading to accumulation of copper in the liver and basal ganglia. These lenticular opacities are also reversible with treatment with penicillamine.<sup>28</sup>

Posterior subcapsular cataract can be drug-induced (steroids most commonly) or a complication of radiation therapy for ocular and periocular tumors.<sup>29,30</sup> It has also been reported in systemic conditions, such as Turner’s syndrome, Fabry’s disease, Bardet–Biedl syndrome, and neurofibromatosis type 2.<sup>31-35</sup>

Membranous cataracts are the disk-like opacities formed after spontaneous resorption of lens material. These are typically seen in Hallermann–Streiff syndrome.<sup>36</sup> This condition has also been described in children with congenital rubella syndrome, Lowe syndrome, and PFV.<sup>37-39</sup> Wedge-shape cataracts are partial lenticular opacities, typically associated with Stickler syndrome in addition to Conradi–Hünemann syndrome, neurofibromatosis type 2, and Fabry’s disease.<sup>22,40</sup>

Punctate cortical opacities sparing the nucleus are characteristically seen in carriers of X-linked recessive Lowe syndrome and in children with Down’s syndrome.<sup>22,41</sup> Radiating spoke-like cortical punctate opacities are also consistent with Fabry’s disease.<sup>32</sup>

Sutural cataracts are visually insignificant opacities along the Y-sutures of the lens. They are often found as an incidental finding on routine examination. They have been described in female carriers of Nance–Horan syndrome, with affected males presenting with dense visually significant cataracts.<sup>21</sup>

**Morphology of cataract**

Whole lens	Central	Anterior	Posterior	Miscellaneous
Total	Lamellar	Anterior polar	Mittendorf dots	Punctate lens opacities
Congenital orgagnian	Central pulverulent	Dot like	Posterior cortical	Sutural
Membranous	Ant egg	Plaque like	Posterior subcapsular	Coralliform
	Nuclear	Anterior pyramidal	Posterior lenticonus	Wedge shaped
	Oil droplet	Anterior subcapsular		Persistent hyperplastic
	Cortical	Anterior lenticonus		primary vitreous
	Coronary			

### **III. Examination of the child**

#### **History taking**

The first complaint is often leukocoria, which the parent notices either total or gradual increase in the size of opacity. The second is child not following object close to face or not making eye contact (inability to recognize mother). The parent may also complain of squeezing of eye in bright light, squinting of eyes, small eyes (microphthalmos), large eyes (buphthalmos), and abnormal movement of the eyes (nystagmus). A detailed history is taken that includes asking about the age of onset and duration of symptoms. Older children may present with difficulty in viewing distant objects, teacher may notice child not being able to read blackboard, or the parent may notice child bringing things very close to face and viewing television at close distance. A similar history in sibling or family member already diagnosed with cataract should be sought and a pedigree chart should be made. The history of fever and rash during pregnancy (TORCH), consumption of any drugs or alcohol, and trauma in case of unilateral cataract should be looked for. The history of trauma during delivery, preterm delivery (retinopathy of prematurity), failure to thrive, and vomiting (galactosemia) should also be elicited. The delay in normal visual milestones should raise a high degree of suspicion in cases of hereditary cataract. In case of trauma, the mode of injury should be inquired which helps to ascertain the severity of injury.

#### **Systemic examination**

Children with cataract often present with systemic illness and syndromic features. Gross general examination may show dysmorphic features with sparse eyebrows, mongoloid slant (Down's syndrome), beaked nose with dental abnormalities (Hallermann–Streiff syndrome), frontal bossing (Lowe syndrome), low-set ears, and prominent parietal and occipital eminences; skin and hair changes such as dry scaly skin over the limbs, abdomen, and scalp with patchy alopecia; skeletal changes such as upper limb flexion deformity of a middle finger, the disproportionate length of upper and lower limbs, and calcaneus valgus deformity (Conradi–Hünemann syndrome), tall stature (Marfan's syndrome), camptodactyly (Beal's syndrome), short stature, and brachydactyly (Weill–Marchesani syndrome). The skull sutures are sometimes irregularly fused, the face shows puffiness (nephrotic syndrome), skin may show pigmentation (xeroderma pigmentosa), and absent eyebrows (Patau's syndrome). Head circumference measurement may show hydrocephalus or microcephaly, both are associated with cataract. Attention-deficit hyperactivity syndrome can be seen in William's syndrome. Subnormal mentation and retardation can be associated with many syndromes. Auscultation may reveal patent ductus arteriosus (rubella) or mitral valve prolapse (Ehler–Danlos syndrome).<sup>42-45</sup>

#### **Ocular examination**

A detailed ocular examination is carried out either in the office or in the operating room. This should include slit-lamp biomicroscopy to assess the size, location, density of lenticular opacity, capsular changes, such as preexistent posterior capsular defects, and other associated anterior-segment developmental anomalies. In addition, measurement of intraocular pressures and corneal diameters are performed. Fundus examination in partial cataracts and ultrasound examination in total cataracts may reveal posterior-segment abnormalities that may affect the visual outcome. Ultrasound biomicroscopy can be informative in children with anterior-segment developmental anomalies and PFV, and also in the assessment of posterior capsular support while considering secondary IOL implantation (Figure 1).<sup>46-48</sup> In children under 12 months of age, it is sometimes possible to examine them after they have been fed milk.

In preverbal children who are uncooperative for standard visual acuity testing, fixation behavior, fixation preference, and objection to occlusion should be checked. In younger infants with poorly developed fixation, a red reflex test can be performed in a darkened room with a direct ophthalmoscope along with undilated retinoscopy to assess the visual significance of the lens opacity. A central cataract larger than 3 mm in diameter, unilateral cataract associated with strabismus, and bilateral cataract with nystagmus are considered visually significant.<sup>49</sup> Asking about the visual interaction of the child at home with the family members, also helps in determining the severity of visual dysfunction.

It is important to check the visual acuity in older cooperative children, if possible with preferential looking cards (Teller acuity card, Keeler, etc), or other vision tests such as "E" charts or Snellen chart appropriate to the age of the child. In cases of lamellar or posterior subcapsular cataracts, the visual acuity in an examination lane with dim light may appear normal or reasonable, but glare testing where visual acuity drops by two or more lines, will reveal potential difficulty in daylight. The glare test is performed by shining a bright light to the side of each eye as the child attempts to read the vision chart.

#### **Investigations**

Ultrasonography (USG) not only helps in intraoperative management, but also in prognosticating a case, especially in cases with unilateral cataract. USG helps us rule out retinal detachment, fundal coloboma, and retinoblastoma.<sup>50</sup> USG in a case of unilateral cataract can diagnose a PFV.<sup>51</sup> Magnetic resonance imaging

can be ordered if there is a high degree of suspicion of PFV which is missed on USG. Color Doppler also shows flow picture in case of a PFV. X-ray is done in cases of traumatic cataract and computed tomography scan to localize an intraocular foreign body.<sup>52</sup> TORCH profile in case of bilateral congenital cataract can be ordered to look for active infection.<sup>53</sup> Echocardiography in cases such as Marfan's syndrome and rubella may reveal aortic regurgitation, aortic root dilation, patent ductus arteriosus, and atrial septal defect. In cases of JIA and juvenile rheumatoid arthritis needing immunosuppressant medications, a rheumatologist's opinion is sought. A neurologist should be consulted in cases of seizure and gross developmental delay. Nephrology evaluation should be done in cases of nephrotic syndrome and Lowe syndrome.<sup>54</sup>

Preoperative evaluation: Biometry

### **Axial length and Keratometry**

Optical correction after pediatric cataract surgery may be achieved by aphakic glasses, contact lenses, or primary IOL implantation. Because of the myopic shift over a period of time, it is essential to predict eye growth and have an accurate biometry in order to choose the appropriate IOL power suited for each child at the time of surgery and well into the future. Accurate measurements of axial length and keratometry in the office setting may be difficult because of poor patient cooperation and poor fixation, and most of the time biometry has to be performed under sedation or general anaesthesia in the operating room. Immersion biometry has been shown to be more predictable than the contact method for IOL-power calculation in children.<sup>55</sup>

### **IOL power calculation**

IOL power calculation is multifactorial. The eye is dynamic in nature with constant change in children. Hence, predicting the right power for the child's eye is difficult and often confusing. The IOL power depends on various factors which include the age of presentation, morphology of cataract, visual acuity at presentation, time of development of cataract (congenital/developmental), biometry at presentation, unilateral or bilateral cataract, and refractive status of the fellow eye.<sup>56</sup> IOL can be implanted in eyes with AL >17 mm and corneal diameter >10 mm. The initial desired refractive outcome after IOL implantation is moderate hypermetropia to avoid undesired myopic shift in adulthood. Dahan and Drusedau suggested undercorrection of 20% in children <2 years and 10% in children between 2 and 8 years.<sup>57</sup> Prost suggested 20% undercorrection between 1 and 2 years of age, 15% undercorrection between 2 and 4 years, and 10% between 4 and 8 years of age.<sup>58</sup> Enyedi suggested postoperative target refraction to be used for IOL power calculation according to age (age + postoperative refraction = 7).<sup>59</sup> Intraoperative aphakic refraction or aberrometry can be used to calculate the IOL power. SRK/T and the Holladay 2 formulae have been shown to have the least predictive error.<sup>60</sup>

### **Choice of intraocular lens**

In recent years, acrylic IOLs have gained popularity over polymethyl methacrylate (PMMA) IOLs, which had remained the IOL of choice for many years.<sup>61</sup> In children AcrySof IOLs are considered better than PMMA IOLs in terms of greater biocompatibility and smaller incision size with use of foldable design, with late onset and lower rate of PCO formation. Hydrophobic acrylic IOLs are used by 93% of pediatric cataract surgeons. The one-piece lenses (SA or SN series) for in-the-bag fixation and three-piece lenses (MA series) for sulcus fixation are preferred.<sup>61</sup> In children with uveitic cataracts, decreased postoperative inflammation has been reported with the use of heparin-surface-coated PMMA IOLs.<sup>62</sup> Silicone IOLs are used less frequently, because of an increased rate of capsule contraction.<sup>63</sup> The "Perfect" IOL would have a hydrophilic anterior surface and a hydrophobic posterior surface.<sup>64</sup> The indications for multifocal IOLs in children are debatable. Simultaneous distance and near vision without the aid of glasses or contact lenses can be achieved with the use of multifocal IOLs. Multifocal IOLs may help in establishing stereopsis in unilateral cases, but the contrast and brightness of the images get compromised.<sup>65</sup> There may be significant myopic shift and subsequent refractive error, hence they are more suitable to teenagers.

## **IV. Management**

### **Nonsurgical management**

Indication for cataract surgery depends upon how much visual function is affected. The mere presence of a lenticular opacity does not indicate surgical removal. Peripheral lens opacities, punctate opacities with intervening clear zones, and opacities less than 3 mm in diameter can be observed closely and successfully managed by treating the associated amblyopia by patching and glasses.<sup>66</sup> For example, anterior polar and pyramidal cataracts are not visually significant per se, but can be associated with significant progressive corneal astigmatism, which can lead to decreased visual acuity and amblyopia.<sup>67</sup> In addition, in small central opacities, a larger area of clear visual axis can be achieved by pharmacological dilatation.<sup>68</sup>

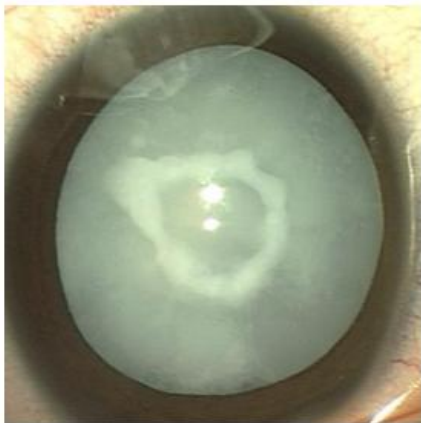
Surgical management

Timing of surgery

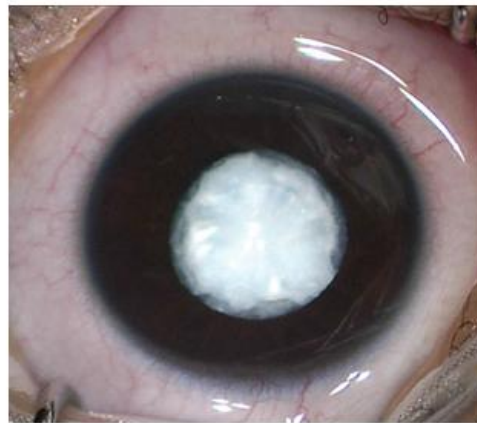A critical period for visual development has been described in the first 6 weeks of life, during which the vision is subcortically mediated and the infant is relatively resistant to amblyopia.<sup>69</sup> Extraction of unilateral congenital cataracts by 4–6 weeks and bilateral congenital cataracts within the first 6–8 weeks of life can prevent the development of stimulus-deprivation amblyopia, strabismus, and nystagmus.<sup>70,71</sup> Prompt optical rehabilitation and occlusion therapy can result in good visual acuity with fusion and stereopsis.<sup>72</sup>

**V. Cataract surgery in children**

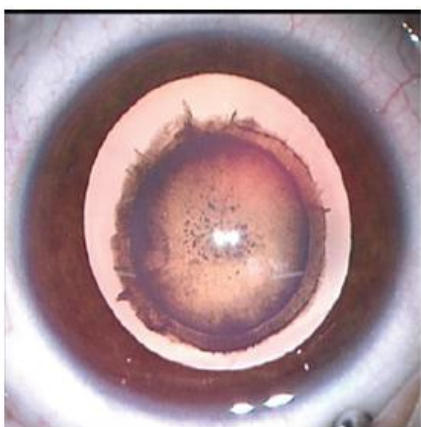
Management of childhood cataracts remains complex. The physiology and anatomy of the growing eyes of children are so different from those of adults that unique applications of modern technology are needed to maximize outcomes. Low scleral rigidity, increased elasticity of the anterior capsule, and high vitreous pressure are among the major obstacles that interfere with the highly demanding surgery. Even the best of surgeons can be humbled by the challenges of the small, soft, poorly developed eyes that require cataract surgery. Intraoperative problems coupled with a risk for increased postoperative inflammation, a changing refractive state, higher re-surgery rate and an inherent risk of amblyopia make cataract surgery in children more complex which thus have an effect on final visual outcome. Historically, several primitive surgical techniques such as surgical iridectomy,<sup>73,74</sup> needling, and needling and aspiration were used for cataract surgery in children and a few of them are even today in practice in many parts of the developing world. Phacoaspiration with primary posterior capsulotomy with or without anterior vitrectomy and capsular bag implantation/optic capture of intraocular lens<sup>75,76</sup> is today the most accepted technique followed while performing pediatric cataract surgery.



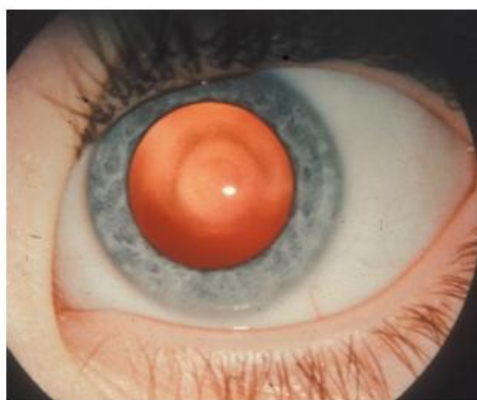
**Figure 1** Total cataract with central anterior capsular plaque.



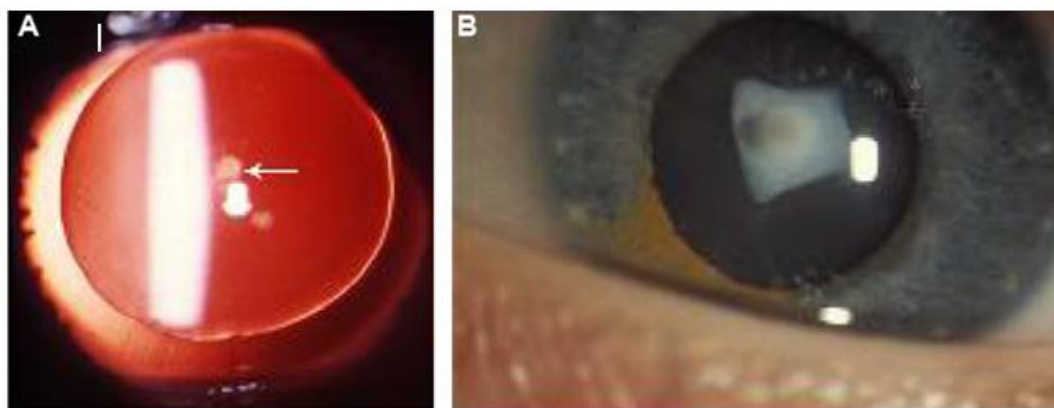
**Figure 2** -4monthsold child with congenital rubella syndrome presenting with membranous cataract.



**Figure 3**-Zonular cataract with riders



**Figure 5** Oil-droplet cataract in galactosemia.



**Figure 4-**Anterior polar cataract. (A) Aniridia with dot-like anterior polar cataract (arrow); (B) pyramidal cataract.

### References

- [1]. Foster A, Gilbert C, Rahi J. Epidemiology of cataract in childhood: a global perspective. *J Cataract Refract Surg.* 1997;23 Suppl 1:601–604.
- [2]. Holmes JM, Leske DA, Burke JP, Hodge DO. Birth prevalence of visually significant infantile cataract in a defined US population. *Ophthalmic Epidemiol.* 2003;10(2):67–74.
- [3]. Stayte M, Reeves B, Wortham C. Ocular and vision defects in preschool children. *Br J Ophthalmol.* 1993;77(4):228–232.
- [4]. Lee KA, Park MH, Kim YJ, Chun SH. Isolated congenital hereditary cataract in a dizygotic twin: prenatal ultrasonographic diagnosis. *Twin Res Hum Genet.* 2013;16(5):994–997.
- [5]. Vasavada AR, Raj SM, Nihalani B. Rate of axial growth after congenital cataract surgery. *Am J Ophthalmol.* 2004;138(6):915–924.
- [6]. Jasman AA, Shaharuddin B, Noor RA, Ismail S, Ghani ZA, Embong Z. Prediction error and accuracy of intraocular lens power calculation in pediatric patient comparing SRK II and Pediatric IOL Calculator. *BMC Ophthalmol.* 2010;10:20.
- [7]. Kekunnaya R, Gupta A, Sachdeva V, Rao HL, Vaddavalli PK, Om Prakash V. Accuracy of intraocular lens power calculation formulae in children less than two years. *Am J Ophthalmol.* 2012;154(1):13–19.e2.
- [8]. Mataftsi A, Haidich AB, Kokkali S, et al. Postoperative glaucoma following infantile cataract surgery: an individual patient data meta-analysis. *JAMA Ophthalmol.* 2014;132(9):1059–1067.
- [9]. Lim Z, Rubab S, Chan YH, Levin AV. Management and outcomes of cataract in children: the Toronto experience. *J AAPOS.* 2012; 6(3):249–254.
- [10]. Lovicu FJ, McAvoy JW, de Iongh RU. Understanding the role of growth factors in embryonic development: Insights from the lens. *Philos Trans R Soc Lond B Biol Sci* 2011;366:1204–18.
- [11]. Cvekl A, Duncan MK. Genetic and epigenetic mechanisms of gene regulation during lens development. *Prog Retin Eye Res* 2007;26:555–97.
- [12]. Hejtmancik JF. Congenital cataracts and their molecular genetics. *Semin Cell Dev Biol* 2008;19:134–49.
- [13]. Santana A, Waiswo M. The genetic and molecular basis of congenital cataract. *Arq Bras Oftalmol* 2011;74:136–42.
- [14]. Huang B, He W. Molecular characteristics of inherited congenital cataracts. *Eur J Med Genet* 2010;53:347–57.
- [15]. Reddy MA, Francis PJ, Bery V, Bhattacharya SS, Moore AT. Molecular genetic basis of inherited cataract and associated phenotypes. *Surv Ophthalmol* 2004;49:300–15.
- [16]. Francis PJ, Moore AT. Genetics of childhood cataract. *Curr Opin Ophthalmol* 2004;15:10–5.
- [17]. Burdon KP, McKay JD, Wirth MG, Russell-Eggitt IM, Bhatti S, Ruddle JB, et al. The PITX3 gene in posterior polar congenital cataract in Australia. *Mol Vis* 2006;12:367–71.
- [18]. Bökenkamp A, Ludwig M. The oculocerebrorenal syndrome of Lowe: An update. *Pediatr Nephrol* 2016;31:2201–12.
- [19]. Atik SU, Gürsoy S, Koçkar T, Önal H, Adal SE. Clinical, molecular, and genetic evaluation of galactosemia in Turkish children. *Turk Pediatr Ars* 2016;51:204–9.
- [20]. Schiffmann R. Fabry disease. *Handb Clin Neurol* 2015;132:231–48.
- [21]. Ding X, Patel M, Herzlich AA, Sieving PC, Chan CC. Ophthalmic pathology of Nance-Horan syndrome: Case report and review of the literature. *Ophthalmic Genet* 2009;30:127–35.
- [22]. Amaya L, Taylor D, Russell-Eggitt I, Nischal KK, Lengyel D. The morphology and natural history of childhood cataracts. *Surv Ophthalmol.* 2003;48(2):125–144. 22. Kostick AM, Romanchuck KG, Beebe DC. Anterior pyramidal cataracts in Ehlers-Danlos syndrome. *Can J Ophthalmol.* 1996;31(3):133–136.
- [23]. Kostick AM, Romanchuck KG, Beebe DC. Anterior pyramidal cataracts in Ehlers-Danlos syndrome. *Can J Ophthalmol.* 1996;31(3):133–136.
- [24]. Brown GC, Shields JA, Oglesby RB. Anterior polar cataracts associated with bilateral retinoblastoma. *Am J Ophthalmol.* 1979;87(3):276.
- [25]. Liu Z, Sun CB, Yao K. Anterior internal lenticonus accompanied by congenital nuclear cataract. *Chin Med J (Engl).* 2011;124(23): 4119–4120.
- [26]. Stevens PR. Anterior lenticonus and the Waardenburg syndrome. *Br J Ophthalmol.* 1970;54(9):621–623.
- [27]. Beigi B, O'Keefe M, Bowell R, Naughten E, Badawi N, Lanigan B. Ophthalmic findings in classical galactosaemia – prospective study. *Br J Ophthalmol.* 1993;77(3):162–164.
- [28]. Ram J, Gupta A. Kayser-Fleischer ring and sunflower cataract in Wilson disease. *JAMA Ophthalmol.* 2014;132(7):873.
- [29]. Suh SY, Kim JH, Kim SJ, Yu YS. Systemic steroid-induced cataracts in children: long-term changes in morphology and visual acuity. *J AAPOS.* 2013;17(4):371–373.
- [30]. Hoehn ME, Irshad F, Kerr NC, Wilson MW. Outcomes after cataract extraction in young children with radiation-induced cataracts and retinoblastoma. *J AAPOS.* 2010;14(3):232–234.



- [31]. Eshagian J, Rafferty NS, Goossens W. Human cataracta complicata. Clinicopathologic correlation. *Ophthalmology*. 1981;88(2):155–163.
- [32]. Sodi A, Ioannidis AS, Mehta A, Davey C, Beck M, Pitz S. Ocular manifestations of Fabry's disease: data from the Fabry Outcome Survey. *Br J Ophthalmol*. 2007;91(2):210–214.
- [33]. Schachat AP, Maumenee IH. Bardet-Biedl syndrome and related disorders. *Arch Ophthalmol*. 1982;100(2):285–288.
- [34]. McLaughlin ME, Pepin SM, Maccollin M, Choopong P, Lessell S. Ocular pathologic findings of neurofibromatosis type 2. *Arch Ophthalmol*. 2007;125(3):389–394.
- [35]. Eshagian J. Human posterior subcapsular cataracts. *Trans Ophthalmol Soc U K*. 1982;102 Pt 3:364–368.
- [36]. Falls HF, Schull WJ. Hallermann-Streiff syndrome, a dyscephaly with congenital cataracts and hypotrichosis. *Arch Ophthalmol*. 1960;63(3): 409–420.
- [37]. Boger WP 3rd, Petersen RA, Robb RM. Spontaneous absorption of the lens in the congenital rubella syndrome. *Arch Ophthalmol*. 1981;99(3): 433–434.
- [38]. Wegener JK, Sogaard H. Persistent hyperplastic primary vitreous with resorption of the lens. *Acta Ophthalmol (Copenh)*. 1968;46(2): 171–175.
- [39]. Tripathi RC, Cibis GW, Tripathi BJ. Pathogenesis of cataracts in patients with Lowe's syndrome. *Ophthalmology*. 1986;93(8):1046–1051.
- [40]. Seery CM, Pruett RC, Liberfarb RM, Cohen BZ. Distinctive cataract in the Stickler syndrome. *Am J Ophthalmol*. 1990;110(2):143–148.
- [41]. Lim Z, Rubab S, Chan YH, Levin AV. Pediatric cataract: the Toronto experience – etiology. *Am J Ophthalmol*. 2010;149(6):887–892
- [42]. Bökenkamp A, Ludwig M. The oculocerebrorenal syndrome of Lowe: An update. *Pediatr Nephrol* 2016;31:2201-12.
- [43]. Roizen NJ, Mets MB, Blondis TA. Ophthalmic disorders in children with Down syndrome. *Dev Med Child Neurol* 1994;36:594-600
- [44]. Trumler AA. Evaluation of pediatric cataracts and systemic disorders. *Curr Opin Ophthalmol* 2011;22:365-79.
- [45]. Mets MB. Eye manifestations of intrauterine infections. *Ophthalmol Clin North Am* 2001;14:521-31
- [46]. El Shakankiri NM, Bayoumi NH, Abdallah AH, El Sahn MM. Role of ultrasound and biomicroscopy in evaluation of anterior segment anatomy in congenital and developmental cataract cases. *J Cataract Refract Surg*. 2009;35(11):1893–1905.
- [47]. De Silva DJ, Nischal KK, Packard RB. Preoperative assessment of secondary intraocular lens implantation for aphakia: a comparison of 2 techniques. *J Cataract Refract Surg*. 2005;31(7):1351–1356.
- [48]. Mackeen LD, Nischal KK, Lam WC, Levin AV. High-frequency ultrasonography findings in persistent hyperplastic primary vitreous. *J AAPOS*. 2000;4(4):217–224.
- [49]. Zetterström C, Lundvall A, Kugelberg M. Cataracts in children. *J Cataract Refract Surg*. 2005;31(4):824–840
- [50]. Kaya A. Preoperative usage of ultrasound biomicroscopy in pediatric cataract. *Arq Bras Oftalmol* 2016;79:62
- [51]. Khokhar S, Tejwani LK, Kumar G, Kushmesh R. Approach to cataract with persistent hyperplastic primary vitreous. *J Cataract Refract Surg* 2011;37:1382-5.
- [52]. Qi Y, Zhang YF, Zhu Y, Wan MG, Du SS, Yue ZZ, et al. Prognostic factors for visual outcome in traumatic cataract patients. *J Ophthalmol* 2016;2016:1748583.
- [53]. Jyoti M, Shirke S, Matalia H. Congenital rubella syndrome: Global issue. *J Cataract Refract Surg* 2015;41:1127.
- [54]. Hacıhamdioğlu DÖ, Kalman S, Gök F. Long-term results of children diagnosed with idiopathic nephrotic syndrome; single center experience. *Turk Pediatri Ars* 2015;50:37-44.
- [55]. Trivedi RH, Wilson ME. Prediction error after pediatric cataract surgery with intraocular lens implantation: contact versus immersion A-scan biometry. *J Cataract Refract Surg*. 2011;37(3):501–50569. Magli A, Forte R, Carelli R, Rombetto L, Magli G. Long-term outcomes of primary intraocular lens implantation for unilateral congenital cataract. *Semin Ophthalmol* 2016;31:548-53.
- [56]. Dahan E, Drusedau MU. Choice of lens and dioptric power in pediatric pseudophakia. *J Cataract Refract Surg* 1997;23 Suppl 1:618-23.
- [57]. Prost ME. IOL calculations in cataract operations in children. *Klin Oczna* 2004;106:691-4.
- [58]. Enyedi LB, Peterseim MW, Freedman SF, Buckley EG. Refractive changes after pediatric intraocular lens implantation. *Am J Ophthalmol* 1998;126:772-81.
- [59]. Zhang Z, Thomas LW, Leu SY, Carter S, Garg S. Refractive outcomes of intraoperative wavefront aberrometry versus optical biometry alone for intraocular lens power calculation. *Indian J Ophthalmol* 2017;65:813-7.
- [60]. Vasavada V, Shah SK, Vasavada VA, Vasavada AR, Trivedi RH, Srivastava S, et al. Comparison of IOL power calculation formulae for pediatric eyes. *Eye (Lond)* 2016;30:1242-50
- [61]. Wilson ME, Trivedi RH. Choice of intraocular lens for pediatric cataract surgery: survey of AAPOS members. *J Cataract Refract Surg*. 2007;33(9):1666–1669
- [62]. Basti S, Aasuri MK, Reddy MK, et al. Heparin-surface-modified intraocular lenses in pediatric cataract surgery: prospective randomized study. *J Cataract Refract Surg*. 1999;25(6):782–787
- [63]. Pavlovic S, Jacobi FK, Graef M, Jacobi KW. Silicone intraocular lens implantation in children: preliminary results. *J Cataract Refract Surg*. 2000;26(1):88–95.
- [64]. Huang Q, Cheng GP, Chiu K, Wang GQ. Surface modification of intraocular lenses. *Chin Med J (Engl)* 2016;129:206-14
- [65]. Wilson ME, Johnson WJ, Trivedi RH. Primary multifocal intraocular lens implantation for teenage-onset bilateral cataracts: Visual results a decade after surgery in 3 siblings. *J AAPOS* 2013;17:623-5.
- [66]. Choi J, Kim JH, Kim SJ, Yu YS. Clinical characteristics, course, and visual prognosis of partial cataracts that seem to be visually insignificant in children. *J AAPOS*. 2012;16(2):161–167.
- [67]. Bouzas AG. Anterior polar congenital cataract and corneal astigmatism. *J Pediatr Ophthalmol Strabismus*. 1992;29(4):210–212.
- [68]. Drummond GT, Hinz BJ. Management of monocular cataract with long-term dilation in children. *Can J Ophthalmol*. 1994;29(5):227–230.
- [69]. Elston JS, Timms C. Clinical evidence for the onset of the sensitive period in infancy. *Br J Ophthalmol*. 1992;76(6):327–328.
- [70]. Birch EE, Stager DR. The critical period for surgical treatment of dense congenital unilateral cataract. *Invest Ophthalmol Vis Sci*. 1996;37(8): 1532–1538.
- [71]. Birch EE, Cheng C, Stager DR Jr, Weakley DR Jr, Stager DR Sr. The critical period for surgical treatment of dense congenital bilateral cataracts. *J AAPOS*. 2009;13(1):67–71.
- [72]. Lambert SR, Drack AV. Infantile cataracts. *Surv Ophthalmol*. 1996; 40(6):427–458.

- [73]. Costenbader FD, Albert DG. Conservatism in the management of congenital cataract. Arch Ophthalmol 1957; 58: 426-30.
- [74]. Scheie HG: Aspiration of congenital or soft cataracts. A new technique. Am J Ophthalmol 1960; 50: 1048-56
- [75]. Wilson ME. Intraocular lens implantation: has it become the standard of care for children? Ophthalmology 1996; 103: 1719-20.
- [76]. Kain HL, Osusky R. [Pars plana lensectomy in pediatric cataract] Klin Monatsbl Augenheilkd. 1992; 200: 451-3.

Dr. Jitendra kumar "Pediatric cataract-Etiology and clinical diagnosis." IOSR Journal of Dental and Medical Sciences (IOSR-JDMS), vol. 17, no. 2, 2018, pp. 12-19.