

## Schwannoma of the median nerve in the wrist and palm of hand treated by excision: a rare case report

Prabhu Shrinivas Prashanth<sup>1</sup>, Prof. Salam Nongthon Singh<sup>2</sup>, Nobin Kumar Sharma<sup>1</sup>, Sudip Deb<sup>1</sup>, Dilip Soring<sup>1</sup>, B. Punithvasanthan<sup>1</sup>, Prabhat Rai<sup>1</sup>

<sup>1</sup> post graduate trainee, department of orthopedics, regional institute of medical sciences, imphal

<sup>2</sup> professor & head, department of orthopedics, regional institute of medical sciences, imphal

Corresponding author: Prabhu Shrinivas Prashanth

Date of Submission: 25-01-2018

Date of acceptance: 09-02-2018

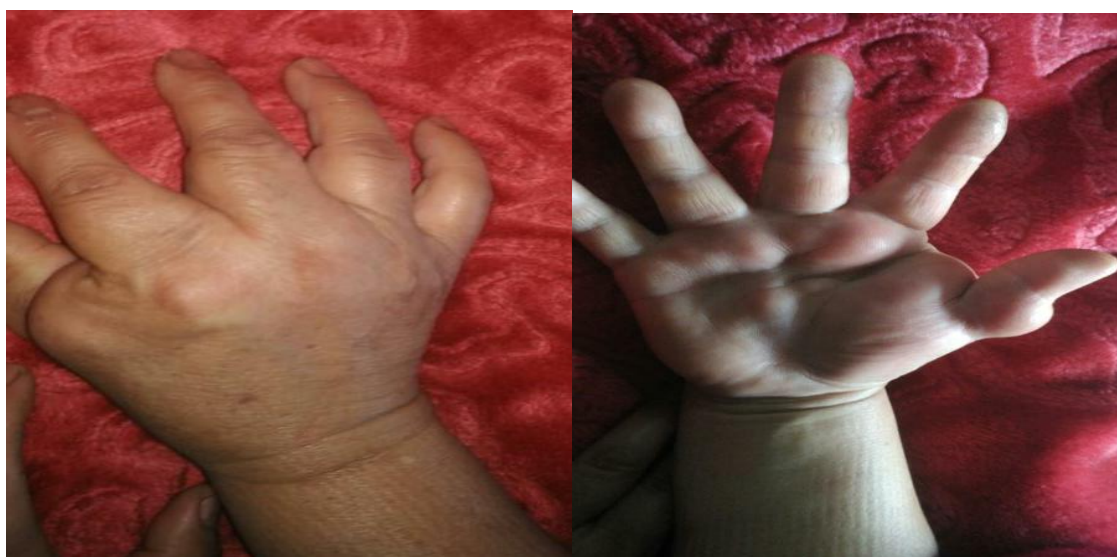### I. Introduction

Schwannomas are also known as neurilemmomas. The cells of origin are the Schwann cells of the peripheral nerve sheath. They are the most common benign tumors of the neural sheath of the peripheral nerves. Schwannomas accounts for 0.1-0.3% of hand tumors. Ulnar nerve is the most common nerve affected. Median nerve is affected only in 7% of the cases. It can give rise to diagnostic dilemma and can be misdiagnosed as ganglion or carpal tunnel syndrome.

### II. Case report

**History:** A 37 years old female presented with a swelling over her wrist and palm for the past 10 years. Patient had been experiencing gradually progressive pain over the swelling for 6 months associated with numbness over the thumb and index finger for the same duration. Patient was previously diagnosed and treated as ganglion at different centers. There was no history of trauma and no similar complains amongst other family members.

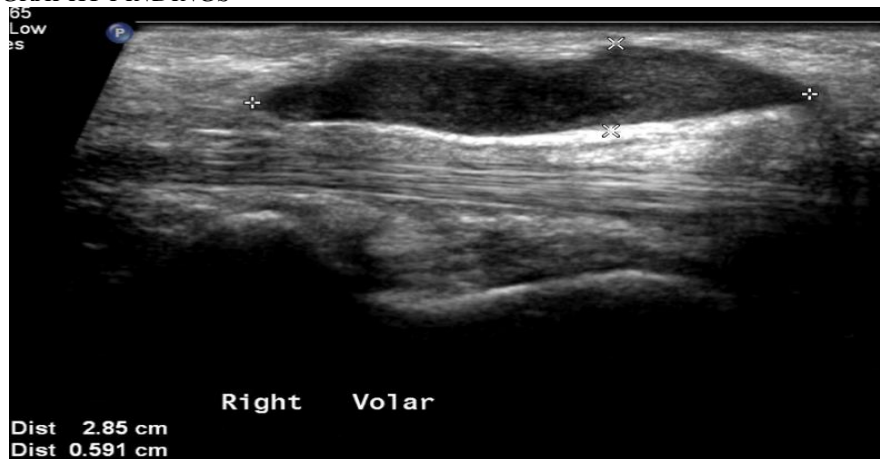On examination, a solid mass measuring 2 x 1 cm over flexor aspect of distal forearm, 2 x 2 cm over thenar eminence of hand, 1 x 2 cm over thumb was seen. Mobility was restricted longitudinally but present transversely. Tinel's sign was positive. There was no associated motor weakness, no muscular atrophy, no cutaneous pigmented lesions.



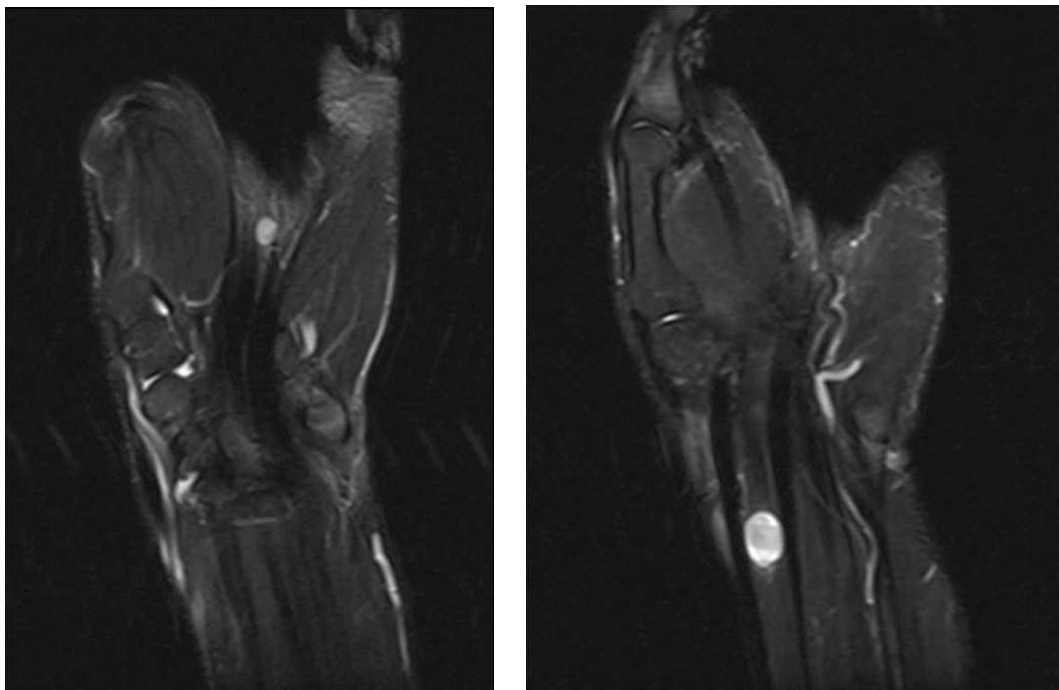
*Clinical picture of the swelling over the dorsum and palmar aspect of hand*

**Investigation:** Plain X-rays of forearm, wrist and hand was done to exclude any associated bony pathology. USG revealed well circumscribed cystic masses without blood supply, present in close relation to flexor tendons. In T1 weighted MRI masses were of intermediate intensity and in T2 weighted MRI masses appeared hyper-intense.

**ULTRASONOGRAPHY FINDINGS**

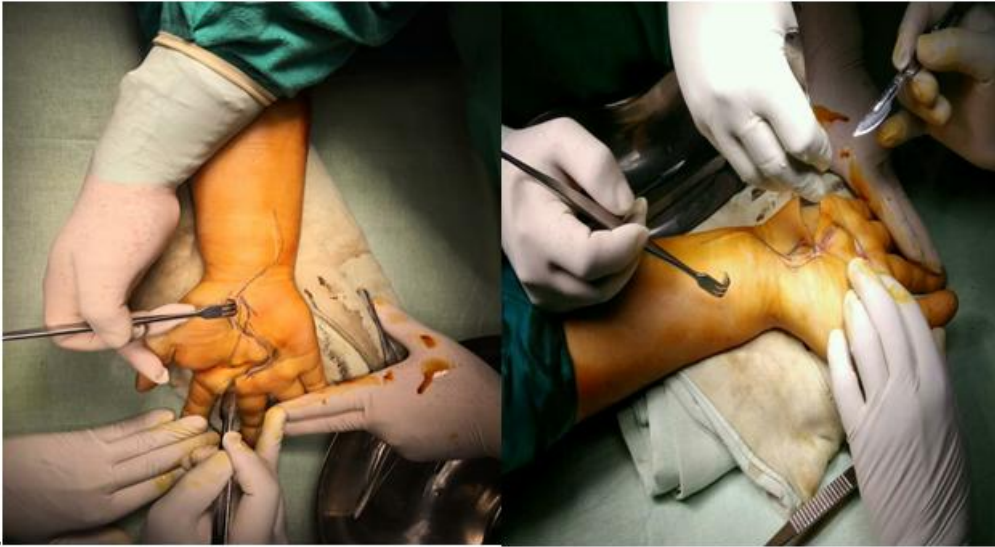

**MRI FINDINGS**

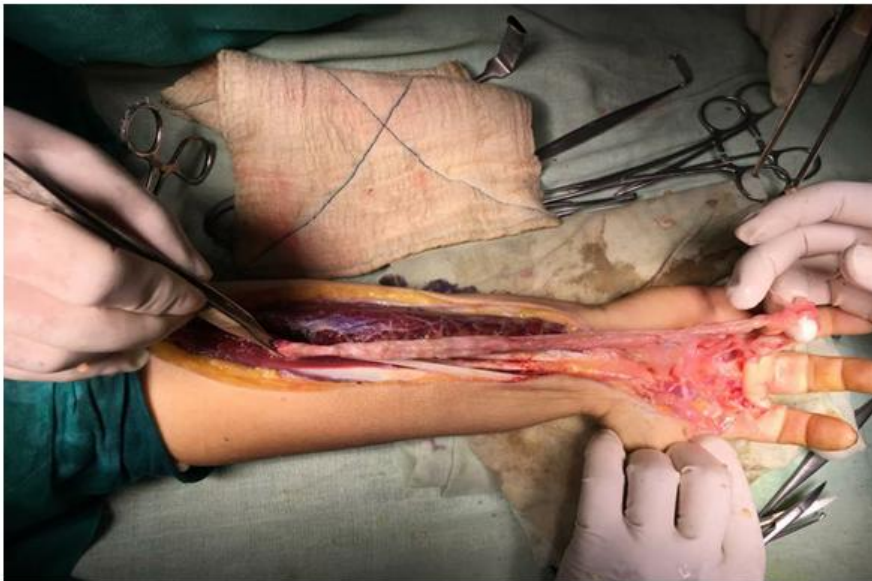

**Provisional diagnosis:** Based on long history, clinical features, ultrasonography and MRI findings nerve sheath tumour of median nerve was diagnosed and was thus planned for excisional biopsy.

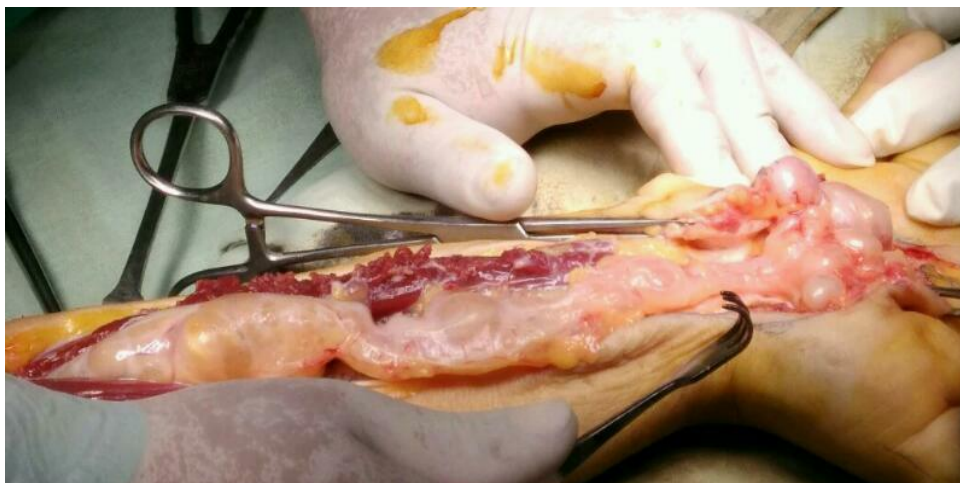**SURGERY:** A longitudinal incision centered over the tumor bulk in the distal flexor aspect of forearm extending over the wrist and palm was made. A separate incision was made over the tumor on the lateral aspect of thumb. Tumor was encapsulated and eccentric in position. It was firmly attached to median nerve in the distal forearm and wrist and to the digital nerve of the thumb. Epineurium was then longitudinally incised and soft tissue mass dissected from surrounding nerve fascicles. Mass was then completely excised with the aim of preserving the median nerve intact. Post operative survey was done to look for any sensory or motor deficit. Painless active movements in all fingers and thumb were present. Histopathology of the mass revealed alternate cellular area (Antoni A) and hypocellular areas in myxoid background (Antoni B). In immunohistochemistry the mass was positive for S-100.



Primary incision along the pre marked site of most prominent part of the swelling.



**TUMOR MASS EXPOSED ALONG THE MEDIAN NERVE TUMOR MASS EXPOSED ALONG THE MEDIAN NERVE**



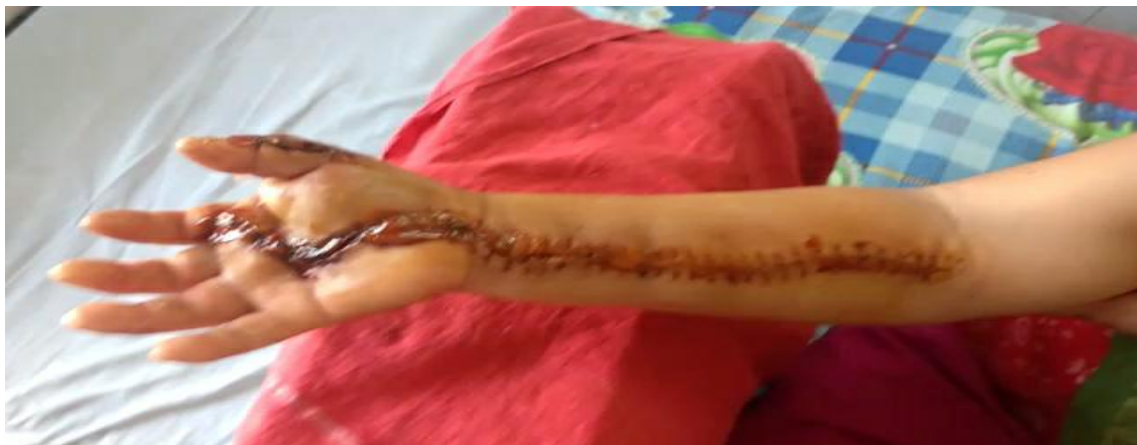**TUMOR MASS AFTER EXCISION**



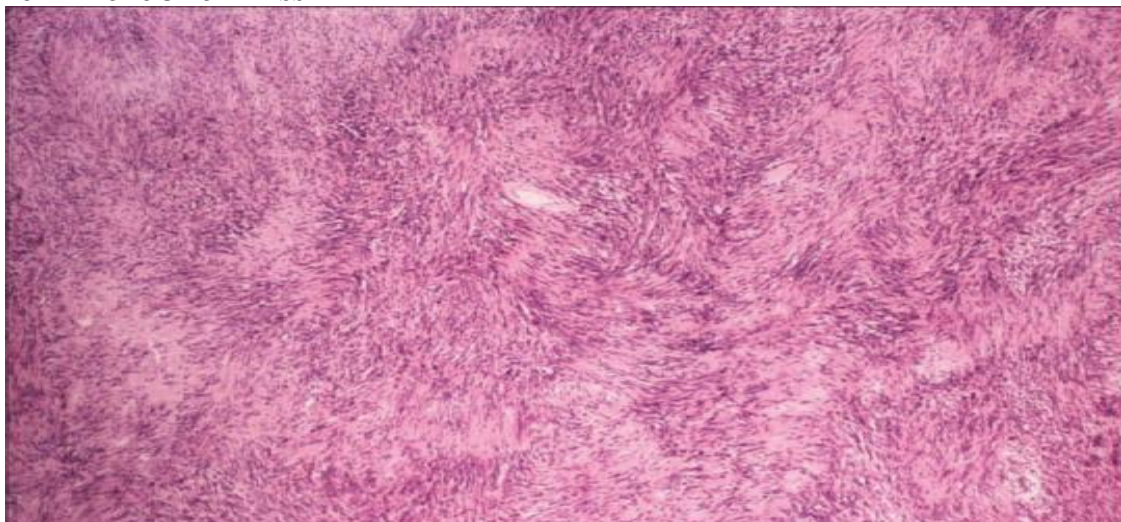
**POST- OPERATIVE CHECK-UP**

- *No sensory loss .No weakness in muscles .Painless active movements in all fingers and thumb present*

**POST-OPERATIVE FINGER MOVEMENTS**



**HISTOPATHOLOGY OF MASS**



- *Alternate Antoni A and Antoni B areas*
- *Antoni A: cellular area (spindle cells & Verocay bodies due to nuclear palisading)*
- *Antoni B: hypocellular , myxoid background*
- *IHC: S-100 positive*

### **III. Discussion**

Schwannomas are rare tumors usually solitary and benign. Multiple schwannomas suggest an underlying tumor predisposition syndrome associated with neurofibromatosis type 1 and schwannomatosis. The incidence of multiple schwannomas has been reported as 1% to 23%. The mostly affected nerves are ulnar and median nerves. There are several cases of multiple schwannomas of median nerve reported in the literature. Wrist and palm involvement similar to our case is reported only in two of these studies. These tumors are slow growing, soft in consistency, mobile in nature, and sometimes painless. They may be misdiagnosed as lipoma, fibroma, ganglion, or xanthoma. MRI can provide useful information about morphological data on the median nerve tumors. The TARGET SIGN with contrasting central and peripheral intensities can be demonstrated. Specificity is 100% but sensitivity is 59%. Conversely, USG gives detailed informative images showing the nerve in relation to the surrounding musculotendinous and vascular structures. Surgical excision is the most effective method of therapy however most authors recommend excision of only symptomatic tumors or those demonstrating enlargement during follow up. Sterile tourniquet dissection for a bloodless field and identification of the nerve proximal and distal to the mass is the most important step in reducing injury to the nerve and traction neuropraxia. Slow circumferential dissection of tumor in the plane between outer nerve sheath and tumor capsule facilitates delivery of the tumor. Post resection the nerve is inspected for injury and tourniquet released to achieve homeostasis. Paresthesia is the most common postoperative complication.

### **IV. Conclusion**

Schwannomas are rare peripheral nerve tumors that have important diagnostic and radiographic features. Surgical resection must be approached with caution to protect nerve function and continuity. Outcome after surgery is good and recurrence rate is low.

### **References**

- [1]. Ozdemir et al, "Schwannomas of the hand and wrist: long term results and review of literature", journal of Orthopedic surgery, vol.13., pp.267-272,2005.
- [2]. Harun Kutaya et al, " Schwannomas of median nerve at hand and wrist: a rare case report"; Case reports in orthopedics, Article ID 950106,volume 2013.
- [3]. Padasali et al, "Median nerve Schwannoma: A case and review of literature", Asian journal of Neurosurgery, 10(3): 212-214 ,2014.

Prabhu Shrinivas Prashanth "Schwannoma of the median nerve in the wrist and palm of hand treated by excision: a rare case report". IOSR Journal of Dental and Medical Sciences (IOSR-JDMS), vol. 17, no. 2, 2018, pp. 32-36.