

Postpartum Transient Osteoporosis of Hip (TOH) of a 31 year old woman: a case Report

A.J.S.P. Nileema*, L. Thasanthan

Department of Radiography/Radiotherapy, Faculty of Allied health Sciences, University of Peradeniya, Sri Lanka.

spnjayasooriya@gmail.com (A.J.S.P. Nileema*)

thasanth@pdn.ac.lk (Thasanthan Loganathan)

Corresponding contributor: A.J.S.P. Nileema

Abstract: Hip pain, pelvic pain and low back pain (LBP) are common conditions during pregnancy and postpartum. Certain numbers of cases of transient osteoporosis of hip (TOH) have been reported in the literature, but its real prevalence seems to be underestimated. We report a case of 31-year-old patient who presented during postpartum period (two weeks after delivery) with severe right hip joint pain and radicular symptoms which mimics lumbar radiculopathy. On request of an Magnetic Resonance Imaging (MRI) scan of lumbar-sacral spine, short tau/TI inversion recovery (STIR) coronal sequence was also performed which ultimately led to the identification of features of TOH. The use of coronal STIR sequence in addition to the routine sequences of lumbar-sacral imaging was paramount of importance in diagnosing the condition. Patient was treated conservatively, with partial resolution of symptoms.

Keywords: Low Back Pain, Lumbar Sacral Imaging, MRI, STIR Imaging, Transient Osteoporosis of Hip

Date of Submission: 25-01-2018

Date of acceptance: 13-02-2018

I. Introduction

Women develop LBP in association with hip joint and/or buttock pain commonly during pregnancy and postpartum period^[1-5]. Pain may present with or without radiating pain to the lower extremity^[6]. TOH is considered to be one of causes of hip pain related with pregnancy and postpartum period^[2-7]. TOH have been described as a rare disease of uncertain etiology which is characterized by severe unilateral or bilateral hip pain^[3,5]. Typically during third trimester of pregnancy, osteoporosis manifests itself with a sudden onset of hip pain and limp without any trauma or infective episode in clinical history^[8]. Nevertheless, when radicular symptoms do accompany the pain, it might distract the clinician from accurate diagnosis of TOH since it mimics lumbar radiculopathy^[6,7].

A few cases of pregnancy-related TOH have been reported worldwide. Among these only few cases were evaluated using MRI, computed tomographic (CT) and laboratory investigations whereas most were evaluated only by MRI features. The majority of cases have utilized the aid of STIR coronal sequence features to diagnose the pathology. Not only TOH, postpartum sacral stress fractures, sacral fractures in athletes are also diagnosed by using advantage of STIR coronal sequence. We herein report a case of postpartum TOH of a woman evaluated by MRI findings whose clinical symptoms were in favor of lumbar radiculopathy. The significance of coronal STIR sequence in imaging for LBP is emphasized.

II. Case Report

A 31-year-old woman presented to her clinician with sudden-onset of severe pain in right hip joint associated with knee and ankle joint pain during postpartum period of her third pregnancy. Patient was unable to sustain any weight bearing with right limb and it disturbed walking. She did not show any symptoms of LBP or pain in any hip joint during pregnancy/before delivery. She was 164.5 cm in height and weighed 67 Kg for a body mass index (BMI) of 24.6. She had a spontaneous vaginal delivery of a 3.9 Kg baby at 37 weeks of pregnancy. There was no history of trauma during pregnancy or peripartum period. There was no family history of osteoporosis. Patient had no significant past medical history. After the delivery the patient was unable to walk and spent most of the day lying on the bed. With time, her pain progressively worsened such that analgesics did not alleviate the symptoms.

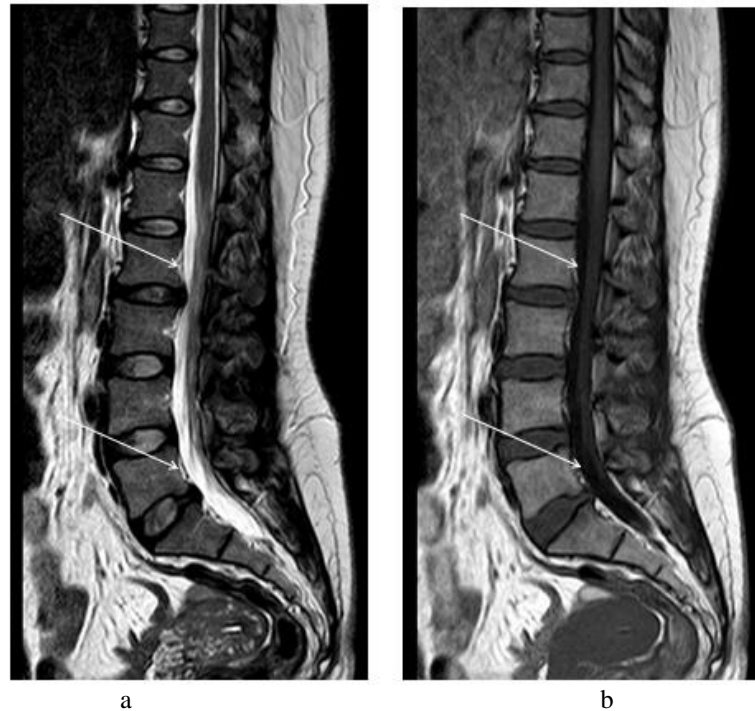


Figure 1. T2 weighted (a) and T1 weighted sagittal images of lumbar sacral spine showing dehydration and disc bulging in L2-L3 and L5-S1 levels (arrows) respectively.

Physical examination revealed a highly localized pain over the right hip joint with palpation. Gait was abnormal; antalgic gait pattern secondary to pain and evident limping. Pain progressively worsened with time giving her an unrelenting pain. 2 months after the delivery a neurologic opinion was sought. Since the initial diagnostic impression of the clinician was that of a lumbar radiculopathy, an MRI scan of lumbar sacral spine was requested. No plain radiographs were taken.

MRI scan of lumbar-sacral spine revealed L2-L3 level disk dehydration with posterior central disk bulge mildly indenting the cauda equina and L5-S1 level disk dehydration with mild posterior central disk bulge indenting the thecal sac. Coronal STIR images showed diffuse STIR high signal intensity in right femoral head, neck and intertrochanteric region indicative of bone marrow edema with an associated small right hip joint effusion. Also, a minor narrowing of right hip joint space and minimal surrounding soft tissue oedema was present. No fractures were identified and contour of the femoral head was maintained. Findings were mostly in favor of postpartum TOH in pregnancy. However, differential diagnosis included avascular necrosis.

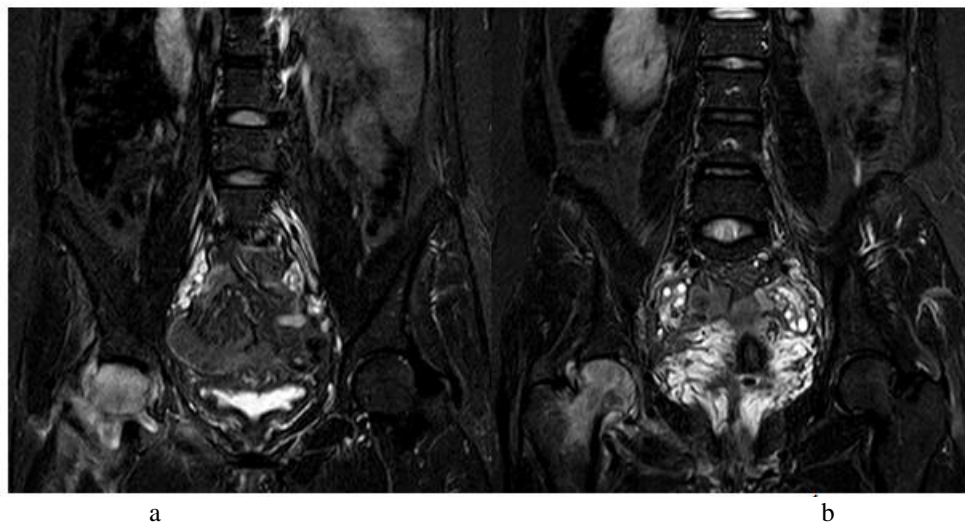


Figure 2. Coronal STIR images of lumbar sacral region (a and b) showing diffuse STIR hyperintensity over right femoral head and neck region with small hip joint effusion and minor right hip joint space narrowing.

Treatment plan consisted of adequate pain control, recommendation of bed rest for two weeks and instructions to limit strenuous and high weight bearing activities. The patient's pain level decreased slowly over several months; however it did not resolve completely.

III. Discussion

Hip joint and pelvic pain is quite common among women in the prenatal and postpartum setting. Physical examination, past medical and family history and reproductive history of the patient provide the clinician with supportive information to narrow the differential diagnoses, which eventually dictate the choice of imaging modality prescribed to diagnose and/or confirm the diagnosis.

TOH is a rare skeletal disease of unknown etiology which is often occurred in previously healthy women during the third trimester of the pregnancy with an approximate probability of 0.4 cases for 100,000 women^[6]. Typically patients present with progressively worsening unilateral or bilateral hip joint pain without prior history of trauma. Limiting the movement of hip, the pain is aggravated by activities^[9,10]. Since the clinician may be distracted from the accurate diagnosis when the condition mimics lumbar radiculopathy, a high index of suspicion with careful physical examination and past medical history is paramount importance to establish an early diagnosis and appropriate treatment of the condition.

Although plain radiographs, radionuclide imaging and MRI can be used to diagnose TOH, MRI is the gold standard to diagnose TOH owing to its high sensitivity rendering early diagnosis and absence of hazardous ionizing radiation. TOH features of MRI include bone marrow oedema involving the femoral head and neck with possible extension into the sub trochanteric region, commonly associated with hip joint effusion. These are identified as increased signal intensity on STIR images and decreased intensity on T1 weighted images. As the initial diagnostic impression in our patient was lumbar radiculopathy, she was prescribed to undergo an MRI scan of lumbar sacral spine. However, clinical expertise and updated knowledge on MRI pulse sequences guided us to expedient use of coronal STIR sequence of lumbar sacral region, which is not routinely performed for this study. MRI findings in our patient's coronal STIR images were consistent with TOH in pregnancy. Differential diagnosis included avascular necrosis.

IV. Conclusion

In conclusion, use of coronal STIR sequence has led the examination towards a proper diagnosis of the clinical scenario. Hence the diagnostic yield of MRI scan of lumbar-sacral spine in patients with LBP can be optimized by performing STIR coronal sequence. Further, TOH should be included in the differential diagnosis of a patient with sudden hip joint pain during third trimester of the pregnancy or immediate postpartum period.

References

- [1]. R. Gupta, P. Mittal, Amit Mittal, Kapish Mittal, Sharad Gupta, and Ravleen Kaul. Additional merit of coronal STIR imaging for MR imaging of lumbar spine. *J craniovertebral Junction & Spine*, 6(1), 2015,12–15.
- [2]. V. Patel, S. Temkin, and M. O'Loughlin. Transient osteoporosis of pregnancy in a 34-year-old female. *J Radiology Case Reports*, 7(2), 2012, 646-649.
- [3]. M.E. Reese, C. Fitzgerald, C. Hynes, Transient osteoporosis of pregnancy of the bilateral hips in twin gestation: a case series. *J Physical medicine and Rehabilitation*, 7(1), 2015, 88-93.
- [4]. M.E. Klontzas, , E.E. Vassalou, A.H. Zibis, A.S. Bintoudi, A.H. Karantanas, MR imaging of Transient Osteoporosis of the hip: an update on 155 hip joints, *Eur J Radiol*, 84(3), 2015, 431-436.
- [5]. T. Anai, K. Urata, A. Mori, F. Miyazaki, S. Okamoto, Transient osteoporosis of the hip in pregnancy associated with generalized low bone mineral density--a case report, *Eur J Radiol*, 76(2), 2013, 133-138.
- [6]. J. Park, E. Ok, H. J. Park, S. H. Hong, and J. I. Lee. Postpartum Sacral Stress Fracture Mimicking Lumbar Radiculopathy in a Patient With Pregnancy-Associated Osteoporosis, *Ann Rehabil Med*, 37(4), 2013, 582-585.
- [7]. A. D. Perdomo, F. T. Bermejo, A. R. Piñera, L. Alvarez. Misdiagnosis of Sacral Stress Fracture: An Underestimated Cause of Low Back Pain in Pregnancy?, *Am J Case Rep*, 16, 2015, 60-64.
- [8]. S. A. Patella V, D. Speciale, M. Petrer, D. Vittore, V. Pesce, S. Patella, Hip fracture in a patient affected by transient osteoporosis of the femoral head during the last trimester of pregnancy. *US*, 32(5), 2009, 365 – 369.
- [9]. A. Samdani, E. Lachmann, W. Nagler, Transient osteoporosis of the hip during pregnancy: a case report. *Am J Phys Med Rehabil*. 77(2), 1998, 153-156.
- [10]. A.T. Sweeney, M. Blake, M.F. Holick, Transient osteoporosis of hip in pregnancy. *J Clin Densitom*, 3(3), 2000, 291-297.

A.J.S.P. Nileema "Postpartum Transient Osteoporosis of Hip (TOH) of a 31 year old woman: a case Report." IOSR Journal of Dental and Medical Sciences (IOSR-JDMS), vol. 17, no. 2, 2018, pp. 82-84.