

Series Of Fetal Structural Abnormalities Detected By Ultrasonogram During Second Trimester Anomaly Scan

¹. Dr. Sundara Raja Perumal R, ². Dr. Sharanya Ponni S

Department Of Radiodiagnosis, Sree Balaji Medical College and Hospital, Chennai

Corresponding author: Dr. Sundara Raja Perumal R

Abstract: Second trimester ultrasound scan is an important antenatal scan, which studies detailed anatomy of the fetus and identify the fetal structural anomalies and also in the management of fetal anomalies. Second trimester anomaly scan done during 18 to 22 weeks of gestation in our institution. A total of 163 second trimester ultrasound anomaly scan were done in the department of Radiodiagnosis, Sree Balaji Medical College and Hospital and Chennai, during the period from June 2017 to September 2017. Out of total 163 second trimester antenatal scans, abnormal USG findings detected in 26 patients. All patients with abnormal USG patients were followed up and findings were corroborated after delivery of baby or after MTP. Out of 26 pregnant women with abnormal USG findings, ten pregnant women had multiple abnormalities and 16 women had isolated abnormalities. Among isolated abnormal findings, renal system was more commonly involved. Few of pregnant women with important USG findings have been described in this article.

Keyword: Second trimester anomaly scan, Target scan, Holoprosencephaly, Cleft lip, palate, CPAM, Arnold Chiari malformation, Club foot, Posterior urethral valve

Date of Submission: 01-02-2018

Date of acceptance: 19-02-2018

I. Introduction

Second trimester ultrasound scan is an important and necessary antenatal scan done during 18 to 22 weeks of gestation and studies the detailed anatomy of the fetus and find out all structural abnormalities of the fetus. Second trimester scan also helps in decision making of whether to continue or not to continue the pregnancy in case of fetus with structural abnormalities and also helpful in deciding about further follow up and treatment. This scan also called as TIFFA scan (Targeted imaging for fetal anomalies) or fetal anomaly scan. Being higher referral centre, We get a number of pregnant patients to our institution, and diagnosed many academically interesting fetal anomalies. In this article, we have summarized few interesting anomalies we had come across in the Department of Radiology, Sree Balaji Medical College and hospital, Chennai.

II. Materials and Methods

This is publication of series of few interesting anomalies which were diagnosed in the department of Radiodiagnosis, Sree Balaji Medical College and Hospital and Chennai. All pregnant patients who had come for target scan in second trimester from June 2017 to September 2017 in the department of Radio diagnosis in Sree Balaji medical college & hospital, Chennai. Out of total 163 second trimester antenatal scans, abnormal USG findings detected in 26 patients. Written Consent of all pregnant women was taken and detailed filling of FORM F done under PNDT act. Incidence of structural abnormalities is higher in our institution, being a tertiary referral centre.

All pregnant women had underwent transabdominal ultrasound and if necessary, transvaginal ultrasound, which were performed by using an DC -7 unit (Mind ray) Ultrasound machine. All patients with abnormal USG patients were followed up and findings were corroborated after delivery of baby or after MTP. Previous antenatal scan were also reviewed for all pregnant women.

Out of 26 pregnant women with abnormal USG findings, ten pregnant women had multiple abnormalities and 16 women had isolated abnormalities. Among isolated abnormal findings, renal system was more commonly involved. Few of pregnant women with important USG findings have been described below.

III. Discussion And Results

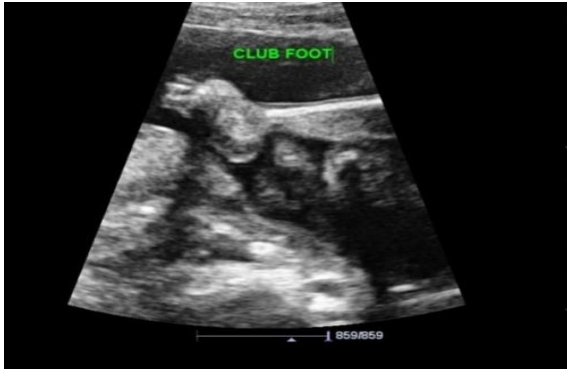CASE NO: 1

A 22 Years old female with history of 19 weeks amenorrhea with history of 2nd degree consanguineous marriage, had come for target scan. No significant previous obstetric history. Dating scan not done. Fetus showed, evidence of multiple anomalies:

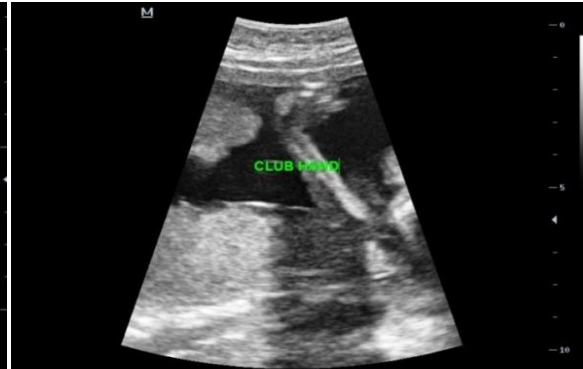Series Of Fetal Structural Abnormalities Detected By Ultrasonogram During Second Trimester ..

Microcephaly, Holoprosencephaly with absence of falx cerebri, Short neck, Narrow thorax, Protuberant abdomen, Kyphoscoliosis of the spine, Sacral agenesis, Single umbilical artery, Bilateral club foot, Bilateral club hand. Stomach bubble, Urinary bladder visualized.

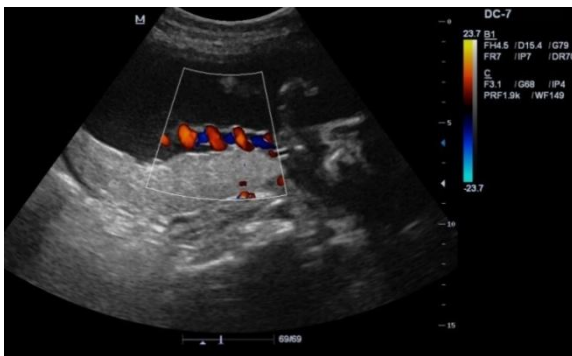BILATERAL CLUB FOOT AND CLUB HAND



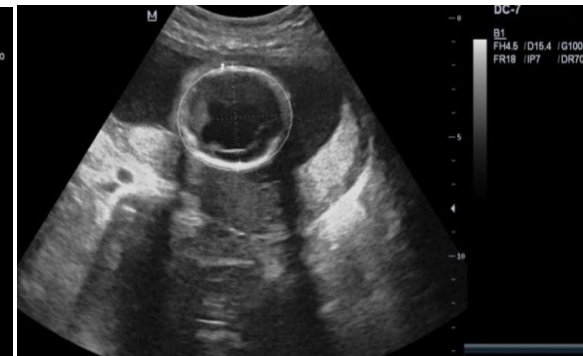CLUB FOOT



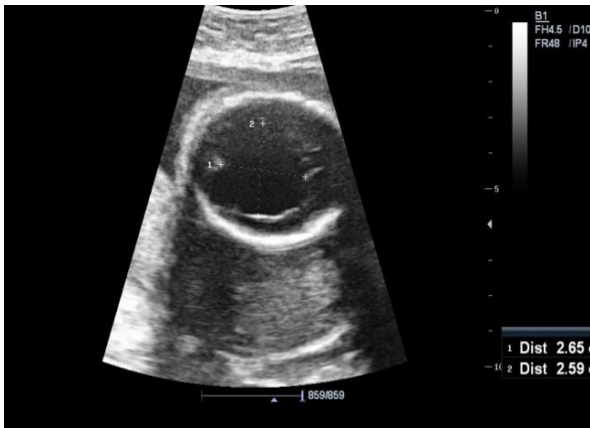
CLUB HAND



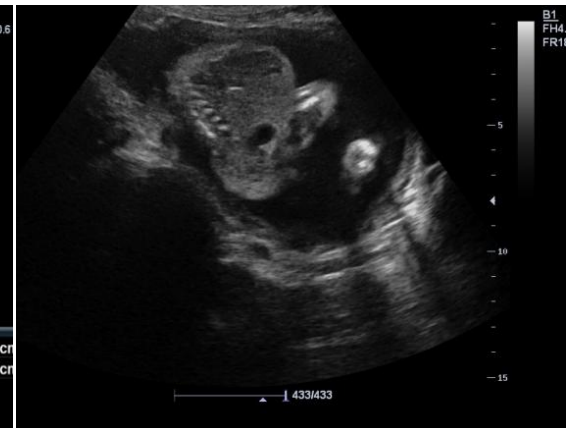SINGLE UMBILICAL ARTERY



HOLOPROSENCEPHALY

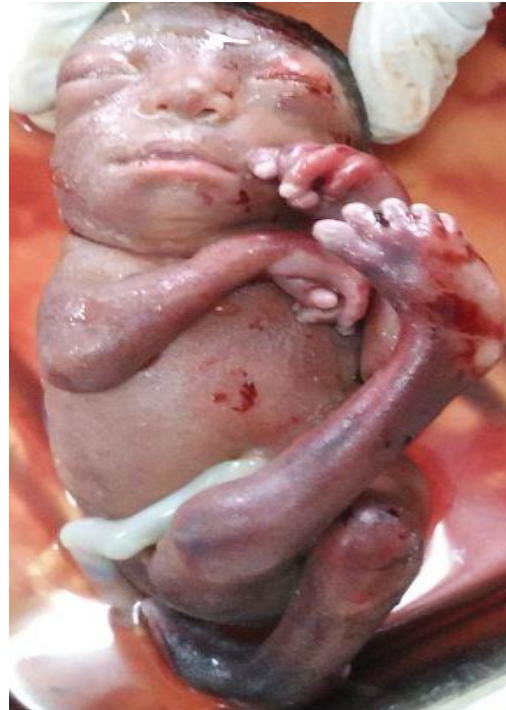
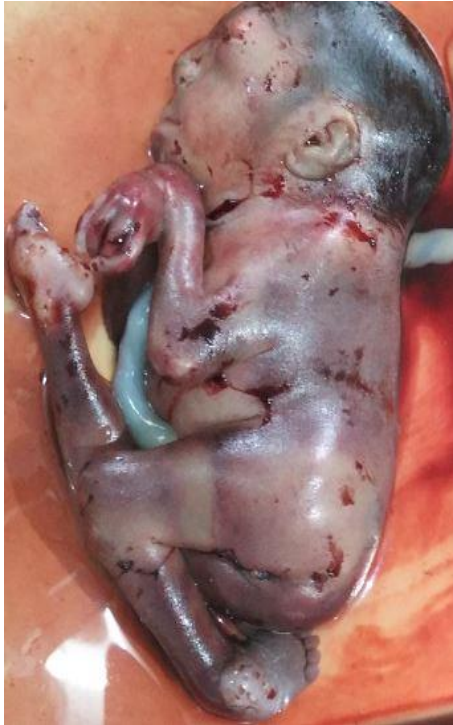
DORSAL BRAIN CYST

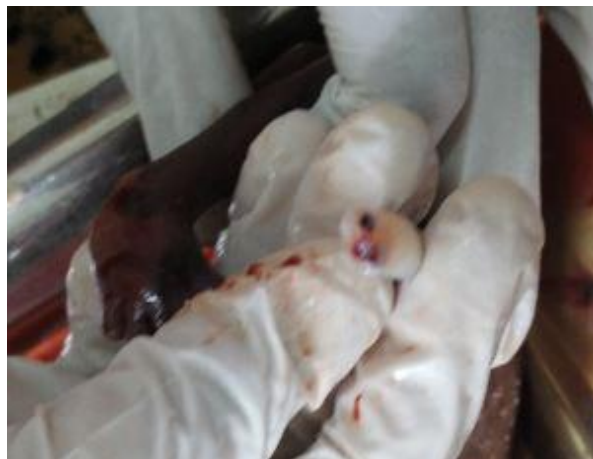

AGENESIS OF SACRUM

Baby was terminated and few of above findings were confirmed. No autopsy was done since parents refused for autopsy.



Baby showed club foot, club hand, low set ears, Deformed spine



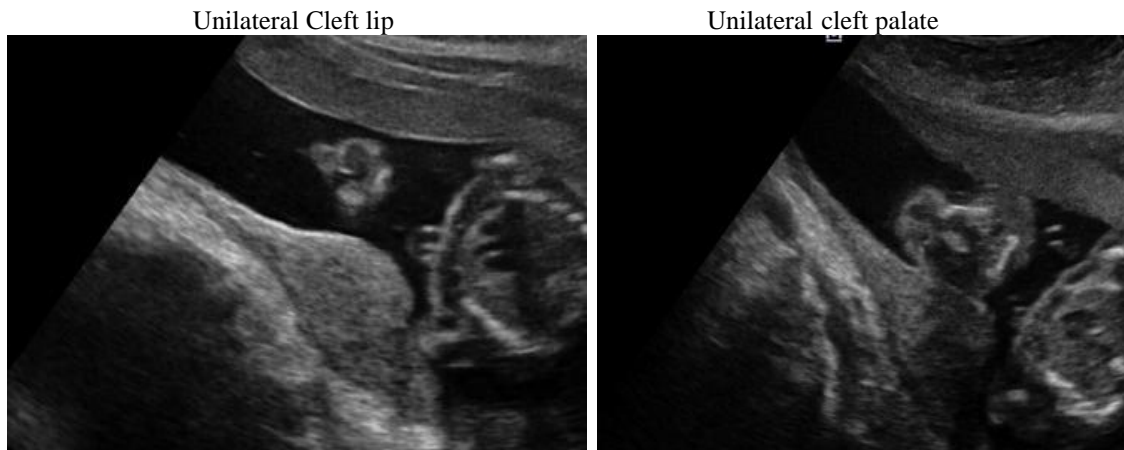
Single umbilical artery

Holoprosencephaly is the most common anomaly involving of the brain and face in humans (3). Other nonfacial abnormalities include genital defect (Most common non facial association), Post axial polydactyly, vertebral defect, limb reduction defects, transposition of great arteries. Few other anomalies also associated with holoprosencephaly like, taanatophoric dysplasia (1), and ectrodactyly (Hartsfield syndrome) (2,5). Prevalence is less than 1 in 10000 in live and stillbirth, incidence is higher when termination of pregnancy also included and as many as 50 per 10000 in aborted embryos (7). There is no strong ethnic predilection. Prognosis is poor in case of severe form of holoprosencephaly.

A dorsal cyst is almost always present in alobar holoprosencephaly, and much less frequently in semi lobar and lobar types (92%, 28%, and 9%, respectively) (4). Dorsal cyst is always associated with thalamic fusion, with possibly obstruction of flow of CSF out of third ventricle causing balloon dilatation of third ventricle. Dilated third ventricle balloon out posteriorly at the point of least resistance at suprapineal recess and present as dorsal cyst. (4). An interhemispheric cyst associated with agenesis of the corpus callosum will be differential diagnosis of dorsal brain cyst, but the distinction may be made by the presence of normal cleavage of the cerebral hemispheres in the case of callosal agenesis (4). Rarely, the dorsal cyst may present as vertex encephalocele as its herniated through the anterior fontanelle. (6).

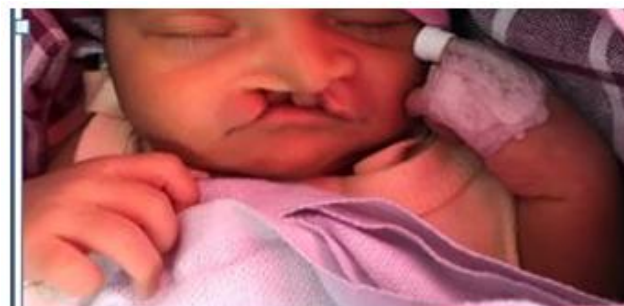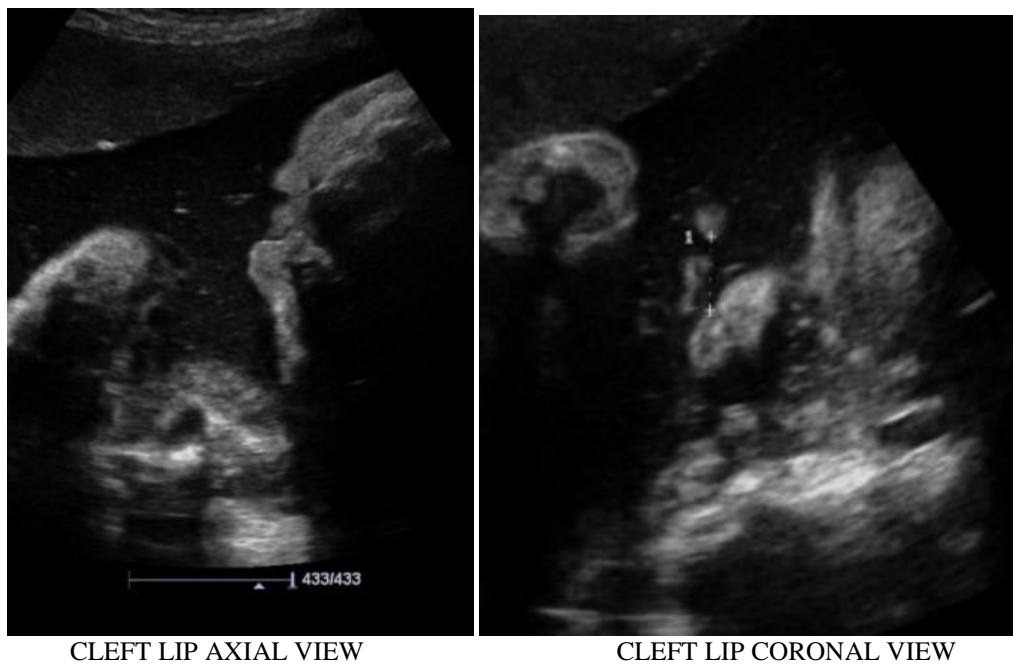
CASE 2:

A 30 year old female with history of 20 weeks 4 days gestation came for target scan with past history of congenital dysplasia of hip of first child and got treated for that. No history of consanguineous marriage. This fetus showed; right cleft lip and cleft palate.



CASE NO 3: (BILATERAL CLEFT LIP AND PALATE):

A 23 year term pregnant woman who got admitted for delivery, came for ultrasound, Dating scan and anomaly scan were not done. This present scan shows bilateral cleft lip and cleft palate. No other associated abnormalities identified. After delivery, clinical examination confirmed above findings and referred for higher centre for further management.



Cleft lip is due to failure of fusion of the medial fronto- nasal process with the maxillary process of the first pharyngeal arch. Fusion takes place at 4–6 weeks of gestation (9). Complete failure of fusion results in a cleft of the lip and cleft palate. Bony defect usually occur in between the incisor and canine teeth level on affected side. This condition is separated into two clinical groups, like cleft lip with or without cleft palate , isolated cleft palate and having with different implications regarding underlying genetic syndromes, associated anomalies, and prognosis.

Cleft Lip with or without Cleft Palate is more common than isolated cleft palate, more commonly in Asians. Males are more affected. More common site is on left side (11). It is associated with Van der Woude syndrome, which is characterized by lower lip pits and cleft lip and cleft palate.(8). A complete cleft implies a clefting of the lip and alveolar process that extends through the nasal floor. An incomplete cleft involves part of the alveolus but does not extend through the nasal floor.

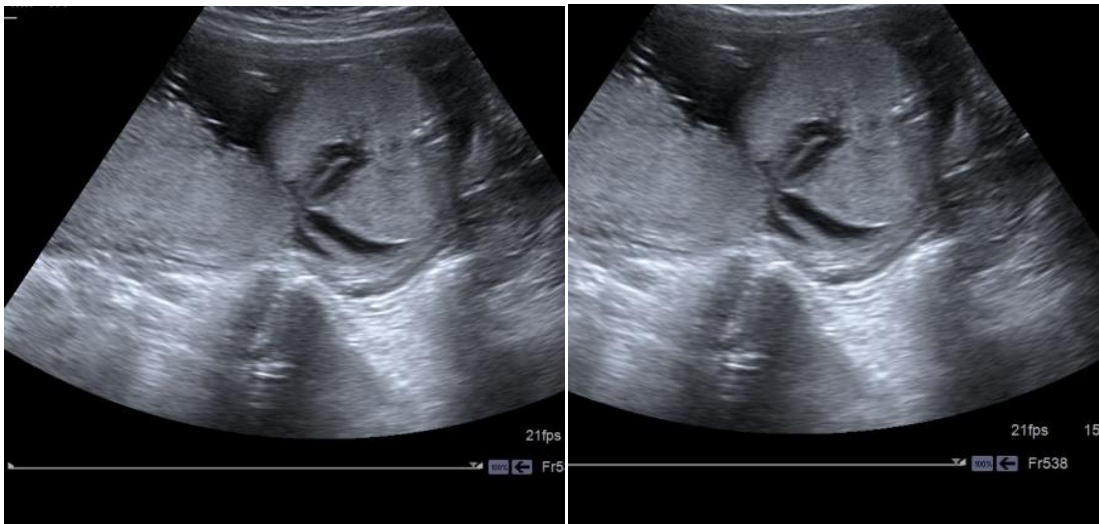
Isolated cleft palate is less common and more likely associated with syndrome. This condition is associated with Stickler syndrome (maxillary hypoplasia, ocular abnormalities and unilateral cleft palate) (10,12). Isolated cleft palate is more difficult to detect at fetal imaging.

CASE NO: 3

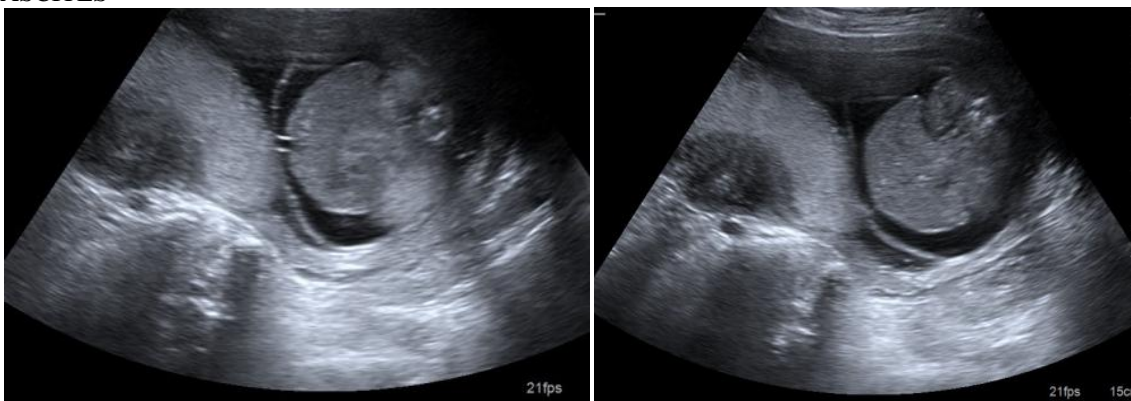
A 25 year old female with 19 weeks of gestation came for anomaly scan with no significant positive past history.

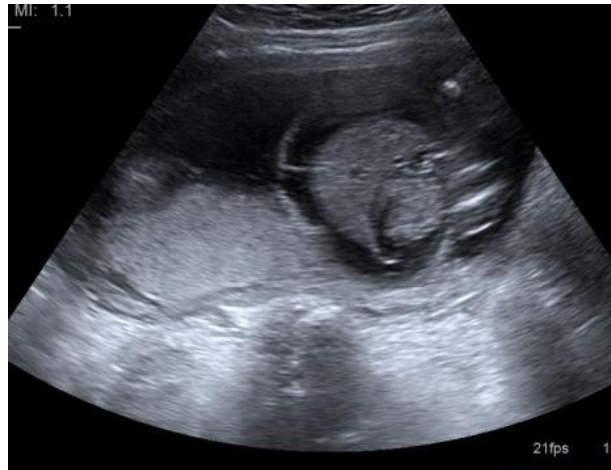Ultrasound of fetus shows enlarged hyperechoic bilateral lung parenchyma seen compressing the centrally placed heart and displacing the diaphragm inferiorly. Significant ascites noted in the abdominal cavity and features suggestive of Type III CPAM with Hydrops fetalis

BILATERAL ECHOGENIC LUNGS



ASCITES





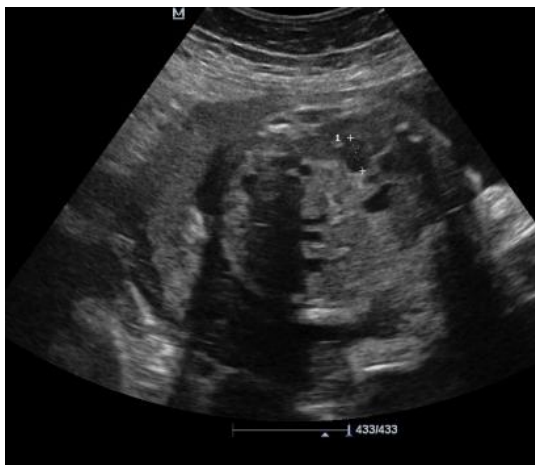Congenital pulmonary airway malformations (CPAM) are uncommon lesion which is characterized by multicystic areas of lung tissue with abnormal proliferation of bronchial structures. This lesion is due to overgrowth of terminal bronchioles in a glandular pattern and with absence of normal development of alveoli, between 7th to 10th week of embryonic life. Incidence is approximately 1:1500-4000 live births with a male predominance. This lesion is divided into three histological types, mainly depending upon the size of cysts. Type I is composed of variable-size cysts, with at least one dominant cyst is >2 cm in diameter. This is the most common (75%) form. Type II lesion have smaller cysts and constitute 15 to 20 % of CPAM. This type have association with, pulmonary sequestration, renal agenesis/ dysgenesis and cardiac anomalies. Type III lesion have micro cysts of less than 5 mm in diameter, usually involving entire lobe and have relatively poor prognosis, often causes death at birth. These lesions appear echogenic on USG imaging with mass effect (14) as described in our case. The prognosis of congenital cystic adenomatoid malformation is variable, depending on the size rather than histological type of the lesion. This condition may present as an incidental finding at routine prenatal ultrasonography to severe hydrops with mass effect and mediastinal shift depends upon the severity. Pulmonary atresia is associated with this lesion especially larger one. In childhood it may represents repeated chest infection. Hydrops fetalis and Polyhydramnios seen associated with this condition. (14).

The differential diagnosis includes congenital diaphragmatic hernia, pulmonary sequestration, and bronchogenic cysts (15, 16). This lesion is usually diagnosed with antenatal ultrasound or in the neonatal period on the investigation for complaint of progressive respiratory distress. The presentation in older patients is usually recurrent pulmonary infections.

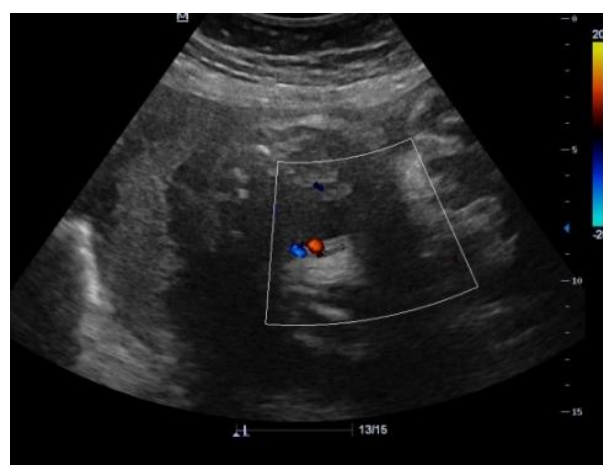
CASE NO 4:

A 34 year old female with history of unknown LMP came for routine scan, with no significant past history. Dating scan and anomaly scan were not done.

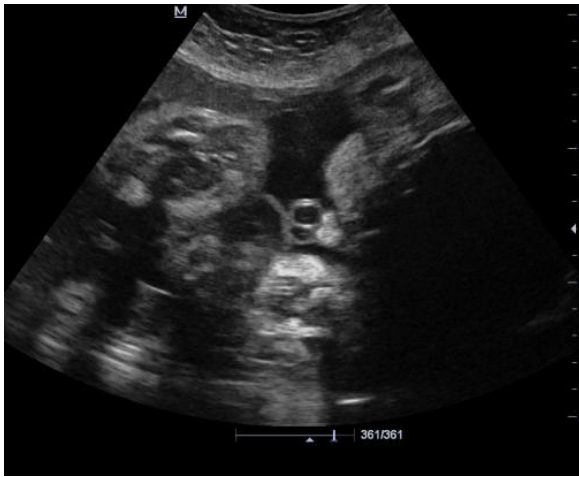Study showed, single umbilical artery, dilated left pelvic calyceal system, (left renal pelvis measures 1.3cm in antero-posterior dimension) and agenesis of right kidney as evidenced by non visualization of right kidney and right renal vessels on doppler study. Post natal ultrasound not done, since patient did not turn up for follow up.



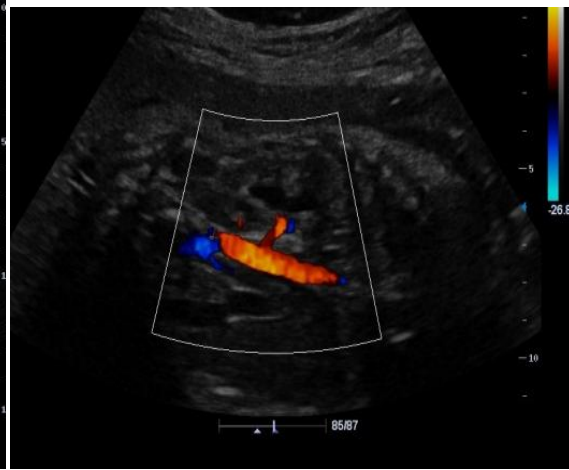
Dilated left renal pelvis



Single umbilical artery:



Single umbilical artery



Single renal artery:

This is a case of unilateral renal agenesis with hydronephrosis of contralateral kidney.

The incidence of unilateral renal agenesis is not known and it is likely 4 to 20 times more common than bilateral renal agenesis. The contralateral kidney will show compensatory hypertrophy. Ultrasound is important modality to identify fetal kidney and fetal adrenal gland. Fetal bowel may be interpreted as fetal kidney, hypoechoic renal medullary pyramids effectively identify the renal parenchyma and also differentiate other structures. Lying down adrenal sign will also helpful in identifying renal agenesis. As the renal arteries are not formed in renal agenesis, non visualization of renal vessels on colour doppler also a useful finding to identify renal agenesis.(17) Sepulveda et al found 8 patients referred with oligohydramnios to have no renal artery signal at sonography. In all patients, renal agenesis was seen in at least in one kidney. (18)

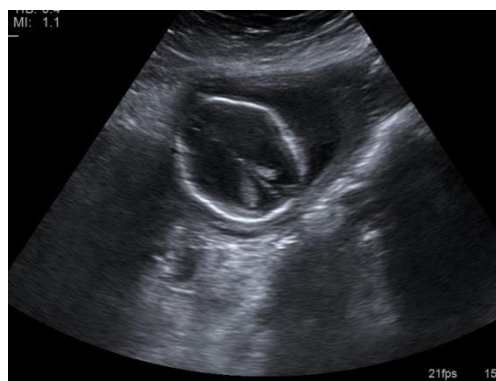Bilateral renal agenesis may be diagnosed by consistent absence of urinary bladder (Minimum of 30 min scanning) and Oligohydramnios. (19)

Fetal kidney develops from the metanephros. Failure of development of metanephros cause renal agenesis. Urine formation starts after 10th week of gestation and become a major source of amniotic fluid only after 14 to 16 weeks of gestation. Normal amniotic fluid before 16 weeks does not exclude renal agenesis. During antenatal scan , it will be difficult to differentiate between small atrophic kidney and renal agenesis.

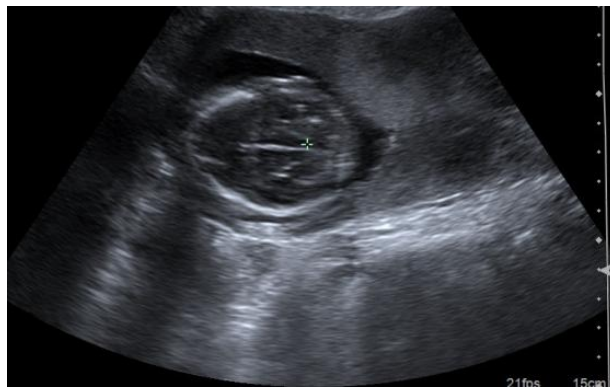
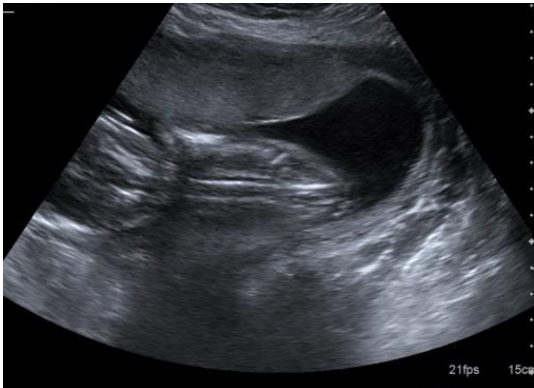
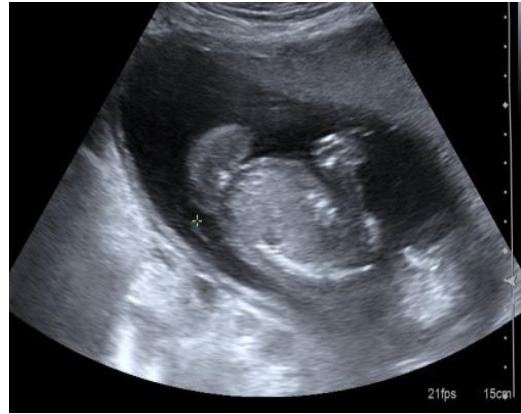
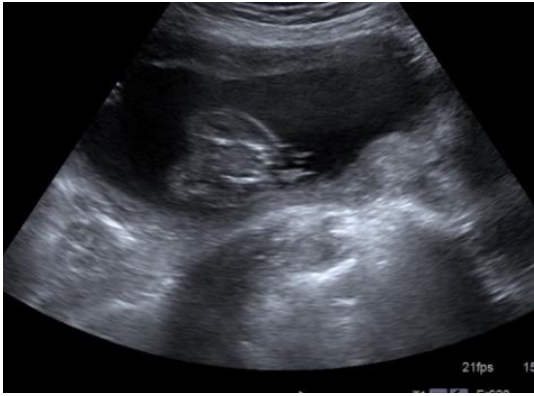CASE NO: 5

A woman of 25 years old, with history of 19 weeks gestation with no significant relevant clinical history. Fetus shows features of Arnold Chiari malformation with evidence of lemon shaped skull, banana shaped cerebellum and Lumbar meningomyelocele

Lemon shaped skull



Meningomyelocele

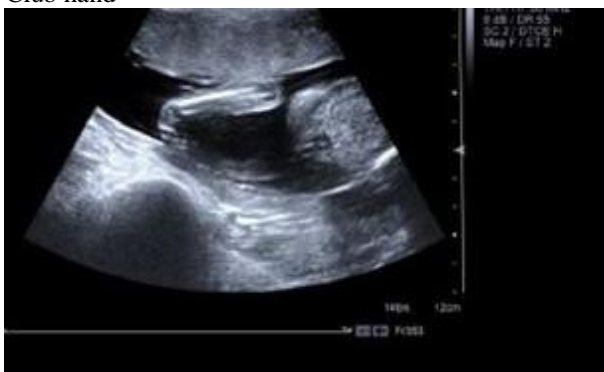

Banana shaped cerebellum with narrowed cisterna magna

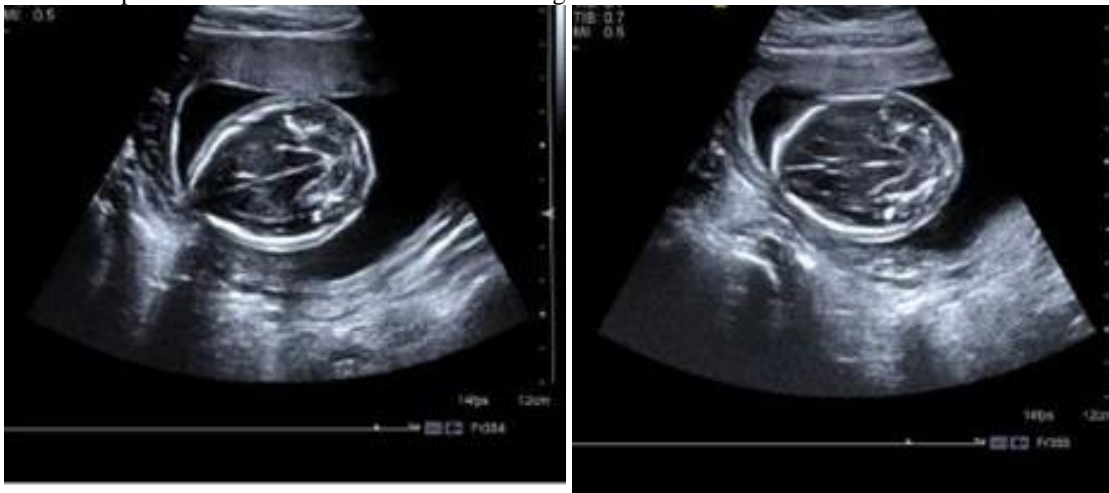CASE NO : 6

ARNOLD CHIARI MALFORMATION WITH BILATERAL CLUB HAND AND FOOT

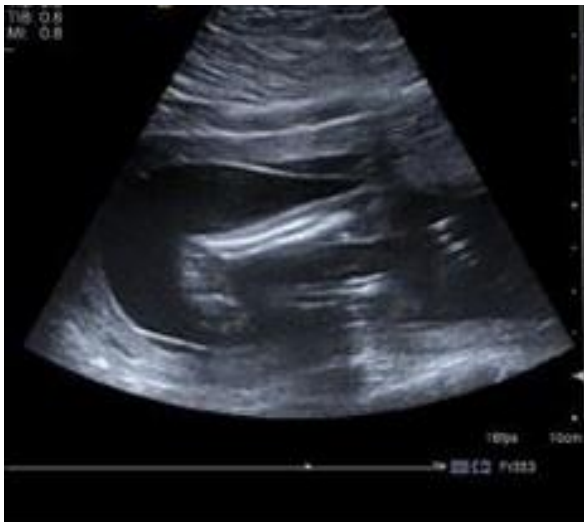
Club hand



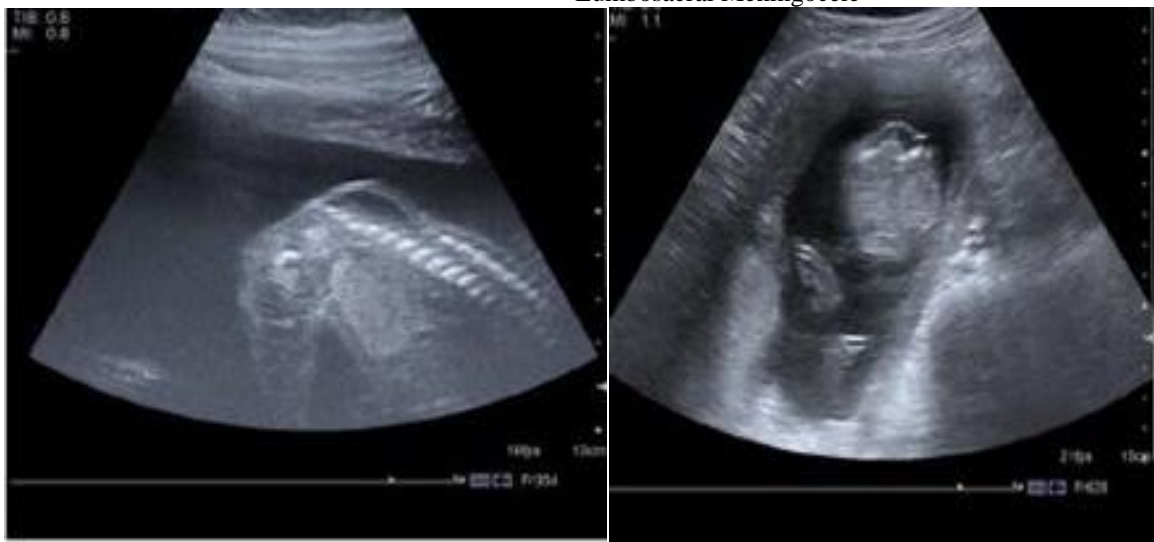
Banana shaped cerebellum with effaced cisterna magna

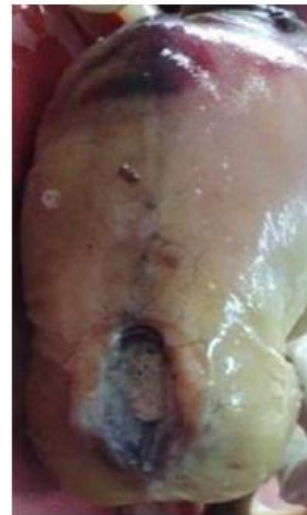
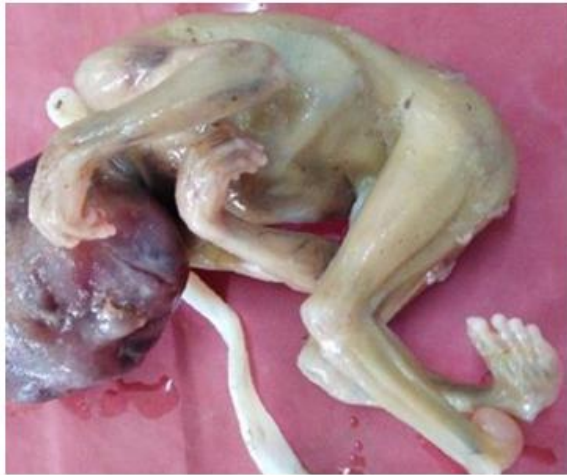
Club foot



Lumbosacral Meningocele





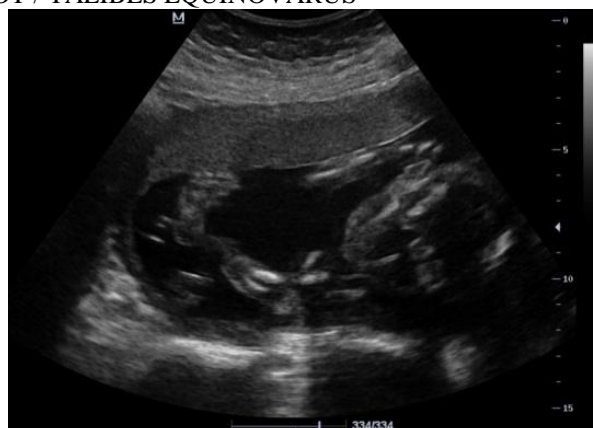A 25-year-old pregnant woman with history of second degree consanguineous marriage came for anomaly scan at 20 weeks of gestation. Patient had history of bipolar disorder and was on regular antipsychotics treatment. Patient stopped antipsychotic medication after confirmation of pregnancy. No other history of familial genetic disorder. In sonographic study at 20 weeks of gestation, multiple fetal anomalies were noticed: Lemon shaped skull, Lumbosacral meningomyelocele, Banana sign of cerebellum and obliteration of cisterna magna and Bilateral club foot deformity and bilateral club hand deformity. (20, 21, 22) Based on these sonographic findings, Arnold Chiari malformation type II was diagnosed. Medical termination of pregnancy was done with delivery of 260 gms dead fetus with deformed scalp, hand, foot with spinal defect. There are four types of Arnold Chiari malformation, among these type II and III can be identified by ultrasound. There is displacement of midbrain, cerebellum inferiorly possibly due to small posterior fossa in Type II and III of Arnold Chiari malformation. Banana shaped cerebellum with varying degree of effacement of cisterna magna also noted depending upon the severity. Ventriculomegaly can be identified and Atrium of lateral ventricle measures more than 10 mm in diameter. Lemon sign of skull represents pinching of frontal bone. Other supratentorial abnormalities are dysplasia of corpus callosum, obstructive hydrocephalus and absent septum pellucidum. (20,21,22). In our both these cases size of lateral ventricle was within in normal limit. (less than 10 mm at atrial level)

Many skeletal abnormalities also seen with Arnold Chiari malformation, like spinal scoliosis, Klippel feil syndrome, atlantoaxial assimilation, Luckenschadel skull, club foot. Association of bilateral club hand which was found in our second case, was not mentioned in the literature as far as our knowledge concerned. We lost the follow up of first case (case No: 5) and second one underwent MTP, sonographic findings were confirmed clinically, Pictures were also given above. Autopsy not done since parents not giving consent for that.

CASE NO: 7

A 30 years female with history of 21 Weeks gestation came for anomaly scan. Fetus showed isolated right club foot with no associated other anomalies.

UNILATERAL CLUB FOOT / TALIBES EQUINOVARUS



Talipes equinovarus or Clubfoot is a common foot deformity in which, foot is excessively plantar flexed and medially adducted. Sole is facing inward. This deformity is due to underdevelopment of the soft tissues on the medial side of the foot and calf and due to rigidity of the foot and calf. The deformity does not resolve spontaneously and not passively correctable. Incidence of Clubfoot is about 0.1 % newborn populations and 0.4 % in antenatal ultrasound. (24)

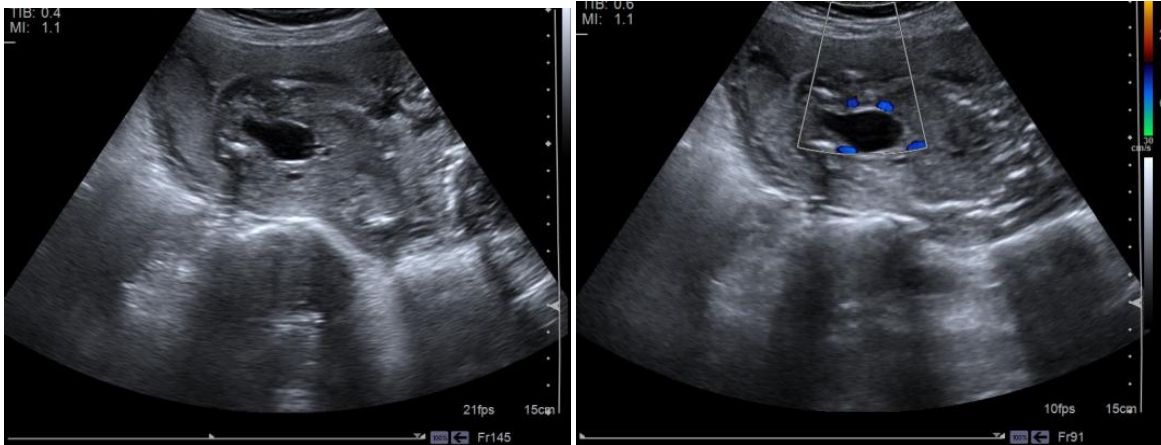
Male are more commonly affected than females, with a 2:1 predisposition (23). In 50 % patient's club foot occurs bilaterally. 80 % fetus of club foot usually associated with other structural abnormalities. Club foot can also occur isolated and with no association with other abnormalities. Unilateral club foot did not show side predominance. (25,26, 27,28,29) This condition may also associated with genetic syndromes (23,25)

CASE NO: 8

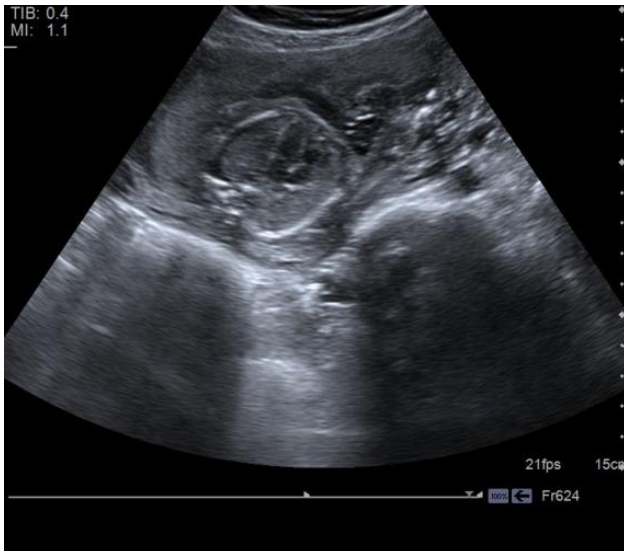
A 25 year old female with history of 20 weeks gestation came for antenatal scan, with no significant previous past history. No history of consanguineous marriage.

Antenatal scan shows a male fetus with evidence of , Severe oligohydraminos, Key hole urinary bladder evidence of posterior urethral valve, Bilateral echogenic kidneys - renal dysplasia, Left pleural effusion, Heart, brain and spine appeared normal.

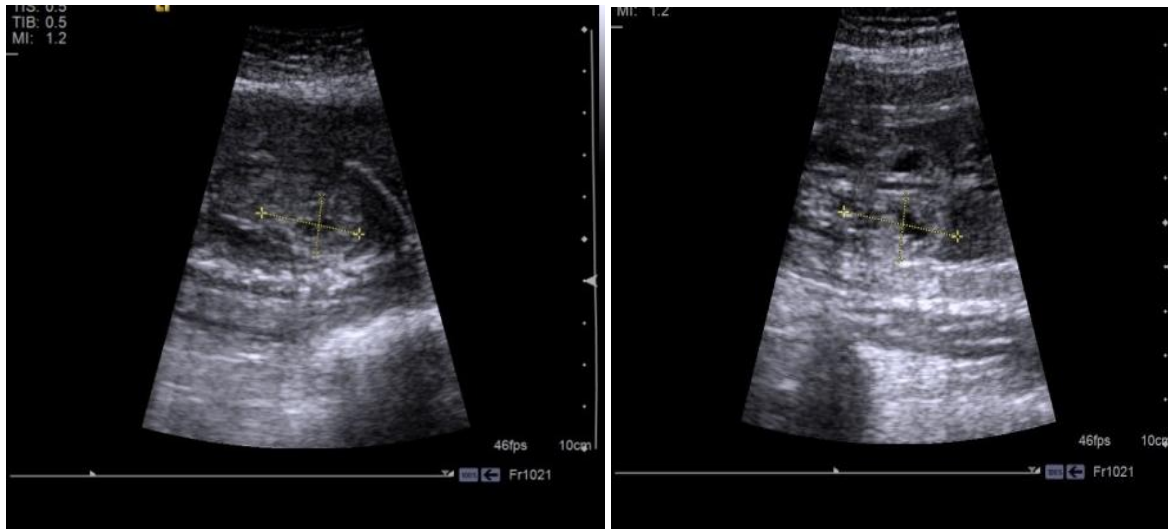
KEY HOLE URINARY BLADDER



LEFTPLEURAL REFFUSION



ECHOGENIC KIDNEYS



Posterior urethral valves are valve like membrane in the distal prostatic urethra, are congenital in nature and only seen in male infants (30) and also called as congenital obstructing posterior urethral membranes (COPUM). It is most common cause of obstructive uropathy in infancy. The estimated incidence is at ~1 in 10,000-25,000 live births with a higher rate of occurrence *in utero*. Most of the cases are sporadic, although rare examples of PUVs occurring in families have been reported (27). Posterior urethral valves are thick membrane that courses obliquely from the verumontanum to the most distal portion of the prostatic urethra. This process usually occurs in early gestation at 5-7 weeks (28,29)

There are three types of posterior urethral valves. The original classification of posterior urethral valve is proposed by Young (30) in 1919, which is still in use. Type I valve is a mucosal fold, the majority type and starts from caudal aspect of verumontanum and fuses together anteroinferiorly at lower level. Type II types are also mucosal fold seen above the level of verumontanum, extending up to bladder neck, antero posteriorly. Type II are rare, probably due to effect of bladder obstruction, rather than causing bladder obstruction. Type III are disc like membrane, unrelated verumontanum, located in the membranous urethra level, occurs due to abnormal canalization of urogenital membrane.

Posterior urethral valves are also associated with other congenital anomalies likely⁽³⁰⁾, chromosomal abnormalities, e.g. Down syndrome⁽³¹⁾, bowel atresia, and craniospinal defects.

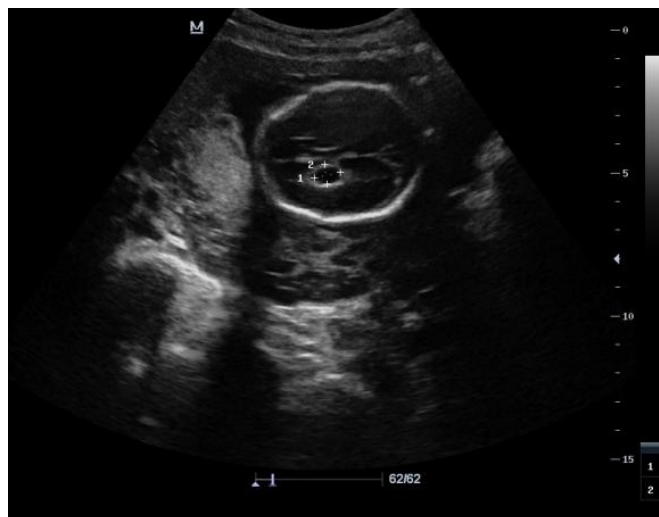
In antenatal imaging, there is marked distension and hypertrophy of urinary bladder. Key hole sign of bladder also noted, caused by dilated urinary bladder and dilated prostatic urethra, which is best appreciated in coronal view of pelvis. In case of significant posterior urethral valve obstruction, there will be bilateral hydronephrosis and hydroureter. In case of severe cases, there will be oligohydramnios and renal dysplasia. Renal dysplasia which is expressed by increased echogenicity of renal parenchyma indicates poor function. (30,31). These findings are generally not identified before 26 weeks of gestation, and are not frequently identified on routine morphology screening, usually carried out around 18 to 24 weeks gestation (31)

Dilated posterior urethra is most specific and sensitive to the diagnosis. Diameter of posterior urethra more than 6 mm is considered abnormal. (sensitivity 100%, specificity 89%, positive predictive value 88%) (35). Fetus may develop complication like rupture of fornix causing para renal urinomas which seen as anechoic collection around the kidneys and intraperitoneal bladder rupture, presenting as ascites. (31,34)

Antenatally, vesicoamniotic shunting can be done allowing urine to exit the bladder via the shunt, bypassing the obstructed urethra. This procedure performed under ultrasound guidance. The efficacy of this procedure is controversial. (30,31). Postnatally, transurethral ablation of posterior urethral valve is definite treatment.(34). Overall prognosis of this condition is depending upon the severity and duration of obstruction. This condition is incompatible life when is associated with renal dysplasia, oligohydramnios and pulmonary dysplasia. Urethral Arterial is another uncommon differential diagnosis (29, 30)

CASE NO 9 :

22 years old female with history of 21 weeks 2 days gestation came for routine second trimester scan with no positive personal and family history. Choroid plexus cyst measures 0.9 x 0.6 cm noted in the right lateral ventricle. No other sonographically demonstrable anomaly identified at this period of gestation. There was complete resolution of cyst in follow up third trimester scan.



Antenatal choroid plexus cysts are benign lesion seen at the level of atria involving the lateral ventricles. Choroid plexus cyst have no epithelial lining , usually CSF filled area within the choroid plexus. These lesions resolve in the third trimester. Estimated occurrence approximately 2 % of pregnancies. Size is varies from millimeter to 1 to 2 cm in diameter. are often transient typically resulting *in utero* from an infolding of the neuroepithelium (35,36,13) There is a soft association with aneuploidy (trisomy 18, trisomy 21, Klinefelter syndrome, Aicardi syndrome) . Ultrasound shows anechoic lesion in the atria of lateral ventricles. Wall may be echogenic due to surrounding choroid plexus. Choroid plexus cyst usually detected in second trimester in the lateral ventricles. The size and number of cysts are thought to affect the risk of aneuploidy by some authors. Antenatal choroid plexus cyst are of no clinical significance and generally disappear in third trimester by 26 to 28 weeks. If cyst is large, obstructive hydrocephalus may occur, it is rare. Cyst are not associated with abnormal CNS development. If choroid plexus cysts are bilateral, multiple or larger in size, associated karyotyping abnormalities to be excluded by amniocentesis.

References

- [1]. Martínez-Frías, Egüés et al. Thanatophoric - dysplasia type II with encephalocele and semilobar holo- prosencephaly Am J Med - Genet 2011;155A(1):197–202.
- [2]. Keaton AA, Solomon BD, van Essen AJ, et al. Holo- prosencephaly and ectrodactyly: report of three new patients and review of the literature. Am J Med Genet C Semin Med Genet 2010;154C(1):170–175
- [3]. Roessler , Muenke . The molecular genetics of holoprosencephaly. Am J Med Genet 2010;154C (1):52–61.
- [4]. Hahn JS, Barnes PD. Neuroimaging advances in holo-prosencephaly: refining the spectrum of the midline malformation. Am J Med Genet 2010; 154C (1):120–132.
- [5]. Metwalley Kalil , Fargalley . Holoprosencephaly in an Egyptian baby with ectro-dactyly–ectodermal dysplasia–cleft syndrome: a case report. J Med Case Reports 2012;6(1)
- [6]. Sarnat HB, Flores-Sarnat L. Neuropathologic research strategies in holoprosencephaly. J Child Neurol 2001;16(12): 918–931.
- [7]. Orioli IM, Castilla EE. Epidemiology of holoprosencephaly: prevalence and risk factors. Am J Med Genet C Semin Med Genet 2010;154C(1):13–21
- [8]. Rizos M, Spyropoulos MN. Vander Wou de syndrome. a review of cardinal signs, epidemiology, associated features, differential diagnosis, expressivity, genetic counselling and treatment. Eur J Orthod 2004;26(1):17–24.
- [9]. Ten Cate AR. Embryology of the head, face, and oral cavity. In: Ten Cate AR, ed. Oral histology: development, structure, and function. 3rd ed. St Louis, Mo: Mosby, 1989.
- [10]. Lee KH, Hayward P. Retrospective review of Stickler syndrome patients with cleft palate 1997–2004. ANZ J Surg 2008;78(9):764–766.
- [11]. Cooper , Stone, Liu Y. Descriptive epidemiology of non- syndromic cleft lip with or without cleft palate in Shanghai, China, Cleft Palate Craniofac J 2000;37(3):274–280.
- [12]. Snead MP, Yates JR. Clinical and molecular genetics of Stickler syndrome. J Med Genet 1999;36(5):353–359.
- [13]. Norton KI, Rai B, Desai H et-al. Prevalence of choroid plexus cysts in term and near-term infants with congenital heart disease. AJR Am J Roentgenol. 2011;196 (3): W326-9
- [14]. Gross GW. Pediatric chest imaging. 1992;4 (5)
- [15]. Rempen A, Fage A, Winsch P. Prenatal diagnosis of bilateral cystic adenomatoid malformation of lung JCU 1987. 15
- [16]. Adzick Ns, Harrison MR, Glick PL et at: Fetal cystic adenomatoid malformation. Prenatal diagnosis and natural history. J Pediatrics Surg 1985 483 -488
- [17]. Paladini D, Volpe P. Ultrasound of Congenital Fetal Anomalies. Informa HealthCare. (2007) ISBN:041541444X.
- [18]. Sepulveda W, Stagiannis KD, Flack NJ, Fisk NM. Accuracy of prenatal diagnosis of renal agenesis with color flow imaging in severe second-trimester oligohydramnios. Am J Obstet Gynecol 173(6):1788-92, 1995.
- [19]. Babcook CJ, Goldstein RB, Barth RA, Damato NM, Callen PW, Filly RA. Radiology. 1994; 190(3): 703.
- [20]. McLone DG, Dias MS. . 2003; 19(7-8): 540-550
- [21]. Barkovich JA. Barkovich JA(ed). , PA: Lippincott Williams & Wilkins; 2005: 378-384.

Series Of Fetal Structural Abnormalities Detected By Ultrasonogram During Second Trimester ..

- [22]. Penso C, Redline RW, Benacerraf BR. J Ultrasound Med. 1987; 6(6):307- 311 10. Ball RH, Filly RA, Goldstein RB, Callen PW. J Ultrasound Med. 1993; 12(3): 131-13
- [23]. Malone FD, Marino T, Bianchi DW, Johnston K, D'Alton ME. Isolated clubfoot diagnosed prenatally: is karyotyping indicated? Obstet Gynecol 2000;95:437-40.
- [24]. Carroll NC. Clubfoot. Pediatric orthopaedic secrets: Hanley and Belfus; 1998. p. 230-4.
- [25]. Rijhsinghani , Yankowitz . Antenatal sonographic diagnosis of club foot with particular attention to the implications and outcomes of isolated club foot. Ultrasound Obstet Gynecol 1998;11:103-106.
- [26]. Yamamoto H. A clinical, genetic and epidemiologic study of congenital clubfoot. Jpn J Hum Genet 1979;24:37-44.
- [27]. Chudleigh P, Thilaganathan B, Chudleigh T. Obstetric ultrasound, how, why and when. Churchill Livingstone. (2004) ISBN:0443054711.
- [28]. Blews DE. Sonography of the neonatal genitourinary tract. Radiol. Clin. North Am. 1999;37 (6): 1199-208, vii.
- [29]. Entezami M, Albig M, Knoll U et-al. Ultrasound Diagnosis of Fetal Anomalies. Thieme. (2003) ISBN:1588902129
- [30]. Young HH, Frontx WA, Baldwin JC. Congenital obstruction of posterior urethra. J Urol 1919.3:289-365
- [31]. Bruyn RD. Pediatric ultrasound, how, why and when. Churchill Livingstone. (2005) ISBN:0443072752.
- [32]. Nyberg DA, McGahan JP, Pretorius DH. Diagnostic imaging of fetal anomalies. Lippincott Williams & Wilkins. (2003) ISBN:0781732115.
- [33]. Entezami M, Albig M, Knoll U et-al. Ultrasound Diagnosis of Fetal Anomalies. Thieme. (2003) ISBN:1588902129.
- [34]. Bianchi DW, Crombleholme TM, D'Alton ME. Fetology, diagnosis & management of the fetal patient. McGraw-Hill Professional. (2000) ISBN:0838525709
- [35]. Naeini RM, Yoo JH, Hunter JV. Spectrum of choroid plexus lesions in children. AJR Am J Roentgenol. 2009;192 (1): 32-40
- [36]. Deroo TR, Harris RD, Sargent SK et-al. Fetal choroid plexus cysts: prevalence, clinical significance, and sonographic appearance. AJR Am J Roentgenol. 1988;151 (6): 1179-81.

Dr. Sundara Raja Perumal R "Series Of Fetal Structural Abnormalities Detected By Ultrasonogram During Second Trimester Anomaly Scan "IOSR Journal of Dental and Medical Sciences (IOSR-JDMS), Volume 17, Issue 2 (2018), PP 14-27.