

Benign Cause of Adult Colocolic Intussusception: A Case Report

Dr Hitesh Kumar^{1*}, Dr Pavitra Dosaj²

¹Senior resident, Department of General Surgery, NDMC Medical College & Hindu Rao Hospital, New Delhi, India

²Assistant professor, Department of General Surgery, NDMC Medical College & Hindu Rao Hospital, New Delhi, India

*Corresponding Author: Dr Hitesh Kumar¹

Abstract: Intussusception is a rare entity in adults accounting for nearly 2 % cases of obstruction. The condition is more frequently encountered in pediatric population compared to adults. In small bowel most of the lead points are benign lesion whereas in large bowel percentage of malignant lead point is much more. We present a case of 43 year old lady who presented with colocolic intussusception. The patient presented with features of acute intestinal obstruction. On exploration proximal part of transverse colon was telescoping into distal one with intraluminal pedunculated fibrofatty tissue as a lead point. The present study discusses the role of colonoscopy and CECT in preoperative workup and the treatment modality of choice for management of such cases.

Keywords: Colocolic intussusception, submucosal lipoma, Colonoscopy.

Date of Submission: 05-02-2018

Date of acceptance: 19-02-2018

I. Introduction

Intussusception may be defined as telescoping of proximal gastrointestinal tract in to the adjacent distal one.¹ The part which telescopes is known as intussusceptum and the recipient portion is known as intussusceptum. The condition is more frequently encountered in pediatric population compared to adult ones where it is rare. In adults, intussusception cause less than 2% causes of intestinal obstruction.²

The median age of presentation in adults is in 6th to 7th decade.² The etiology of intussusception differs greatly in adult and children. In almost all cases of adult intussusception there is demonstrable inflammatory lesion or neoplasm is present which act as a lead point. Neoplasms causing adult intussusception are malignant in more than 90% cases.²

Submucosal lipoma of the colon as lead point is noted in 0.2-0.4% cases.³ though being rare these lipomas are most common benign non epithelial tumors found in gastrointestinal tracts and overall third commonest tumors after hyperplastic and adenomatous polyps.⁴ Intraluminal lesion along with food particles and peristaltic activity leads to narrowing above the stimulus and relaxation below, thus making the lead point (intussusceptum) telescope to the distal bowel (intussusceptum).^{1,5}

We present a case of 43 year old lady who presented with colocolic intussusception with intraluminal, pedunculated fibrofatty tissue as lead point.

II. Case Report

A 43 year old lady with no significant medical and surgical history presented to surgical emergency with abdominal distension and non passage of faeces and flatus for last 2 days. She also gives history of multiple episodes of greenish vomiting and pain in upper abdomen for last 1 day.

On examination she was afebrile; blood pressure was 116/78 mm of Hg, Pulse rate was 90 beats per minute. On examination of the abdomen, visible bowel loops were present. A firm lump of size 10x 6 cm was palpable in left hypochondrial region which was not moving with respiration. No guarding and rigidity was observed over abdomen, tenderness was noted over the lump but there was no rebound tenderness. Bowel sounds were sluggish. On per rectal examination tarry black matter was present, rest all findings were normal.

Biochemical analysis revealed Haemoglobin of 11.2 Gm%, TLC count of 9100 cells/mm³, rest all investigations were within normal range. X-ray abdomen revealed multiple air fluid levels, USG was suggestive of intussusception. CECT abdomen also confirms the findings of USG.

Considering the features of acute intestinal obstruction, patient was planned for exploratory laparotomy. Intraoperatively one portion of the transverse colon appeared to be telescoping in to other. A firm mass of size 5x6 cm appeared to be the lead point. The intussusception part was non reducible. Considering it to be tumor, taking adequate margin colonic resection was done bilaterally. End to end colocolic anastomosis was done with single layer interrupted sutures after mobilizing the hepatic flexure of colon.

A covering ileostomy was also done. Abdominal drain was placed. Cut section of the specimen showed firm polypoidal growth on antimesentric wall of lumen. Postoperative period was uneventful, ileostomy started functioning on 2nd day, patient was orally allowed on 3rd day, and drain was removed on 4th day. She was discharged in satisfactory condition on 7th day. Ileostomy closure was done 2 months after first surgery. Histopathological examination revealed fibrofatty tissue with no signs of neoplastic growth. Patient was followed up for 1 year, no complication arises.

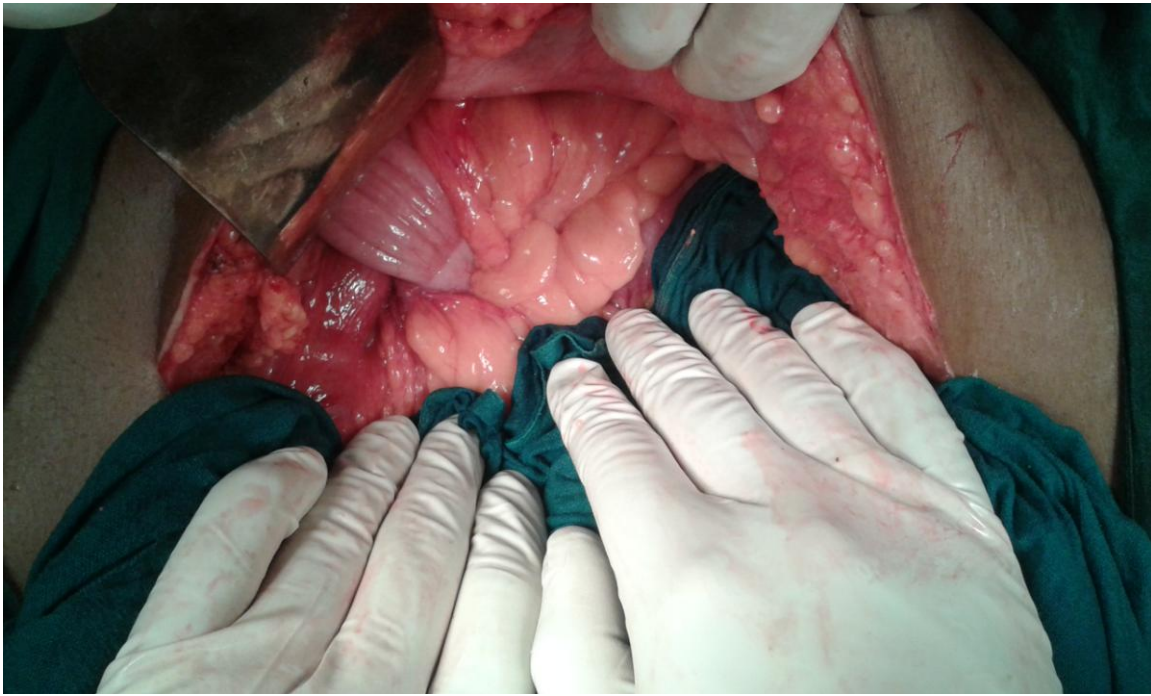


Figure 1

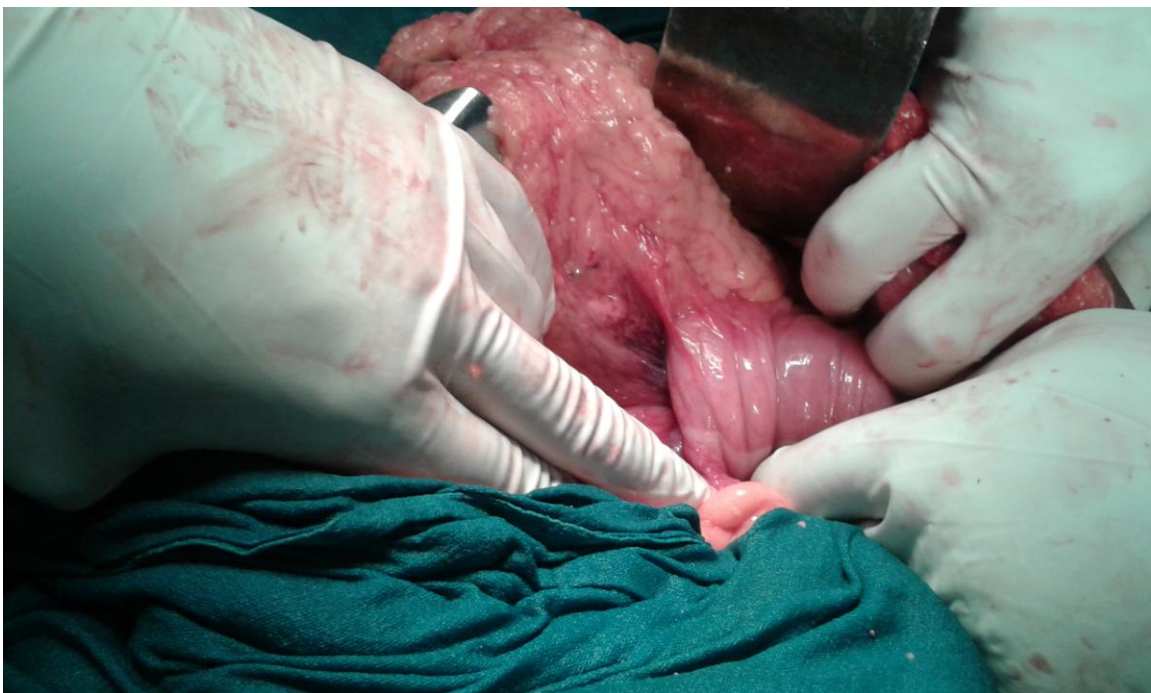


Figure 2

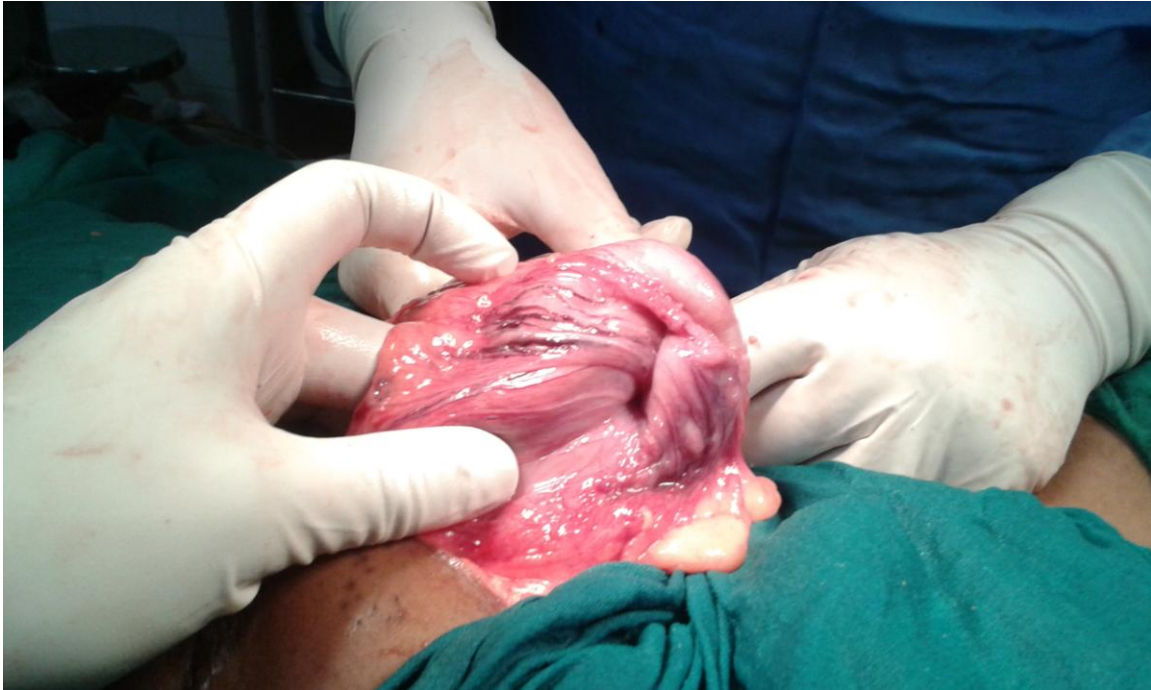

Figure 3

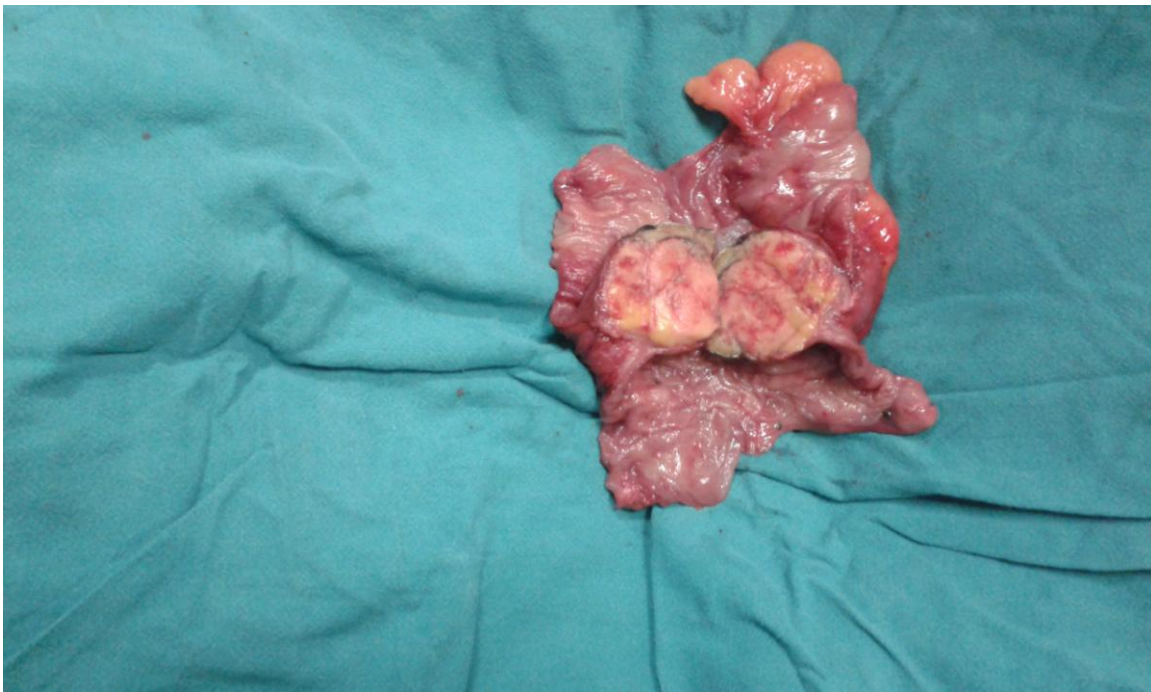

Figure 4

III. Discussion

Intussusception is a rare entity in adults accounting for nearly 2 % cases of obstruction.² In small bowel most of the lead points are benign lesion whereas in large bowel percentage of malignant lead point is much more, ratio being 1:3.^{6, 7} Adenocarcinoma is the most common malignant lesion found in colocolic intussusception in up to 64% of cases,^{7, 8} benign lead point is observed far rarely.³

Our patient presented with features of acute intestinal obstruction with palpable abdominal lump which is a relatively less common finding.^{6, 7} One study revealed a palpable abdominal mass in 62.3% cases whereas other studies have indicated abdominal mass findings in between 24 and 42%.^{9, 10} Other complaints include nausea and vomiting (36–82%), diarrhea, bleeding or melena (18–29%) and constipation (4–29%).^{5, 11}

X-ray abdomen shows multiple air fluid levels suggesting acute intestinal obstruction, USG abdomen revealed telescoping of one part of transverse colon in to other. Abdominal Computed tomography is the most sensitive investigation for diagnosis of intussusception.^{7, 8} On CT scan presence of target sign is characteristic which is also visible on USG abdomen.¹² After making diagnosis of intussusception exploration was planned and the involved segment was resected and end to end colocolic anastomosis done.

IV. Conclusions

Adult colocolic intussusception is a rare entity diagnosed on USG abdomen and CECT. Colonoscopy should be performed to identify the location of the lesion as a preoperative workup and evaluating whether there are any synchronous lesions that may be malignant and not seen on CT scan. As there is a 64% higher risk of malignancy in adults, surgical en-bloc resection is the treatment of choice. Edoscopic reduction should be considered only in non emergent situations where benign nature of the lesion is already proven.

Acknowledgement

Nil

References

- [1]. Azar T, Berger DL. Adult intussusception. *Ann Surg.* 1997; 226: 134–138.
- [2]. Michael J Zinner, Stanley W Ashley, Intussusception. In; *Maingot's Abdominal Operations: 12th edition*: The McGraw Hill Companies, Inc. 2013. p. 593-594.
- [3]. Paškauskas S., Latkauskas T., Valeikaite G., et al. Colonic intussusception caused by colonic lipoma: a case report. *Medicina.* 2010; 46(7):477–481.
- [4]. Arora R., Kumar A., Bansal V. Giant rectal lipoma. *Abdominal Imaging.* 2011; 36(5):545–547.
- [5]. Nagorney DM, Sarr MG, McIlrath DC. Surgical management of intussusception in the adult. *Ann Surg.* 1981; 193:230–236.
- [6]. Begos DG, Sandor A, Modlin IM. The diagnosis and management of adult intussusception. *Am J Surg.* 1997; 17:88–94.
- [7]. Wang LT, Wu CC, Yu JC, Hsiao CW, Hsu CC, Jao SW. Clinical entity and treatment strategies for adult intussusceptions: 20 years' experience. *Dis Colon Rectum.* 2007; 50:1941–1949.
- [8]. Yakan S, Caliskan C, Makay O, Denecli AG, Korkut MA. Intussusception in adults: clinical characteristics, diagnosis and operative strategies. *World J Gastroenterol.* 2009; 15:1985–1989.
- [9]. Gupta RK, Agrawal CS, Yadav R, Bajracharya A, Sah PL. Intussusception in adults: institutional review. *Int J Surg.* 2011; 9:91–95.
- [10]. Hanan B, Diniz TR, da Luz MM, da Conceição SA, da Silva RG, Lacerda-Filho A. Intussusception in adults: a retrospective study. *Colorectal Dis.* 2010; 12:574–578.
- [11]. Goh BKP, Quah HM, Chow PKH, Tan KY, Tay KH, Eu KW, Ooi LL, Wong WK. Predictive factors of malignancy in adults with intussusception. *World J Surg.* 2006; 30:1300–1304.
- [12]. Gayer G, Apter S, Hofmann C, Nass S, Amitai M, Zissin R, Hertz M. Intussusception in adults: CT diagnosis. *Clin Radiol.* 1998; 53:53–57.

Dr Hitesh Kumar "Benign Cause of Adult Colocolic Intussusception: A Case Report. "IOSR Journal of Dental and Medical Sciences (IOSR-JDMS), Volume 17, Issue 2 (2018), PP 40-43.