

## A Clinical Study of Precancerous Lesions of Oral Cavity In Patients Attending A Tertiary Care Centre Of Jharkhand

Dr. R.K.Choudhary<sup>1</sup>, Dr. Amit Kumar<sup>2</sup>

1. Associate professor, Department of Otorhinolaryngology, Rajendra Institute of Medical Sciences, Ranchi.

2. Senior Resident, Department of Otorhinolaryngology, Rajendra Institute of Medical Sciences, Ranchi.

Corresponding author: Dr. R.K.Choudhary1

**Abstract: Introduction:** Precancerous lesions of oral mucosa, now known as potentially malignant disorders, need to be diagnosed in the early stage for further proper management. Oral leukoplakia, oral submucous fibrosis, oral erythroplakia, traumatic dental ulcers and oral lichen planus are the major ones encountered in our Out Patient Department (OPD). Most of the patients give a history of addiction to chewing tobacco or betelnut and smoking. **Objectives:** To assess the prevalence of oral potentially malignant disorders and to determine the socio-demographic profile and the potential risk factors for their development in population of Jharkhand. **Materials and Methods:** This is a retrospective study carried over a period from November, 2015 to January, 2017. Total sample size was 106. The data was collected from OPD register, ENT and analysed using SPSS software (Version 20). **Results:** Of all 106 patients included in the study, Oral Submucous Fibrosis (OSF) was the most common precancerous lesion (55.7%) identified, followed by Oral Leukoplakia (OL) (20.8%). Oral Erythroplakia (OE) (9.4%), Traumatic Dental Ulcers (TDU) (7.5%) and Oral Lichen Planus (OLP) (6.6%) were the other lesions identified in the order of frequency of occurrence. Maximum patients were in age group 45-55 years (32%) and most of them were males (69.8%). Tobacco addiction (29.5%) was most common and addiction for 1-5 years (41%) was most commonly encountered. **Conclusion:** OSF is the most common precancerous lesion of oral cavity encountered amongst the patients attending ENT OPD, RIMS. The precancerous lesions are most commonly encountered in males of age group 45-55 years. Addiction to tobacco is most common.

**Key Words :** Precancerous, oral cavity, addiction..

Date of Submission: 16-03-2018

Date of acceptance: 30-03-2018

### I. Introduction

The common oral precancerous lesions are oral leukoplakia, oral submucous fibrosis (OSMF), and oral erythroplakia. Traumatic dental ulcers and oral lichen planus are the other major contributors to the list.

Although the etiological factors vary in various studies, the etiology of most of these diseases is not understood completely<sup>1</sup>. The most frequently encountered factors are tobacco chewing, alcohol drinking, chewing of betel quid containing areca nut, smoking and solar rays. While tobacco chewing is a major risk factor for oral leukoplakia, OSMF, and erythroplakia, tobacco smoking may be a risk factor for oral leukoplakia. Alcohol drinking may increase the risk for oral leukoplakia by 1.5-fold, by 2-fold for OSMF, and 3-fold for erythroplakia.

Early diagnosis can be lifesaving and hence important, since the disease may progress to severe dysplasia and even carcinoma in situ and/or squamous cell carcinoma in later stages. Miscellaneous modalities such as oral cavity examination, supravital staining, oral cytology and optical technologies including spectroscopy, fluorescence spectroscopy, elastic scattering (reflectance) spectroscopy, Raman spectroscopy, fluorescence imaging, optical coherence tomography, narrow-band imaging, and multimodal optical imaging may be used<sup>2</sup>.

The criteria to be considered relative to the importance of early diagnosis are

- (1) Symptomatic and/or non-symptomatic non-healing lesions of oral mucosa;
- (2) History of smoking, chewing tobacco, alcohol consumption, oral HPV infection, drug use, long-term exposure to sunlight;
- (3) Advanced age;
- (4) The presence of immunodeficiency;
- (5) The presence of genetic disease; and
- (6) Poor oral hygiene.

The diagnosis must be confirmed by biopsy since clinically, these diseases may resemble each other. The histopathological findings are distinctive in early stages, but in case malignant transformation occurs,

identical histological features with oral carcinoma are seen. Left untreated, they may cause problems affecting the patient's social and daily life.

**Leukoplakia** is defined as "A white plaque of questionable risk having excluded (other) known diseases or disorders that carry no increased risk for cancer"<sup>2</sup>. The prevalence of oral leukoplakia varies between 1.1% and 11.7%, with a mean value of 2.9%<sup>5</sup>. It often occurs in individuals under the age of 40, although can occur at any age<sup>6</sup>. Leukoplakia is six times more common amongst smokers than the non-smokers<sup>4</sup>.

Clinically it may affect any part of the oropharyngeal cavity. It is divided into two subtypes, the homogeneous and non-homogeneous types<sup>4</sup>. Homogenous lesions are characterized by uniformly flat, thin, uniformly white in colour and shows shallow cracks of the surface keratin<sup>4,7</sup>. Non-homogenous lesions are defined as a white and red lesion (known as *erythroleukoplakia*) that may be either irregularly flat (speckled) or nodular. Verrucous leukoplakia is a type of non-homogenous leukoplakia<sup>8</sup>.

Proliferative verrucous leukoplakia is a form of verrucous leukoplakia, characterized by multifocal presentation with a strong potential for malignant transformation, resistant to treatment and was first described by Hansen et al<sup>8,9</sup> in 1985.

Histopathologically, two distinct appearances are possible: dysplastic or non-dysplastic leukoplakia.

The differential diagnosis includes aspirin burn, chemical injury, oral pseudomembranous and hyperplastic candidiasis, frictional lesions, oral hairy leukoplakia, leukoedema, linea alba, lupus erythematosus, morsicatio buccarum, papilloma and allied lesions, mucous patches in secondary syphilis, tobacco-induced lesions, smoker's palate (nicotinic stomatitis), stuff-induced lesion, white sponge nevus, oral lichen planus (OLP), and lichenoid reaction<sup>4,7</sup>.

**Erythroplakia** is defined as "A fiery red patch that cannot be characterized clinically or pathologically as any other definable disease". Clinically these are characterized by flat or depressed erythematous change of the mucosa without a patch lesion. Both red and white changes in the same lesion refer to as "*erythroleukoplakia*". Prevalence of erythroplakia is usually between 0.02% and 0.83%. It mainly occurs in the middle aged and the elderly. Males are most frequently affected. The most commonly affected areas were the soft palate, the floor of the mouth, and the buccal mucosa<sup>8,10</sup>.

**Oral lichen planus** is a chronic, autoimmune, inflammatory disease which may affect skin, oral mucosa, genital mucosa, scalp, and nails<sup>11</sup>. Prevalence of OLP is usually between 0.5% to 3%<sup>12</sup>. It mostly affects females and the age of onset is usually between third and sixth decade<sup>12,13</sup>.

**Oral submucous fibrosis** is chronic and potentially malignant disorder characterized by juxtaepithelial fibrosis of the oral cavity, with consequent fibroelastic change of the lamina propria and epithelial atrophy, and finally, stiffness of oral mucosa, trismus and an inability to eat<sup>14</sup>.

## II. Materials And Methodology

After clearance from the ethical committee, an informed consent was taken from the patients willing to participate in the study. A detailed history of his/her complaints and a proper examination of each patient were undertaken. All patients with oral precancerous lesions, i.e. OSF, OL, OE, TDU and OLP, who gave consent for biopsy, were included in the study. Following cases were excluded from the study:

- a) Patients with conditions other than those included in the study.
- b) Patients with known or suspected malignant condition.
- c) Patients whose biopsy results were different from the lesions included in our study.

The data was analysed using SPSS software (version 20).

## III. Results

Out of the 106 cases studied, maximum were diagnosed as OSF (55.7%), followed by OL (20.8%) and OLP cases were least in number (6.6). The causes for highest frequency of cases of OSF are the early symptoms presentation and early medical consultation by patients for the same, as against OL that presents as a painless plaque in oral cavity. **Table 1.** Shows the types of precancerous lesions with their frequencies of occurrence in the study group.

**Table 1.** Types of precancerous lesions

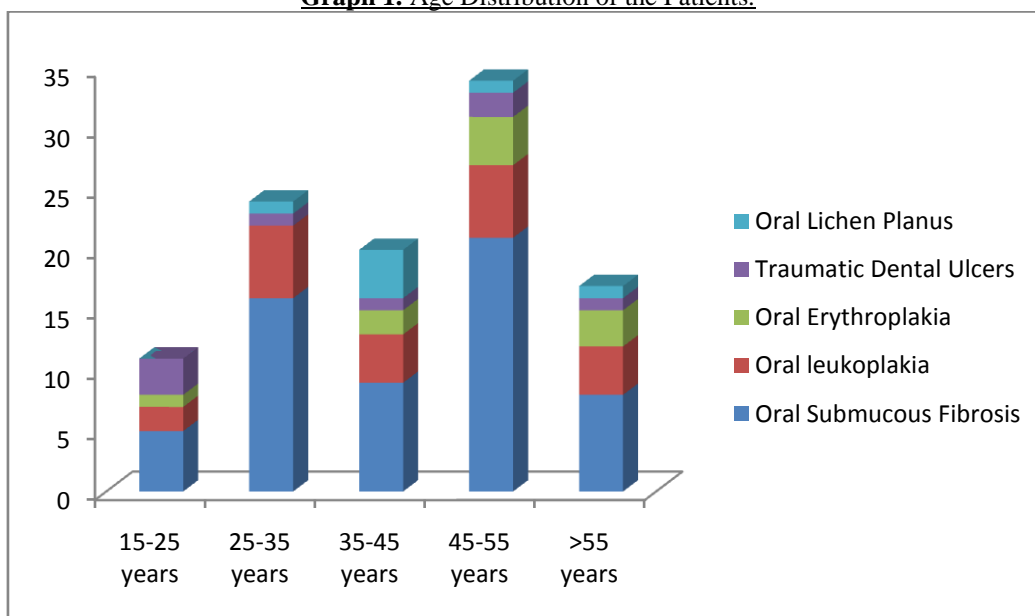
Serial No.	Lesion	Number (n)	Frequency (%)
1	Oral Submucous Fibrosis	59	55.7
2	Oral leukoplakia	22	20.8
3	Oral erythroplakia	10	9.4
4	Traumatic dental ulcer	8	7.5
5	Oral lichen planus	7	6.6

Maximum cases were in the age group 45-55 years (32%). Of all the cases of OSF, maximum cases were in age group 45-55 years, the youngest patient being a 19 year old male and eldest being an 85 year old male, showing wide age distribution. **Graph 1** and **Table 2** depict the age distribution of all the patients included in the study.

**Table 2.** Age distribution of the patients.

Lesion	15-25 years	25-35 years	35-45 years	45-55 years	>55 years
Oral Submucous Fibrosis	8	5	16	9	21
Oral leukoplakia	4	2	6	4	6
Oral erythroplakia	3	1	0	2	4
Traumatic dental ulcers	1	3	1	1	2
Oral lichen planus	1	0	1	4	1

**Graph 1.** Age Distribution of the Patients.



All the lesions were found to have more frequency of occurrence in males (69.8%), except OLP, which was more common in females. 36.8% patients of all (n=106) were males presenting with OSF while 2.8% of all patients were males presenting with OLP. **Table 3** shows the sex distribution of the cases according to the lesions.

**Table 3.** Sex distribution of various types of precancerous lesions

Serial No.	Type	Males		Females	
		No.	%	No.	%
1	Oral Submucous Fibrosis	39	36.8	20	18.9
2	Oral Leukoplakia	17	16.0	5	4.7
3	Oral Erythroplakia	7	6.6	3	2.8
4	Traumatic Dental Ulcers	8	7.6	0	0
5	Oral Lichen Planus	3	2.8	4	3.8
	Total	74	69.8	32	30.2

Tobacco chewing was the most commonly encountered addiction (24.5%) followed by addiction to betelnut chewing (17.9%). Of all the cases of OSF maximum had addiction to betelnut chewing (27.1 %) followed by addiction to tobacco chewing (20.3%). 45.5% cases of OL had a habit of tobacco chewing while 36.4% had a habit of smoking. In cases with OE, addiction to tobacco chewing, betelnut chewing and alcohol intake were encountered with same frequency (30%). 21.7% patients gave no history of addiction. Maximum cases of TDU and all cases of OLP gave no history of any addiction. The frequency of addiction to various products has been shown in **Table 4**.

Addiction → Lesion ↓	Tobacco		Betelnut		Paan		Smoking		Alcohol		None	
	No.	%	No.	%	No.	%	No.	%	No.	%	No.	%
OSF (n=59)	12	20.3	16	27.1	6	10.1	8	13.6	8	13.6	9	15.3
OL (n=22)	10	45.5	2	9.1	1	4.5	8	36.4	0	0	1	4.5

OE (n=10)	3	30	1	10	0	0	3	30	3	30	0	0
TDU (n=8)	1	12.5	0	0	0	0	1	12.5	0	0	6	75
OLP (n=7)	0	0	0	0	0	0	0	0	0	0	7	100
Total	26	24.5	19	17.9	7	6.6	20	18.9	11	10.4	23	21.7

41% of all the patients had an addiction for 1-5 years while 3.6% patients were addicted to some product for 21-25 years. The duration of addictions have been presented in Table 5.

**Table 5. Duration of addiction.**

Years	No. of Patients	Frequency
1-5	34	41
6-10	29	35
11-15	10	12
16-20	7	8.4
21-25	3	3.6
Total	83	100

#### IV. Discussion

In our study OSF (55.7%) was the most commonly encountered precancerous lesion of oral cavity, and OLP (6.6%) the least common. According to a study by Cox and Walker<sup>15</sup>, OSF has become an Indian epidemic with an estimation of 2.5 million patients all over the country suffering from the disease. The prevalence rose from 0.16% in 1967 to 3.2% in 1994<sup>16</sup>. The incidence of OL is 28.9 per 1000 persons, that of TDU is 2.1 per 1000, for OLP it is 1 per 1000 people and OE presents in 0.1-0.6 of every 100,000 persons annually<sup>17</sup>.

Analysing the results from our study, we came up to the conclusion that 32% patients were in the age group of 45-55 years, the youngest being a 19 year old male diagnosed with OSF and eldest age of presentation being 85 years. Sirsat and Pindborg<sup>18</sup> encountered a wide range of presentation of cases of OSF with respect to age, with majority being 30-50 years of age. Pindborg (1965) reported in his comparative study of Bombay and Lucknow that the youngest patient was of 32 years and the oldest of 72 years age<sup>19</sup>.

OL occurs mainly in persons over 40 years of age<sup>17,20</sup>.

OE has a mean age of diagnosis as 50-69 years<sup>21</sup>.

OLP is commonly diagnosed in middle aged males<sup>22</sup>.

Out of the total 106 cases, 74 cases (69.8%) were males and 32 cases (30.2%) were females with male to female ratio as 2.18:1.

Sharan<sup>23</sup> and Wahi et al<sup>24</sup>, in their studies of OSF found the male to female ratio as 2:1. Pindborg et al<sup>19</sup> had a female preponderance in their study with male to female ratio as 3:8. Dayal et al<sup>25</sup> obtained male preponderance with the ratio as 4.2:1.

Out of 7 cases of OLP, 4 females and 3 males were present. LP has a strong female predilection and the same goes with our study<sup>17,22</sup>.

Tobacco chewing (24.5%) was the most common addiction encountered of the total 106 patients, followed by smoking (18.9%), betelnut chewing (17.9%), alcohol intake (10.4%) and intake of paan (6.6%). 21.7% patients gave no history of any addiction.

Out of 59 patients, 16 (27.1%) had a habit of chewing betelnut. Pindborg and co-workers<sup>26</sup>, in their case control study conducted in Gumla, Jharkhand, found betelnut chewing as the most important etiological factor in OSF.

Tobacco chewing was the most common form of addiction in patients with OL (45.5%) followed by smoking (36.4%) in our study. Bancozy<sup>27</sup> and Bouquot and Gorlin<sup>17</sup>, in their study, stated that OL is most common in tobacco smokers followed by tobacco chewers, in whom malignant transformation rate is comparatively less.

In cases of OE, tobacco chewing, smoking and alcohol intake were equally encountered (30%). Prout et al<sup>28</sup>, in their study, reported a prevalence rate of 17 per 1000 in US adult tobacco users.

No history of addiction was found in cases of OLP, as it is an autoimmune condition with exact etiology unknown<sup>29</sup>.

#### V. Conclusion

OSF is the most common precancerous lesion encountered in oral cavity, followed by OL. Maximum cases belonged to the age group of 45-55 years. The male to female ratio was found to be 2.18:1 while OLP was more in females. In maximum cases oral hygiene was poor upon examination. In cases of OSF, betelnut chewing is the most common form of addiction encountered (27.1%) followed by tobacco chewing (20.3%). The most common form of addiction in cases of OL was tobacco chewing (45.5%) followed by smoking (36.4%). Tobacco chewing, alcohol intake and smoking were equally common in cases of OE (30%). No history

of addiction was reported in cases of OLP. Maximum cases had an addiction for 1-5 years (41%). Thus early detection and management of these precancerous lesions can prevent development of full blown carcinoma.

## References

- [1] Vlková B, Stanko P, Minárik G, Tóthová L, Szemes T, Baňasová L, Novotňáková D, Hodosy J, Celec P. Salivary markers of oxidative stress in patients with oral premalignant lesions. *Arch Oral Biol*. 2012;57:1651–1656. [[PubMed](#)]
- [2] Steele TO, Meyers A. Early detection of premalignant lesions and oral cancer. *Otolaryngol Clin North Am*. 2011;44:221–229, vii. [[PubMed](#)]
- [3] Phookan J, Saikia KP. A clinicopathological study of the pre-malignant conditions of oral cavity. *Indian J Otolaryngol Head Neck Surg*. 1998;50:246–249. [[PMC free article](#)] [[PubMed](#)]
- [4] van der Waal I. Potentially malignant disorders of the oral and oropharyngeal mucosa; terminology, classification and present concepts of management. *Oral Oncol*. 2009;45:317–323. [[PubMed](#)]
- [5] Bánóczy J, Gintner Z, Dombi C. Tobacco use and oral leukoplakia. *J Dent Educ*. 2001;65:322–327. [[PubMed](#)]
- [6] Greer RO. Pathology of malignant and premalignant oral epithelial lesions. *Otolaryngol Clin North Am*. 2006;39:249–275, v. [[PubMed](#)]
- [7] Warnakulasuriya S, Johnson NW, van der Waal I. Nomenclature and classification of potentially malignant disorders of the oral mucosa. *J Oral Pathol Med*. 2007;36:575–580. [[PubMed](#)]
- [8] van der Waal I. Potentially malignant disorders of the oral and oropharyngeal mucosa; present concepts of management. *Oral Oncol*. 2010;46:423–425. [[PubMed](#)]
- [9] Batsakis JG, Suarez P, el-Naggar AK. Proliferative verrucous leukoplakia and its related lesions. *Oral Oncol*. 1999;35:354–359. [[PubMed](#)]
- [10] Reichart PA, Philipsen HP. Oral erythroplakia--a review. *Oral Oncol*. 2005;41:551–561. [[PubMed](#)]
- [11] Ismail SB, Kumar SK, Zain RB. Oral lichen planus and lichenoid reactions: etiopathogenesis, diagnosis, management and malignant transformation. *J Oral Sci*. 2007;49:89–106. [[PubMed](#)]
- [12] Farhi D, Dupin N. Pathophysiology, etiologic factors, and clinical management of oral lichen planus, part I: facts and controversies. *Clin Dermatol*. 2010;28:100–108. [[PubMed](#)]
- [13] Edwards PC, Kelsch R. Oral lichen planus: clinical presentation and management. *J Can Dent Assoc*. 2002;68:494–499. [[PubMed](#)]
- [14] Arakeri G, Brennan PA. Oral submucous fibrosis: an overview of the aetiology, pathogenesis, classification, and principles of management. *Br J Oral Maxillofac Surg*. 2013;51:587–593. [[PubMed](#)]
- [15] Cox SC, Walker DM (1996) Oral submucous fibrosis. A review. *Aust Dent J* 41:294-299
- [16] Gupta PC, Mehta FS, Daftary DK et al (1980) Incidence rates of oral cancer and natural history of oral precancerous lesions in a 10-year follow-up study of Indian villagers. *Community Dent Oral Epidemiol* 8:287-333
- [17] Bouquot JE, Gorlin RJ (1987) Leukoplakia, lichen planus, and other oral keratosis in 23,616 white Americans over 35 years of age. In: Sober AJ (ed) 1987 year book of dermatology. Year Book Med Publication, Chicago, pp 254-255
- [18] Sirsat SM, Pindborg JJ (1967) Subepithelial changes in oral submucous fibrosis. *Acta Pathol Microbiol Scand*70(2):161-173
- [19] Pindborg JJ, Reichart PA, Smith CJ, Van der Waal I (1997) World Health Organization International Histological Classification of Tumours. Histological typing of cancer and precancer of the oral mucosa. Springer, Berlin
- [20] Schwimmer E (1877) Die idiopathischen Schleimhautplaques der Mundhohle (Leukoplakia buccalis). *Arch Dermatol Syph* 9:570-611
- [21] Lumerman H, Freedman P, Kerpel S (1995) Oral epithelial dysplasia and the development of invasive squamous cell carcinoma. *Oral Surg Oral Med Oral Pathol Oral Radiol Endod* 79(3):321-329
- [22] Bouquot JE, Gundlach KKH (1986) Oral exophytic lesions in 23,616 white Americans over 35 years of age. *Oral Surg Oral Med Oral Pathol* 62:284-291
- [23] Sharan J (1959) Histopathological observations on cases of submucous fibrosis of the oral cavity. *Indian J Pathol Microbiol* 2:150
- [24] Wahi PN, Arora S, Srivastava MC, Kehar U, Bodhke RR (1961) Leukoplakia of oral cavity. *Indian J Pathol Bacteriol* 4:189-202
- [25] Dayal PK, Joshi HN, dayal JP (1988) Concomitant occurrence of oral sub-mucous fibrosis, pemphigus and squamous cell carcinoma, *Indian J Pathol Microbiol* 31:334-337
- [26] Bhonsle RB, Murti PR, Daftary DK, Guopta PC, Mehta FS, Sinor PN, Irani RR., Pindborg JJ (1987) Regional variations in oral submucous fibrosis in India. *Community Dent Oral Epidemiol* 15(4):225-229
- [27] Banoczy J (1982) Oral leukoplakia. Martinus Nijhoff Publishers, The Hague
- [28] Prout MN, Sidari JN, Witzburg RA et al (1997) Head and neck cancer screening among 4,611 tobacco users older than 40 years. *Otolaryngol Head Neck Surg* 116:201-208
- [29] Vincent SD, Fotos PG, Baker KA, Williams TP (1990) Oral lichen planus: the clinical, historical and therapeutic features of 100 cases. *Oral Surg Oral Med Oral Pathol* 70:165-171

Dr. R.K.Choudhary, " A Clinical Study of Precancerous Lesions of Oral Cavity In Patients Attending A Tertiary Care Centre Of Jharkhand."IOSR Journal of Dental and Medical Sciences (IOSR-JDMS), vol. 17, no. 3, 2018, pp 69-73.