

Endodontic Management of Radix Entomolaris: A Case Series

Prof. Dr. Pardeep Mahajan, Pratima Sharma, Harsimran Kaur,

Harshita Wadhwa, Divya Pipat, Pallvi Dhand

Genesis institute of dental sciences and research, Ferozepur

Abstract: The Root Canal Treatment Of A Mandibular Molar With Aberrant Canal Configuration Can Be Diagnostically And Technically Challenging. Usually Mandibular Molars Have Two Roots With Three Canals But In Few Teeth, The Number Of Roots And Canals May Vary. Radix Entomolaris Is One Of The Anatomical Variant Found In A Permanent Mandibular Molar Was First Described By Carabelli. It Is Characterized By The Presence Of Additional Or Extra Third Root, Which May Be Typically Found Distolingually. Achieving The Endodontic Success In The Presence Of An Re Requires Knowledge About Its Prevalence, Diagnosis, Morphology, Canal Configuration, And Clinical Approach. This Report Discusses Endodontic Treatment Of Two Different Mandibular Molars Having Radix Entomolaris (Re).

Date of Submission: 24-02-2018

Date of acceptance: 12-03-2018

I. Introduction

Radix Entomolaris (Re) Is One Of The Anatomical Variant Found In A Permanent Mandibular Molar And Was First Described By Carabelli.¹ It Is Characterized By The Presence Of An Additional Or Extra Third Root, Which Is Typically Found Disto-Lingually. Radix Entomolaris Can Be Found In The First, Second, And Third Mandibular Molars.^{2,3}

Radix Entomolaris Has An Extra Root That Is Typically Smaller Than The Distobuccal Root And Is Usually Curved. The Relevant Literature Revealed An Incidence Of <5% In Caucasian, African, Eurasian And Indian Populations, Whereas In Those With Mongoloid Traits, Such As Chinese, Eskimo And Native American Populations, The Re Occurs With A Frequency Of 5% And Even Up To 40%.⁴⁻⁶

This Present Case Series Discusses The Successful Endodontic Management Of Two Cases Of Radix Entomolaris In Relation To Mandibular First Molar.

Case Report 1

A 34 Year Old Woman Reported To The Department Of Conservative Dentistry And Endodontics, Genesis Institute Of Dental Sciences And Research, Ferozepur, With Difficulty In Chewing In Right Lower Back Region Of Mouth. There Was No Relevant History Of Spontaneous Pain. Patient Medical History Was Non-Contributory.

Intraoral Examination Revealed Mesio-Occlusal Caries In Tooth #46. The Tooth Was Slightly Tender On Percussion And Showed No Response To Electric Pulp Test. Periapical Radiograph Revealed Mesio-Occlusal Caries With Pulpal Involvement. On Keen Observation, There Appeared To Be An Additional Root Outline Seen Distolingually. Radiographs Were Taken In Three Different Angulations Keeping In Mind The SLOB Rule To Confirm Presence Of An Extra Root Distolingually.

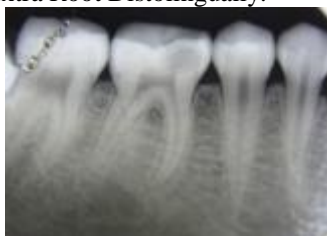

Fig. 1 Preoperative IOPA showing caries with pulpal involvement #46

After Taking Patients Consent Root Canal Treatment Was Started. 2% Lidocaine With 1:100,000 Adrenaline Was Administered And The Tooth Was Isolated Under Rubber Dam. Access Was Made With Endo Access Bur No.1 (Dentsply Switzerland).

Extension And De-Roofing Of The Pulp Chamber Were Done To Provide Straight Line Access To The Canals. Three Canals Were Located Immediately But The Dentinal Map Seemed To Be Slightly Extending In A Distolingual Direction. The Access Cavity Was Modified From A Triangular Outline To A Trapezoidal Outline.

Probing With A Dg-16 Explorer (Hu Friedy) Revealed An Extra Canal In Distolingual Aspect Of The Floor Of Access Cavity.

The Root Canals Were Explored With Precurved K-File Iso Number 10 (Dentsply Maillefer, Ballaigues, Switzerland). Working Length Was Determined Using Apex Locator (Prope Pixi, Dentsply) And Confirmed Using Radiographic Method .

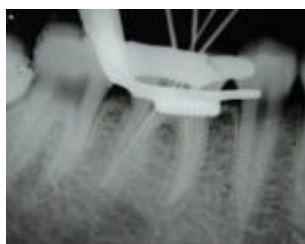


Fig. 2 Working length determination #46

The Root Canals Were Instrumented Using K Files With Step Back Technique (Dentsply Maillefer, Ballaigues, Switzerland) In All The Canals. Glyde (Dentsply Maillefer, Ballaigues, Switzerland) Was Used As A Lubricant. Canals Were Irrigated With 5ml Of 3% Sodium Hypochlorite (Deor, Azure Laboratories, Kochi, India) Followed By 5ml Of Saline After Each Instrument. Final Irrigation Was Done Using 2% Chlorhexidine (Rc-Chlor, Deor, Azure Laboratories, Kochi, India).

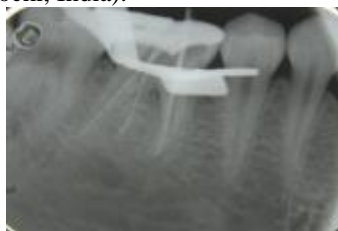


Fig. 3 Master cone placed to working length

Obturation Was Done Using Ah Plus Sealer (Dentsply, Maillefer, Ballaigues, Switzerland) And Corresponding 2% Gutta Percha Points Using Lateral Condensation Technique. Access Preparation Was Then Restored With Composite Resin.

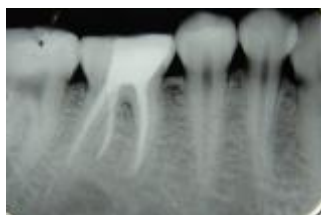


Fig.4 obturation was done using lateral consensation technique #46

Case Report 2

A 25 Year Old Male Reported To The Department Of Conservative Dentistry And Endodontics, Firozpur, With Complaint Of Pain In The Right Lower Back Teeth. The Patient Reported With A History Of Throbbing Pain For The Past One Month, Which Increased In Intensity On Food Intake And Was Relieved On Taking Medication. On Examination, The Right & Left Mandibular First Molar Displayed Deep Dental Carious Lesion With No Tenderness On Percussion. Thermal And Electrical Pulp Testing Of The Tooth Elicited A Negative Response. The Pre-Treatment Radiograph Showed Widening Of The Periodontal Ligament Space And An Additional Root Between The Mesial And Distal Roots

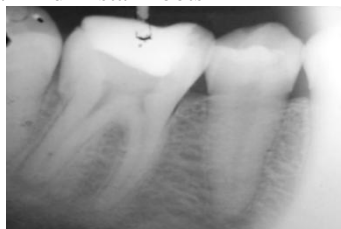

Fig. 5 preoperative IOPA showing a restoration extending towards pulp and an extra root outline seen behind the distal root

A Diagnosis Of Pulpal Necrosis Associated With Chronic Periapical Periodontitis With Respect To Right First Mandibular Molar Was Made According To Aae Recommended Diagnostic Terminology As Confirmed By Radiograph. In The First Visit Right Mandibular First Molar Was Anesthetized Using 2 Ml Of 2% Lidocaine Containing 1:100,000 Epinephrine (Lox 2%, Neon Laboratories Ltd., Mumbai, India) And Isolated Under Rubber Dam. The Pulp Chamber Was Accessed And Two Mesial Orifices And Two Distal Orifices Were Located. To Obtain A Straight Line Access The Preparation Was Modified To A Trapezoidal Form. Working Length Was Determined Using Radiographic Method.

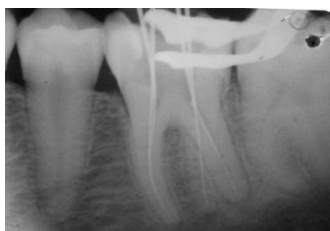

Fig. 6 working length determined #46

The Root Canals Were Instrumented Using The Protaper Rotary Files (Dentsply Maillefer, Ballaigues, Switzerland) Using Crown Down Technique In All The Canals. Irrigation Was Done Using 5ml Of 3% Sodium Hypochlorite (Deor, Azure Laboratories, Kochi, India) Followed By 5ml Of Normal Saline. 2% Chlorhexidine (Rc-Chlor, Deor, Azure Laboratories, Kochi, India) Was Used As Final Irrigant.

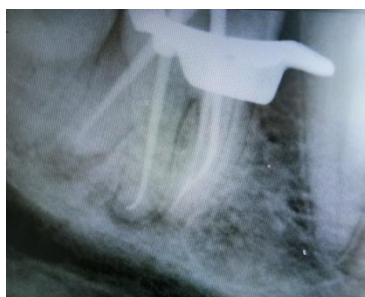

Fig.8 master cone placed to working length

Obturation Was Done Using Ah Plus Sealer (Dentsply,Maillefer, Ballaigues, Switzerland) And Corresponding Protaper Gutta Percha Points With Single Cone Obturation Technique. Access Preparation Was Then Restored With Composite Resin.

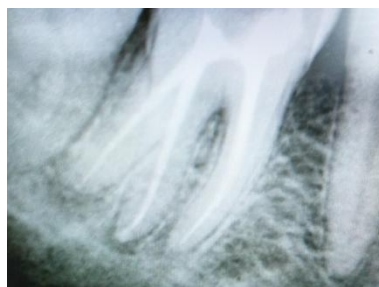


Fig.8 obturation done #46

II. Discussion

The Presence Of A Third Root In Mandibular First Molars Has Clinical Implications In Endodontic Treatment.

The Re Is Located Distolingually, With Its Coronal Third Completely Or Partially Fixed To The Distal Root. The Dimensions Of The Re Can Vary From A Short Conical Extension To A 'Mature' Root With Normal Length And Root Canal. In Most Cases The Pulpal Extension Is Radiographically Visible.⁷

The Etiology Behind The Formation Of The Re Is Still Unclear. In Dysmorphic, Supernumerary Roots, Its Formation Could Be Related To External Factors During Odontogenesis, Or To Penetrance Of An Atavistic Gene Or Polygenetic System (Atavism Is The Reappearance Of A Trait After Several Generations Of Absence).⁷

Carlsen And Alexandersen Describes Four Different Types Of Re According To The Location Of The Cervical Part Of The Re: Types A, B, C And Ac.⁸ Types A And B Refer To A Distally Located Cervical Part Of The Re With Two Normal And One Normal Distal Root Components, Respectively. Type C Refers To A Mesially Located Cervical Part, While Type Ac Refers To A Central Location, Between The Distal And Mesial Root Components. This Classification Allows For The Identification Of Separate And Nonseparate Re.^{7,8}

It Is Important To Make A Thorough Radiographic Examination In Radix Entomolaris. The Exposure Of The Involved Tooth From Three Different Horizontal Projections, The Standard Buccal-To-Lingual Projection, 20 Degree From The Mesial, And 20degree From The Distal Reveals The Basic Information Regarding The Anatomy Of The Tooth In Order To Perform Endodontic Treatment.⁹ However, Using The Buccal Object Rule With Two Radiographs With Different Horizontal Angulations May Suffice To Determine The Position Of A Lingual Root.⁹

Schafer Et Al. 2009 , Showed That The Occurrence Of Three-Rooted Mandibular First Molars In A German Population Was 1.35% Of All Patients And 0.68% Of All Teeth Examined, Respectively.¹⁰ In European Populations It Has Been Reported That A Separate Re Is Present In The Mandibular First Molar With A Maximum Frequency Of 3.4–4.2%. In African Populations (Bantu, Bushmen, Senegalese) A Maximum Of 3% Is Found. In Eurasian And Indian Populations The Frequency Is Less Than 5%. In Populations With Mongoloid Traits, Such As Chinese, Eskimo And American Indians, The Re Occurs With A Frequency Of 5% To More Than 40%.⁵

Based On Above Quoted Studies, The Clinical Recommendations Can Be Given That, Although Seldom With A Prevalence Of Less Than 2%, The Clinician Should Be Aware Of The Unusual Root Morphologies In Mandibular First Molars .

III. Conclusion

Clinicians Should Be Aware Of These Unusual Root Morphologies In The Mandibular First Molars In Caucasian People. The Initial Diagnosis Of A Radix Entomolaris Or Paramolaris Before Root Canal Treatment Is Important To Facilitate The Endodontic Procedure, And To Avoid 'Missed' Canals. Preoperative Periapical Radiographs Exposed At Two Different Horizontal Angles Are Required To Identify These Additional Roots.

Bibliography

- [1]. Carabelli G. Systematisches Handbuch Der Zahnheilkunde. 2nd Ed. Vienna: Braumullerund Seidel; 1844:114.
- [2]. Tu Mg, Huang Hl, Hsue Ss, Hsu Jt, Chen Sy, Jou Mj Et Al. Detection Of Permanent Three-Rooted Mandibular First Molar By Cone-Beam Computed Tomography Imaging In Taiwanese Individuals. J Endod 2009;35:503-7.
- [3]. Garg Ak, Tewari Rk, Kumar A, Hashmi Sh, Agrawal N, Mishra Sk. Prevalence Of Three-Rooted Mandibular Permanent First Molars Among The Indian Population. J Endod 2010;36:1302-6.
- [4]. Gulabivala K, Aung Th, Alavi A, Ng Y-L. Root And Canal Morphology Of Burmese Mandibular Molars. Int Endod J 2001;34:359–70.
- [5]. De Moor Rj, Deroose Ca, Calberson Fl The Radix Entomolaris In Mandibular First Molars: An Endodontic Challenge. Int Endod J 2004; 37: 789–99.
- [6]. Tu Mg, Tsai Cc, Jou Mj Et Al. Prevalence Of Three-Rooted Mandibular First Molars Among Taiwanese Individuals. J Endod 2007 ;33:1163–6.
- [7]. Calberson Fl, De Moor Rj, Deroose Ca. The Radix Entomolaris And Paramolaris: Clinical Approach In Endodontics. J Endod 2007;33:58–63.
- [8]. Carlsen O, Alexandersen V. Radix Entomolaris: Identification And Morphology. Scan J Dent Res 1990;98:163–73.
- [9]. Ingle Ji, Bakland Lf, Eds. Endodontics. 5th Ed. Hamilton, London, Uk: Bc Decker Inc; 2002:203–58.
- [10]. Sch" Afer E, Breuer D, Janzen S. The Prevalence Of Three Rooted Mandibular Permanent First Molars In A German Population. J Endod 2009; 35: 202–5.

Prof. Dr. Pardeep Mahajan” Endodontic Management Of Radix Entomolaris: A Case Series”IOSR Journal of Dental and Medical Sciences (IOSR-JDMS), vol. 17, no. 3, 2018, pp 06-09