

Monophasic Synovial Carcinoma of knee joint- A Case Report and Review of Literature

Dr S Tulasiram Yashaswi

Junior Resident of Orthopaedics, Yenepoya Medical College, Dr Deepak rai Professor of Orthopaedics, Yenepoya Medical College, Mangalore.

Date of Submission: 23-02-2018

Date of acceptance: 12-03-2018

I. Introduction

Synovial sarcoma was first reported in 1893¹ and named after its microscopic resemblance to normal synovium.² It is thought to originate from primitive mesenchymal cells that undergo differentiation to resemble synovial cells.^{2,3,4,5}

Synovial sarcomas usually occur in adolescents and young adults, with no gender or racial predilection.^{2,3,4} They typically affect the extremities (80%–95% of cases),⁴ arising from tendons, tendon sheets and bursal structures. It is important to note that they usually arise beyond the confines of the joint capsule. The single most commonly affected site is the knee.^{2,3,4,5,6}

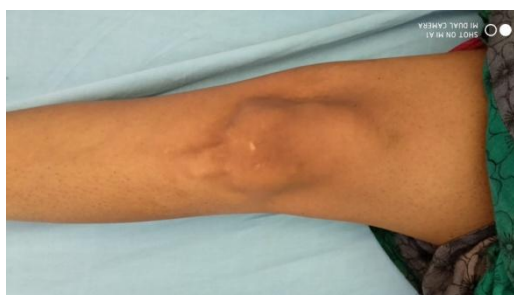Synovial sarcomas are frequently initially incorrectly diagnosed as benign processes such as myositis, synovitis, haematoma, tendinitis or bursitis,² resulting in the time to final diagnosis ranging from two to four years.⁴ It is therefore important to consider synovial sarcoma when a young adult patient presents with a calcified juxta-articular soft-tissue mass of insidious onset.⁵

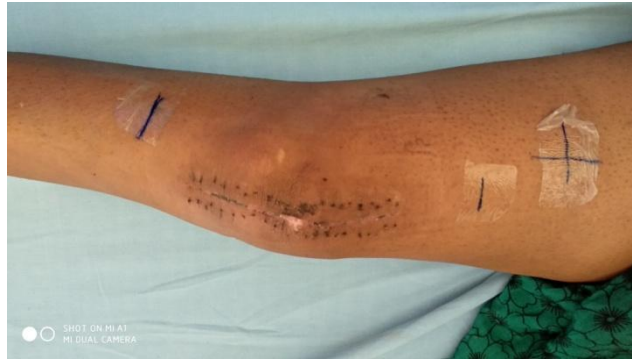II. Case Report

A 25yrs old female presented with two years history of tender, slow growing, juxta-articular right knee mass. Pain was associated with restriction on her knee range of motion since one year. After one year the pain increased. On examination, a palpable diffuse mass that was detected over antero-medial aspect of the knee. The mass was soft with some tenderness in the palpation and pisani sign was negative.

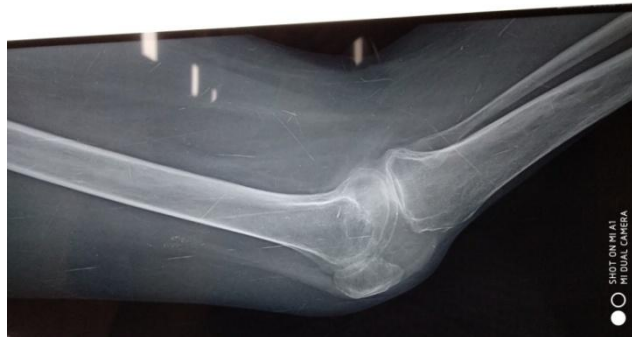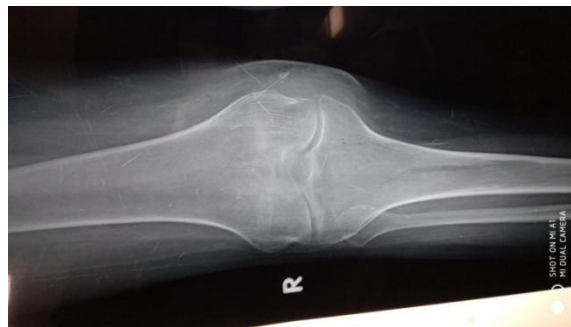Then patient planned for excisional biopsy of mass. Intra-operatively, there was grayish-white mass extending from medial joint space to intercondylar area. The mass had infiltrated extra-capsularly on the medial side of the joint. En-bloc excision of the tumour done and sent for HPE.

Histopathology studies revealed highly cellular tumour tissue made up of large groups, masses, sheets and islands of oval and spindle shaped cells having ovoid and slightly pleomorphic nuclei with few atypical mitotic figures. IHC revealed, cells were Bcl-2 positive suggestive of Monophasic synovial sarcoma of FNCLCC grade-2.

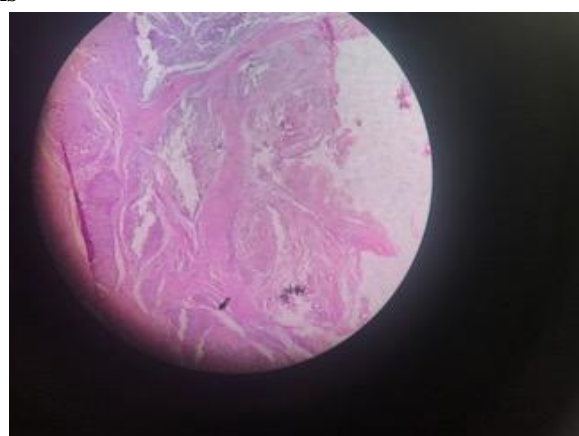
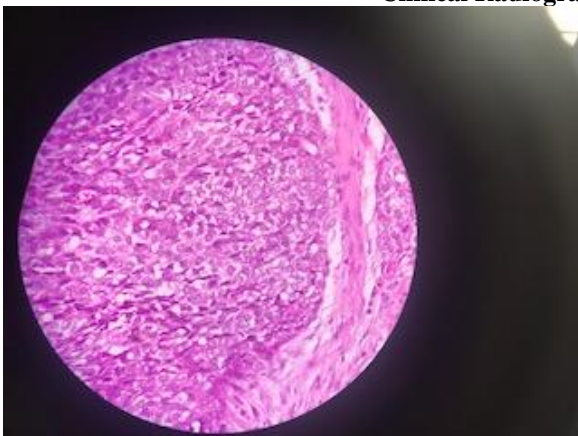


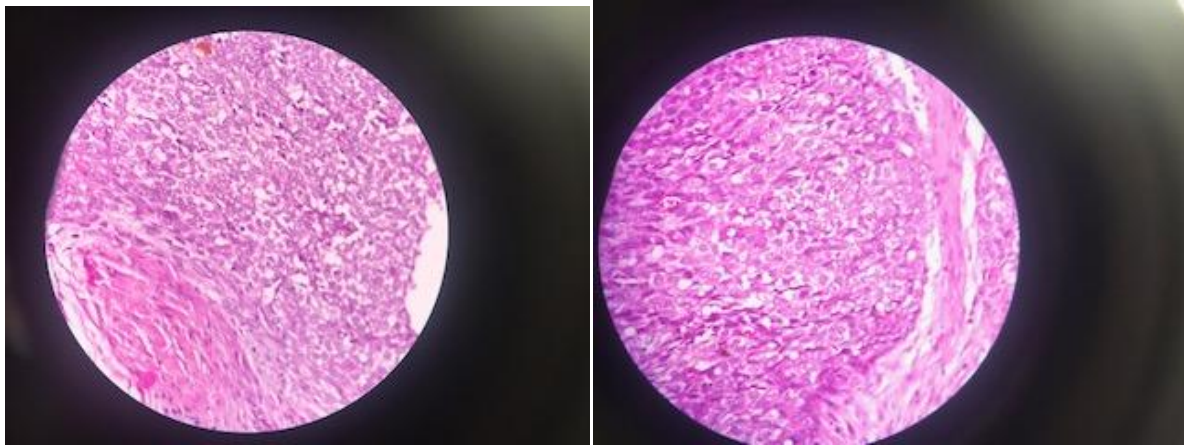


Clinical photographs



Clinical Radiographs





HISTO-PATHOLOGICAL SLIDES

LAB No : 3533/18
NAME : KOWSAR ABBILLAH HASSAN
REFERRED BY : Dr. DEEPAK K RAI MS, ORTHO, D. ORTHO

DATE OF REPORT : 01-02-18 AT 10:59 AM
AGE/SEX : 28 yrs /

HISTOPATHOLOGY REPORT

NATURE OF SPECIMEN :
Soft tissue biopsy from right knee.

GROSS FEATURES OF THE SPECIMEN :
Specimen consists of 2 pale brown masses measuring 3.2 cm in diameter each. Cut section of both shows homogenous pale brown and dark brown areas.

MICROSCOPY :
Multiple sections studied show a highly cellular tumour tissue made up of large groups, masses, sheets and islands of oval and spindle shaped cells having ovoid and slightly pleomorphic nuclei. Few atypical mitotic figures are seen. In few areas small groups of cells with epithelial like morphology are seen. Thick fibrovascular stroma is seen.

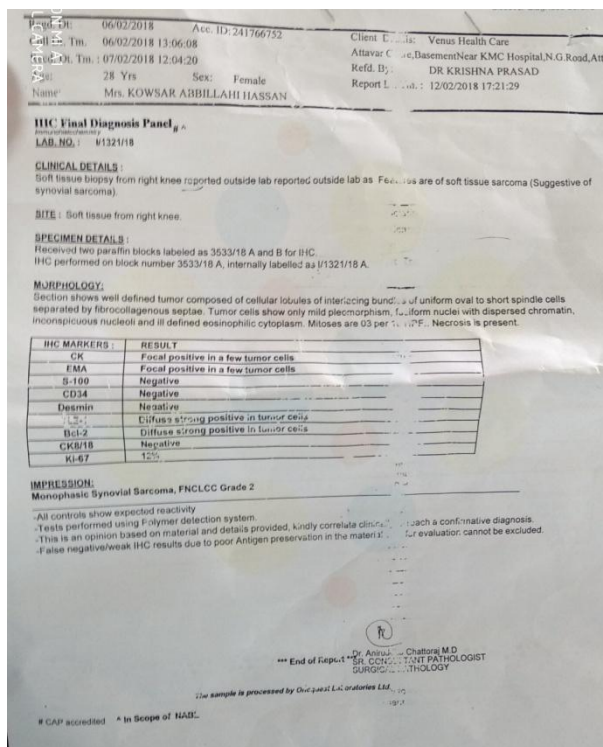
Features are of **SOFT TISSUE SARCOMA**.
(Suggestive of **SYNOVIAL SARCOMA**).

IMMUNOHISTOCHEMICAL MARKER STUDY of the tissue is indicated for further evaluation, typing and accurate subtyping.

*** End of Report ***

Page 1 of 1

Signature



HPE & IHC Reports

III. Discussion

Synovial sarcoma is a slow-growing, high-grade malignant neoplasm with extensive metastatic potential.^{4,5} It accounts for approximately 10% of all soft-tissue sarcomas and occurs predominantly in adolescents and young adults between the ages of 15 and 40 years.^{2,3,4,5}

The extremities are affected in 95% of cases, and the lower limb in 70% of the former.⁶ The neoplasms usually occur in close proximity to large joints of the extremities, predominantly around the knee,^{2,3,4,5,6,7} followed by the ankle, elbow and shoulder.² They rarely occur in the head, neck, thorax and abdomen.³

Synovial sarcomas are usually found in close association with tendon sheets, bursae and joint capsules, but joint involvement is rare.² When intra-articular involvement does occur, it usually extends from an extra-articular site into the joint space.^{4,5}

Patients most commonly present with insidious onset of a peri-articular, palpable, deep-seated swelling or mass that is commonly associated with pain or tenderness.^{2,3,4,5,6,7} The duration of symptoms varies from weeks to decades, with an average duration of 2–4 years.^{2,3,4}

Metastases are present in a quarter of patients at initial diagnosis,⁵ and mainly affect the lungs^{2,3,4,5} and, to a lesser extent, lymph nodes, bone and rarely the liver or brain.³

Conventional radiographs may appear normal in approximately 50% of cases.⁴ Typical radiographic features include a juxta-articular soft-tissue mass within 5 cm of the joint and amorphous calcifications in 20%–30% of cases, which are often eccentric or peripheral.⁴ An associated periosteal reaction is present in 15%–20% of cases.^{2,3,4,5,6,7}

Computed tomography (CT) scanning shows a soft-tissue mass with or without calcifications and bony involvement.^{2,3,4,5,6,7} MRI is reserved for local staging of the extent of the disease. Characteristic changes include a heterogeneous, multi-lobulated soft-tissue mass with a signal intensity similar to or slightly higher than that of muscle on T1W, and a mixed high, intermediate, low signal on T2W that has been described as the triple sign. Fluid-fluid levels are seen in 25% of cases.^{2,3,4,5,6}

Fluorodeoxyglucose positron emission tomography (FDG-PET) is helpful in differentiating recurrent tumour from post-therapeutic changes, and is valuable in determining prognosis.^{3,7}

It is important to note that imaging appearances are largely non-specific; biopsy is always necessary for the final diagnosis. At our institution, this is the domain of the clinician and not the radiologist. The current treatment of choice is surgery with or without radiotherapy. The use of chemotherapy is controversial.^{3,5}

IV. Conclusion

Synovial sarcoma represents approximately 10% of all soft-tissue sarcomas and must be considered in addition to other sarcomas when adolescents or young adults present with insidious onset of a calcified juxta-articular mass, especially around the knee.

References

- [1] Craig RM, Pugh DG, Soule EH. The roentgenologic manifestations of synovial sarcoma. *Radiology*. 1955;65(6):837. <http://dx.doi.org/10.1148/65.6.837>
- [2] Siegel HJ, Sessions W, Casillas MA, Said-Al-Naief N, Lander PH, Lopez-Ben R. Synovial sarcoma: Clinicopathologic features, treatment and prognosis. *Orthopedics*. 2007;30(12):1020–1025.
- [3] Bakri A, Shinagare AB, Krajewski KM, et al. Synovial sarcoma: Imaging features of common and uncommon primary sites, metastatic patterns and treatment response. *AJR*. 2012;199(2):W208–W215. <http://dx.doi.org/10.2214/AJR.11.8039>
- [4] Murphey MD, Gibson MS, Jennings BT, Crespo-Rodriguez AM, Fanburg-Smith J, Gajewski DA. Imaging of synovial sarcoma with radiologic-pathologic correlation. *Radiographics*. 2006;26(5):1543–1565.
- [5] Roberts CC. STATdx Premier. Synovial sarcoma. Salt Lake City: Amirsys; 2005–2014. [cited 10–30 May 2014]. Available from: <http://my.statdx.com>
- [6] O'Sullivan PJ, Harris AC, Munk PL. Radiological features of synovial cell sarcoma. *Br J Radiol*. 2008;81(964):346–356. <http://dx.doi.org/10.1259/bjr/28335824>
- [7] Dähnert W. *Radiology Review manual*. 6th ed. Philadelphia: Lippincott Williams & Wilkins; 2007; p. 166–167.

Dr S Tulasiram Yashaswi "Monophasic Synovial Carcinoma of knee joint- A Case Report and Review of Literature." *IOSR Journal of Dental and Medical Sciences (IOSR-JDMS)*, vol. 17, no. 3, 2018, pp 13-17.