

## Morphometric Study of Foramen Ovale in Human Skull in Population of Bihar

Binod Kumar<sup>1</sup>, Rajiv Ranjan Sinha<sup>1</sup>, Sanjay Kumar<sup>2</sup>, Md. Jawed Akhtar<sup>3</sup>, Ruchi Ratnesh<sup>2</sup>, Avanish Kumar<sup>4</sup>, Jyoti P Kulkarni<sup>4</sup>, Vinod Kumar<sup>5</sup>

<sup>1</sup>.Associate Professor, Department of Anatomy, Indira Gandhi Institute of Medical Sciences Patna, Bihar

<sup>2</sup>.Tutor, Department of Anatomy, Indira Gandhi Institute of Medical Sciences Patna, Bihar

<sup>3</sup>.Assistant Professor, Department of Anatomy, Indira Gandhi Institute of Medical Sciences Patna, Bihar

<sup>4</sup>.Additional Professor, Department of Anatomy, Indira Gandhi Institute of Medical Sciences Patna, Bihar

<sup>5</sup>. Professor, Department of Anatomy, Indira Gandhi Institute of Medical Sciences Patna, Bihar

Corresponding author: Rajiv Ranjan Sinha

### Abstract

**Introduction:** The foramen ovale is located in the middle cranial fossa in the greater wing of sphenoid through which passes the many structures. It is situated at the transition zone between extracranial and intracranial structures. Therefore the foramen ovale is used in various surgical and diagnostic procedures.

**Objectives:** The objective of this study is to determine the length and width of foramen ovale and also the shape of foramen ovale.

**Material and methods:** The present study was carried out on 80 foramen ovale using 40 adult human skulls collected from department of Anatomy and Forensic Medicine at IGIMS, Patna, Bihar and also from other medical colleges of Bihar. Length and width of foramen ovale was measured. Shape of foramen ovale was determined.

**Results:** The mean length of foramen on right side was  $6.86 \pm 1.26$  mm and on left side was  $6.84 \pm 1.3$  mm. The mean width of foramen ovale on right was  $3.53 \pm 0.59$  mm and on left side was  $3.51 \pm 0.58$  mm. The shape of foramen ovale was oval in 60%, almond shaped in 28.75%, round in 10% and D-shaped in 1.25% of foramen ovale.

**Conclusion:** Morphometric variations of foramen ovale could be explained by developmental region. The foramen ovale has various anatomical, clinical and surgical importance.

**Keywords:** foramen ovale, trigeminal neuralgia, skull, morphometry

Date of Submission: 05-03-2018

Date of acceptance: 19-03-2018

### I. Introduction

The foramen ovale is present in the greater wing of sphenoid bone and it is the one of the several cranial foramina in the sphenoid bone. Structures passing through foramen ovale are mandibular nerve, accessory meningeal artery, lesser petrosal nerve and emissary vein [1, 2]. The foramen ovale is located in middle cranial fossa in the infratemporal surface of greater wing of sphenoid posterolateral to foramen rotundum and anteromedial to the foramen spinosum. The otic ganglia is located under the foramen ovale. It is located very close to the upper end of the posterior margin of the lateral pterygoid plate. The foramen ovale is a important foramen which connect the extracranial and intracranial structures. Therefore the foramen ovale is used in various diagnostic and surgical procedures [2,3]. The sphenoid bone developed from both intramembranous and endochondral ossification centres. The sphenoid bone consists of a body (basisphenoid), a pair of lesser wings (orbitosphenoid) and a pair of greater wings (alisphenoid). The first ossification centre appear for alisphenoids and most of it forms the greater wing of sphenoid by membranous ossification in which the mandibular nerve is surrounded by cartilage to form the foramen ovale [4]. The foramen ovale is seen in the 7<sup>th</sup> month of intrauterine life as a discrete ring shaped area and predominantly visible at 3 years after birth [5]. The foramen ovale connects the pterygoid plexus to the cavernous sinus through emissary vein [6]. The present study focuses on morphometric study such as length, width and shape of foramen ovale.

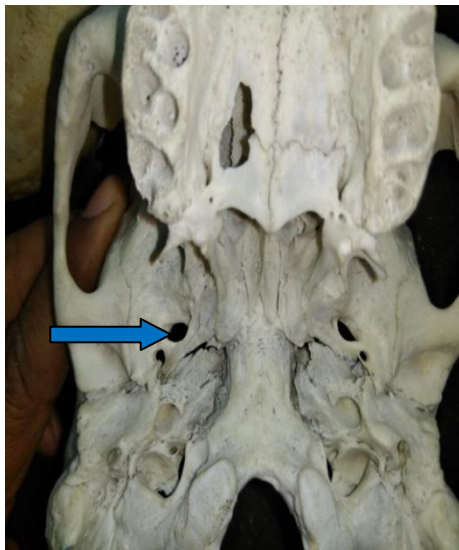
### II. Material And Methods

The present study was carried out on 80 foramen ovale using 40 adult human skulls, obtained from Department of Anatomy and Forensic Medicine at IGIMS, Patna and also from other medical colleges of Bihar. Skulls with damaged near the foramen ovale were excluded from this study. The maximum length (anteroposterior diameter) and width (transverse diameter) of foramen ovale were obtained by dividers and then

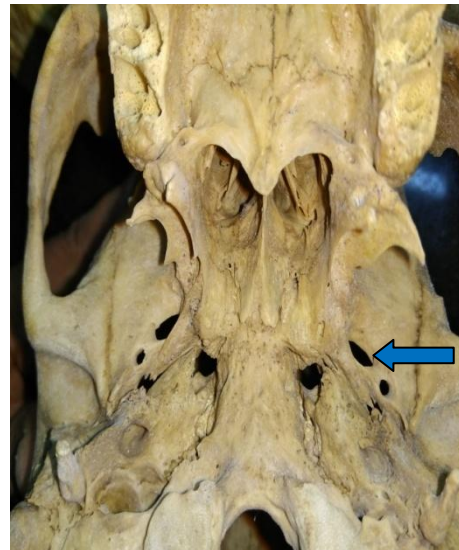
carefully transferred to a meter rule for the reading. All the measurement taken in millimetre. Any variations in the right and left side were calculated. The mean and standard deviation of the length and width were calculated. The variations in shape were also recorded.

## II. Results

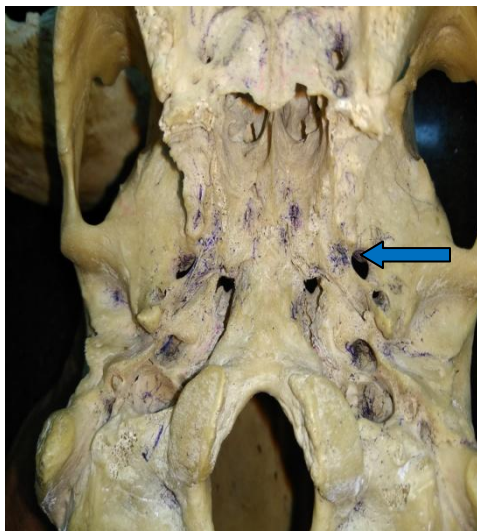
The present study was conducted on 80 foramen ovale using 40 adult human skulls. The maximum and minimum length of foramen ovale on the right and left was 10 mm, 4.4 mm and 9.8 mm, 3.4mm. respectively. The mean length of foramen ovale on right was  $6.86 \pm 1.26$  mm and on the left side was  $6.84 \pm 1.3$  mm. The maximum and minimum width of foramen ovale on the right and left side was 5 mm, 2.5 mm and 4.9 mm, 2.7 mm respectively. The mean width of foramen ovale on right was  $3.53 \pm 0.59$  mm and on left side was  $3.51 \pm 0.58$  mm. The shape of foramen ovale was oval in 60%, almond shaped in 28.75%, round in 10% of foramen ovale and D-shaped in 1.25%.



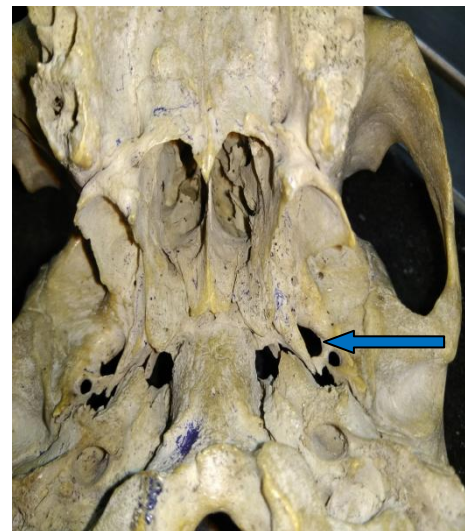
**Fig. 1. Oval shaped foramen ovale on left side**



**Fig. 2. Almond shaped foramen ovale on right side**



**Fig. 3. Round shaped foramen ovale on right side**



**Fig. 4. D shaped foramen ovale on right side**

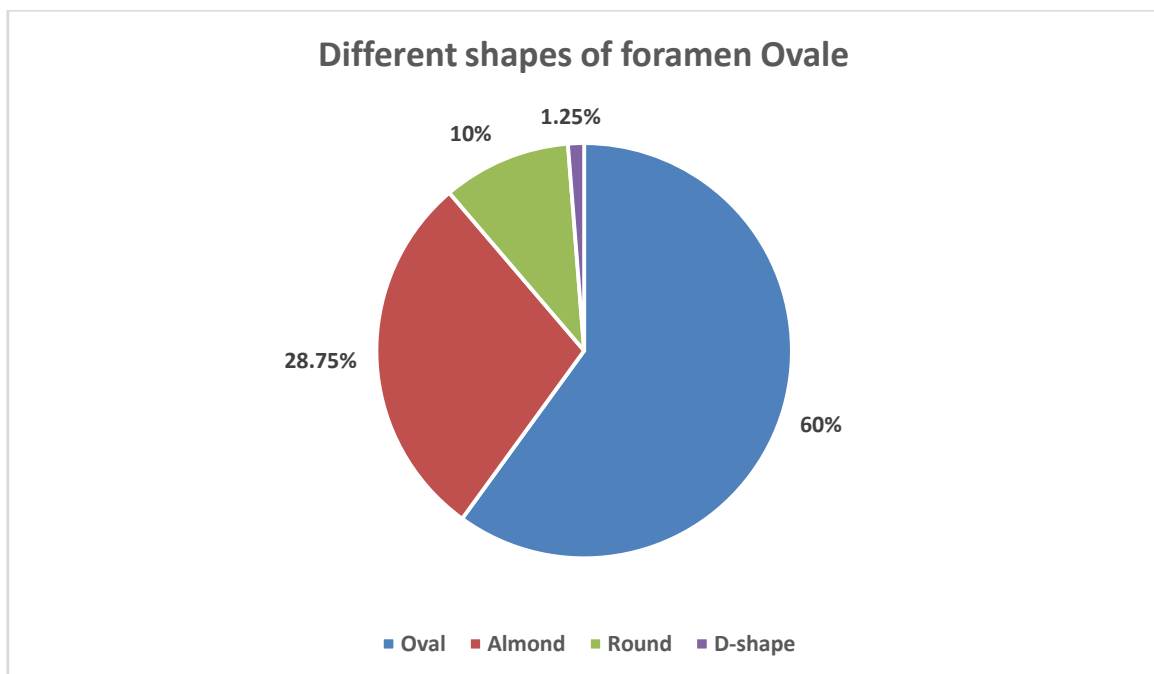
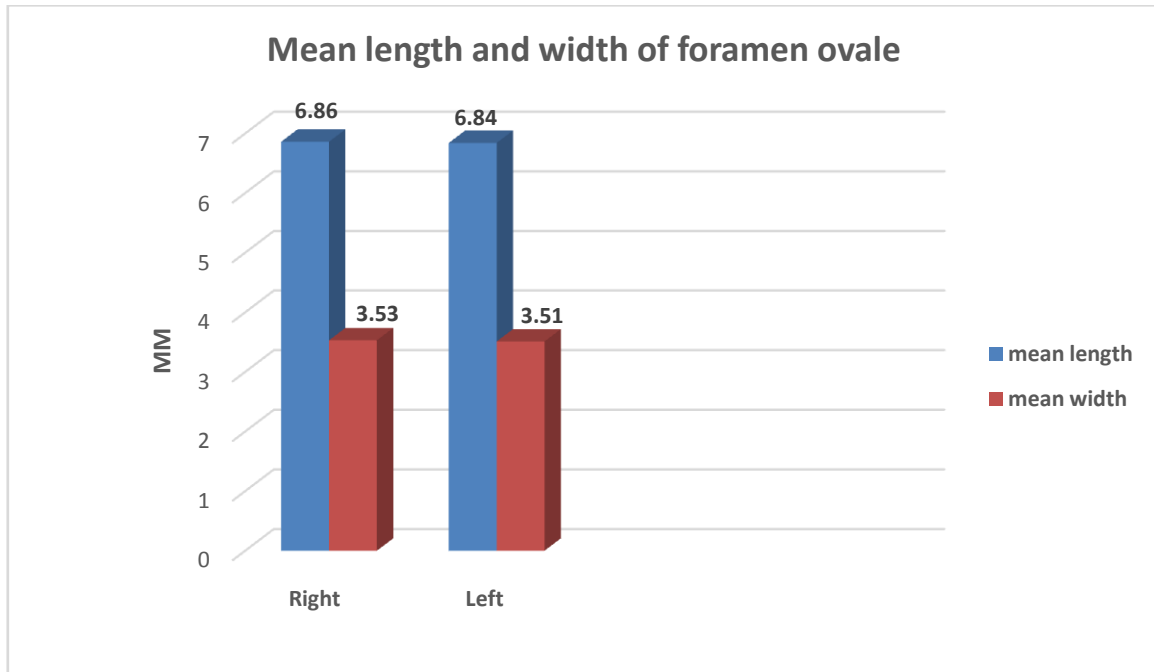
**Table 1. Length and width of foramen Ovale**

	Length	Length	Width	Width
	Right (mm)	Left (mm)	Right (mm)	Left (mm)
Maximum	10	9.8	5	4.9
Minimum	4.4	3.4	2.5	2.7
Mean	6.86	6.84	3.53	3.51

<b>Standard deviation</b>	1.26	1.3	0.59	0.58
---------------------------	------	-----	------	------

**Table 2.** Shape of foramen Ovale

Shape	Right ( n=40)	Left (n=40)	Total (n=80)
Oval	23 (57.5%)	25 (62.5%)	48 (60%)
Almond	12 (30%)	11 (27.5%)	23 (28.75%)
Round	4 (10%)	4 (10%)	8 (10%)
D-shape	1 (2.5%)	00	1 (1.25%)



### III. Discussion

The foramen ovale is one of the important foramina present at the transition zone between the extracranial and intracranial structures, so it is used for various diagnostic as well as surgical procedures. Therefore, it is essential to know about the size and shape of foramen ovale for surgeons. In the present study, the mean length of foramen ovale on the right and left side was 6.86 mm  $\pm$  1.26 mm and 6.84 mm  $\pm$  1.3 mm respectively. This study was in agreement with the study done by Biswabina Ray et al on 70 foramen ovale in

35 dry adult skulls. In their study the mean length of foramen ovale was  $7.46 \pm 1.41$  mm on the right side and  $7.01 \pm 1.41$  mm on left side [7]. In this study the maximum and minimum length of foramen ovale on the right and left side was 10 mm, 4.4mm and 9.8 mm, 3.4 mm respectively. This value falls in agreement with the value obtained by Arun in Nepal, in which the maximum length of foramen ovale was 9.8 mm and minimum length was 2.9 mm [8]. In present study, the mean value of width of right and left foramen ovale was  $3.53 \pm 0.59$  mm and  $3.51 \pm 0.58$  mm respectively. Maximum width on right side was 5 mm and on left side was 4.9 mm, while the minimum width on right side was 2.5 mm and on left side was 2.7 mm. This results were correlating with Biswabina Ray et al, they reported the mean width of right and left foramen ovale was  $3.21 \pm 1.02$  mm and  $3.29 \pm 0.85$  mm respectively, maximum width of foramen ovale was 5 mm on both right and left side, while minimum width was 1 mm on right side and 2.2 mm on left side. In Lang J study the average width was 3.7 mm [9]. In this study, the shape of foramen ovale was oval shaped in 60% , followed by almond and round shaped, the incidence of which were 28.75% and 10% respectively. Least common shape was D-shaped which was 1.25%. This results are in agreement with the study done by Biswabina ray at al the reported that oval shape in 61.4%, almond shaped in 34.3% and round in 2.9% and slit like in 1.4% of foramen ovale.

#### IV. Conclusion

The variations in the dimension and symmetry of foramen ovale has various anatomical, clinical and surgical importance. This study is significance for the medical practitioners in case of trigeminal neuralgia, diagnostic detection of tumors.

#### References

- [1]. Kuta AJ, Laine FJ (1993) Imaging the sphenoid bone and basiocciput: anatomic considerations. *Semin Ultrasound CT MR*, 14: 146–159.
- [2]. Long J (1995) Skull base and related structures. *Atlas of clinical anatomy*. Shattauer, Stuttgart, New York.
- [3]. Williams PL, Bannister LH, Berry MM, Collin P, Dyson M, Dussek JE, Ferguson MWJ. *Gray's anatomy*. 38th ed. Churchill Livingstone.
- [4]. Ray B, Gupta N and Ghose S.
- [5]. Anatomic variations of foramen ovale. *Kathmandu University Medical Journal*. 2005;3: 64–68.
- [6]. Magi Murugan, Shaik Hussain Saheb. Morphometric and morphological study of foramen ovale. *Int J Anat Res* 2014, Vol 2(4):664-67.
- [7]. Yanagi S. Developmental studies on the foramen rotundum, foramen ovale and foramen spinosum of the human sphenoid bone. *Hokkaido Journal of Medical Science*. 1987;62(3):485-496.
- [8]. Bekov DB (1965) *Atlas venoznoi sistemy golovnogo mozga tscheloveka*. Medicina, Moskwa.
- [9]. Biswabina Ray, Nirupma Gupta, Supriya Ghose. Anatomic variations of foramen ovale. *Kathmandu University Medical Journal*. 2005;3(9):64-68.
- [10]. Ambica Wadhwa, Mamta Sharma and Paramjeet Kaur. Anatomical variations of foramen ovale – Clinical variations. *International Journal of Basic and Applied Medical Sciences*. 2012 Vol. 2 (3) September - December, pp. 21-24.
- [11]. Lang J, Maier R, Schafhauser O. Postnatal enlargement of the foramina rotundum, ovale et spinosum and their topographical changes. *Anatomischer Anzeiger*. 1984;156 (5):351-387.

Binod Kumar "Morphometric Study of Foramen Ovale in Human Skull in Population of Bihar." *IOSR Journal of Dental and Medical Sciences (IOSR-JDMS)*, vol. 17, no. 3, 2018, pp 40-43