

Annular Pancreas Presenting With Acute Pancreatitis And Duodenal Obstruction- A Rare Case Report

Dinesh Kumar K, Chandrabose Ambedkar M J,
Rajendran V, Rajendran S

Department of Surgical Gastroenterology, Madras Medical College, Chennai, India
Corresponding Author- Dinesh Kumar K

Abstract: Annular pancreas manifesting in adulthood is rare and presentation after the age of 60 is rarer. We discuss our experience with one case of annular pancreas which presented with recurrent acute pancreatitis and duodenal obstruction. A 60 years old male presented with abdominal pain and features of gastric outlet obstruction. As malignancy is an important differential diagnosis to be considered at this age, the radiological features consistent with annular pancreas (CT & MRI) played a crucial part in clinching the diagnosis preoperatively. Laparotomy confirmed the preoperative findings and areas of saponification around the annulus was also seen. A lateral duodenojejunostomy was done and intraoperative core biopsy of the annular tissue was taken. Postoperative course was uneventful. Biopsy confirmed pancreatic tissue with fibrocollagenous tissue with no evidence of malignancy. This case is being presented for its rarity.

Keywords: Annular pancreas, Duodenal obstruction, Adults, case report

Date of Submission: 03-03-2018

Date of acceptance: 19-03-2018

I. Introduction

Annular pancreas (AP) is an uncommon congenital anomaly. We report the case of a 60-year-old patient who was diagnosed with recurrent acute pancreatitis involving the annular pancreas which resulted in duodenal obstruction. Various theories regarding the embryologic basis that results in the formation of annular pancreas exists. Recurrent pancreatitis, duodenal stenosis at the site of the annulus, or duodenal or gastric ulceration initiate the symptoms in adults.

II. Case Report

A 60-year-old man with 6 months history of recurrent attacks of right upper quadrant and epigastric pain, upper abdominal fullness and non bilious vomiting following food intake presented with signs of dehydration and chronic weight loss. There was no history of jaundice, hematemesis or melena. The patient was hospitalized twice in the past 3 months, underwent upper gastrointestinal endoscopy which showed an edematous duodenum in the region of the junction of the first and second part. A repeat endoscopy performed this time, revealed an unhealthy duodenal mucosa and partial narrowing of the postbulbar region. Biopsy was negative for malignancy. Serum amylase (650 IU) was elevated. WBC (9300 cells/mm³), Hb% (11.3), CA 19-9, serum levels of calcium and triglycerides were within normal limits. Plain abdominal and chest radiographs were normal. Doppler ultrasound of the portal venous system was normal. Abdominal ultrasound showed a wall thickening in the antropyloric region.

Barium meal series revealed a narrowing of the second part of the duodenum (short segment smooth narrowing) with proximal dilatation of the first part of duodenum and stomach [Fig: 1]. An ill defined moderately enhancing soft tissue density lesion noted around the second part of the duodenum with occlusion of the second part of the duodenum was seen in the abdominal CT [Fig:2]. Fat stranding was noted surrounding the lesion.

MR imaging showed a smooth narrowing of D2 segment of duodenum with pancreatic parenchyma surrounding the D2 posteriorly and anteromedially [Fig:3]. Patient was optimized before definitive surgery which included correction of hypokalemia associated with chronic gastric outlet obstruction.

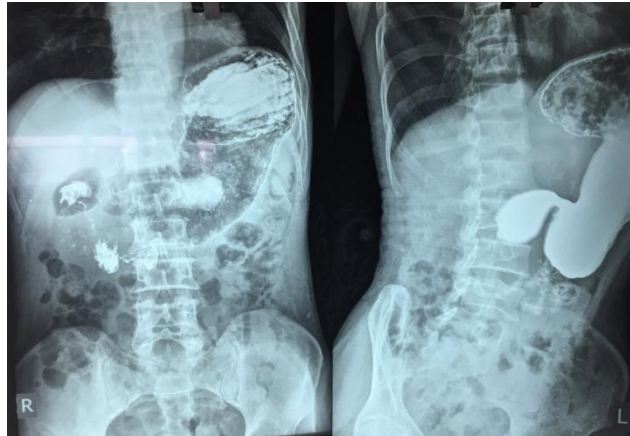

Fig 1: Barium meal series shows narrowing of 2nd part of duodenum with dilatation of proximal duodenum and stomach

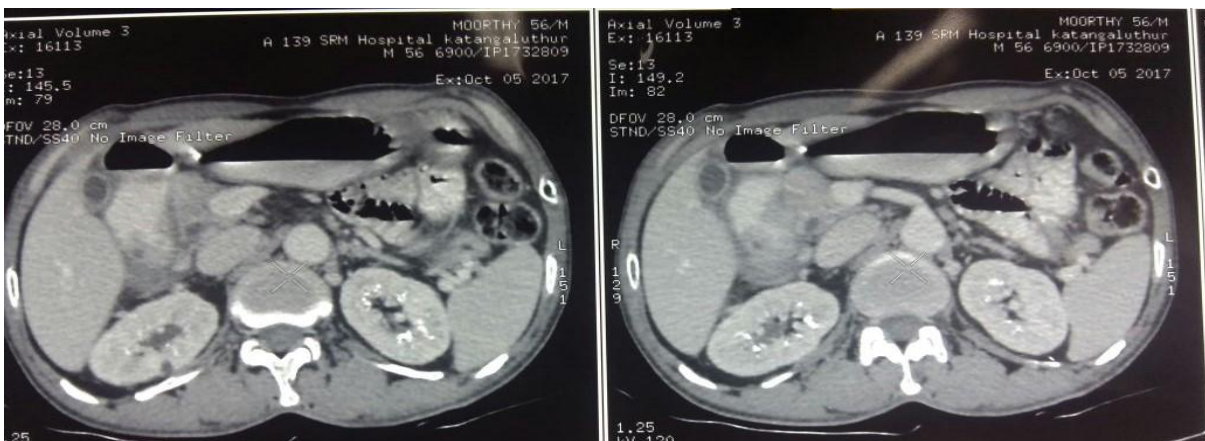

Fig 2: CT abdomen shows ill defined moderately enhancing soft tissue density lesion noted around the second part of the duodenum with near total occlusion of the second part of the duodenum

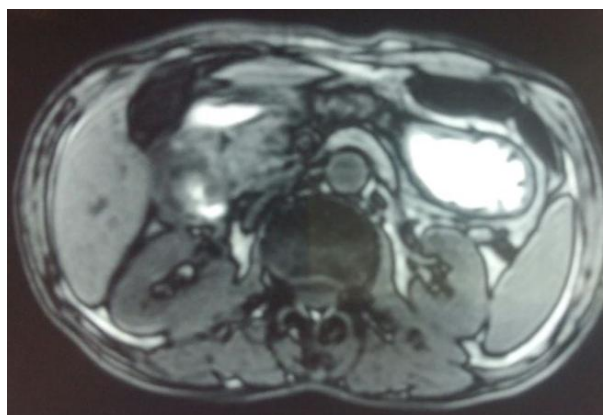


Fig 3: MRI abdomen shows smooth narrowing of D2 segment of duodenum with pancreatic parenchyma surrounding the D2 posteriorly and anteromedially

Intraoperatively the stomach and the first part of the duodenum were found to be grossly dilated[Fig:4]. A rim of pancreatic tissue with significant fat stranding and features of saponification was found encircling the junction of the first and the second part of the duodenum[Fig:5]. A limited Kocher maneuver with evaluation of the involved segment of the duodenum and the pancreas was done to rule out the presence of a mass lesion. A core biopsy of the annulus was also done. A lateral side to side duodenojejunostomy was fashioned. Postoperative course was uneventful and was discharged on 8th post operative day. The core biopsy shows pancreatic tissue with fibrocollagenous tissue and negative for malignancy.

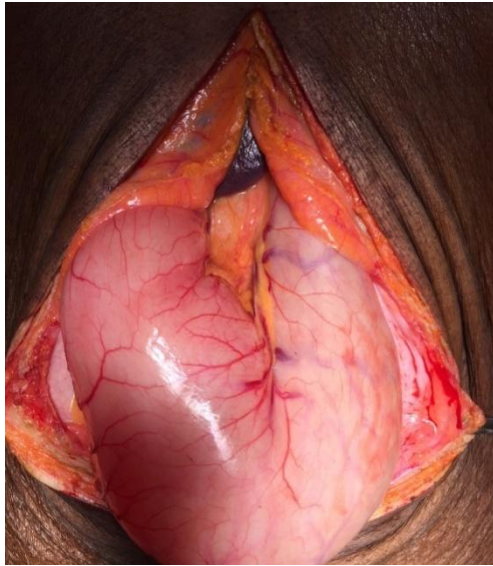


Fig 4: Dilated stomach and 1st part of duodenum

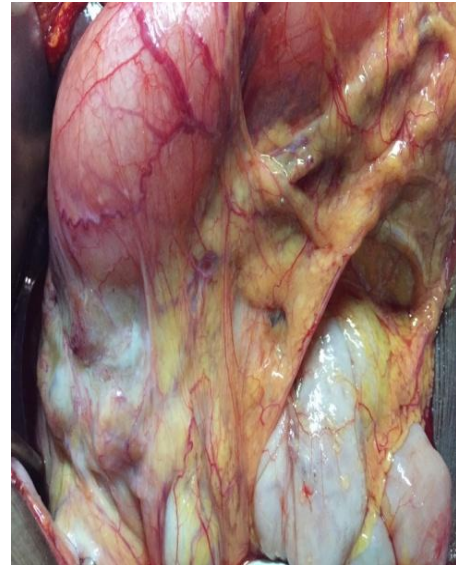

Fig 5: Rim of pancreatic tissue around the duodenum

III. Discussion

Annular pancreas is a rare anomaly that affects approximately 1 in 20,000 newborns [1]. It is due to an embryologic migration fault and has been associated with other congenital anomalies, including Down's syndrome, tracheoesophageal fistula, intestinal atresia, pancreas divisum, and pancreaticobiliary malrotation [2]. Several hypotheses regarding the causes of this condition exist. One such hypothesis, known as Lecco's theory, suggests that adhesion of the distal tip of the ventral primordium to the duodenal wall, prior to its migration, creates an obstructive pancreatic ring [3]

The second part of the duodenum is affected in three fourths of the patients whereas the first and third duodenal parts constitute 21% of cases [4]. Majority of these cases are observed very early in life more commonly in males. In infants, it is usually characterized by severe duodenal obstruction requiring immediate surgical intervention. However, in other cases, the obstruction may be minimal at birth and the patient remains asymptomatic for life. When clinical manifestations occur in adults, symptoms generally include the onset of cramps, epigastric pain, and postprandial fullness relieved by vomiting. Other conditions associated with an annular pancreas are peptic gastroduodenal ulcers, acute and chronic pancreatitis, pancreaticolithiasis, and duodenal obstruction [5,6,7,8].

Pancreatitis due to annular pancreas is generally confined to the annulus and to the adjoining pancreatic head, preserving the body and tail of the gland [9]. Its pathogenesis is related to the inability of pancreatic secretions to flow through the accessory duct (Santorini duct), although the flow of secretions in the main pancreatic duct allows the body and tail of the pancreas to remain intact [10]. The related inflammation of the annulus may cause an obstruction of the encircled duodenum. In most cases, the initial CT scan confirms the diagnosis of pancreatitis resulting from an annular pancreas since a ring of inflammatory pancreatic tissue is revealed surrounding the duodenum. Sometimes, for the associated duodenal obstruction, a gastroduodenoscopy will show concentric narrowing and prestenotic duodenal dilatation. In upper gastrointestinal double contrast studies, the presence of an annular filling defect of the duodenum associated with a proximal dilation of the duodenal bulb and stomach ("double bubble" sign) are classic signs of an obstructive annular pancreas. Endoscopic ultrasonography can also be very useful in the diagnostic process [11].

The clinical course of the pancreatitis and duodenal obstruction is generally resolved by medical management. In case of failure of the medical treatment, several procedures have been proposed to facilitate the gastrointestinal clearance. It is generally acknowledged that removal of the pancreatic annulus is hazardous as the pancreatic tissue may be intramural [12]. Bypass surgery of the annulus by duodenojejunostomy or gastrojejunostomy seems to be the preferred method of treatment in the case of persistent duodenal obstruction. Duodenojejunostomy is ideal choice if possible because it does not disturb the normal physiology as it happens in gastrojejunostomy.

IV. Conclusion

Annular pancreas is one of the rare causes of acute pancreatitis and duodenal obstruction in adults. Preoperative diagnosis is often difficult. Though CT and MRI abdomen are the imaging methods used for diagnosis, surgery is necessary to confirm the diagnosis and for the management of duodenal obstruction.

References

- [1] Paraskevas G, Papaziogas B, Lazaridis C, Gigis P, Papaziogas T. *Annular pancreas in adults: embryological development, morphology and clinical significance. SurgRadiolAnat 2001; 23:437-42. [PMID 11963628]*
- [2] Mavridis G, Soutis M, Sakellaris D, Keramidas D. *Annular pancreas. ActaChirHellen 1995; 67:597-600.*
- [3] Lecco TM. *Zurmorphologie des pancreas annulare. Sitzungberichte de KaiserlichenAkademie der Wissenschaften 1910; 69:391-406.*
- [4] Hollender L, Marie A. *PankreasAnnulare. In: ChirurgischeGastroenterologie, von Allgower M, Harder F, Hollender F, Peiper J (eds) ChirurgischeGastroenterologie Berlin: Springer,1981;1058-60.*
- [5] Ladd AP, Madura JA. *Congenital duodenal anomalies in the adult. Arch Surg 2001; 136:576-84. [PMID 11343551]*
- [6] Urayama S, Kozarek R, Ball T, Brandabur J, Traverso L, Ryan J, Wechter D. *Presentation and treatment of annular pancreas in an adult population. Am J Gastroenterol 1995; 90:995-9. [PMID 7771437]*
- [7] Gilinsky NH, Lewis JW, Flueck JA, Fried AM. *Annular pancreas associated with diffuse chronic pancreatitis. Am J Gastroenterol 1987; 82:681-4. [PMID 3605030]*
- [8] Yogi Y, Kosai S, Higashi S, Iwamura T, Setoguchi T. *Annular pancreas associated with pancreatolithiasis: a case report. Hepatogastroenterology 1999; 46:527-31. [PMID 10228856]*
- [9] Itoh Y, Hada T, Terano A, Itai Y, Harada T. *Pancreatitis in the annulus of annular pancreas demonstrated by the combined use of computed tomography and endoscopic retrograde cholangiopancreatography. Am J Gastroenterol 1989; 84:961-4. [PMID 2756989]*
- [10] Drey NW. *Symptomatic annular pancreas in the adult. Ann intern Med 1957; 46:750-72. [PMID 13411884]*
- [11] Papachristou GI, Topazian MD, Gleeson FC, Levy MJ. *EUS features of annular pancreas (with video). GastrointestEndosc 2007; 65:340-4. [PMID 17259001]*
- [12] Ravitch MM, Woods AC Jr. *Annular pancreas. Ann Surg 1950; 132:1116-27. [PMID 14790583]*

Dinesh Kumar K "Annular Pancreas Presenting With Acute Pancreatitis And Duodenal Obstruction- A Rare Case Report" IOSR Journal of Dental and Medical Sciences (IOSR-JDMS) , vol. 17, no. 3, 2018, pp. 47-50