

Evaluation of Low Back Pain using MRI and its findings in patients attending Radiology Department of Rajendra Institute of Medical Sciences in Ranchi – A Cross sectional analysis .

Dr Suresh Kumar Toppo¹, Dr Pulak Abhishek², Dr Rajeev Kumar Ranjan³

¹Professor and Head , Department of Radiology ,Rajendra Institute of Medical Sciences ,Ranchi

²Senior Resident , Department of Radiology ,Rajendra Institute of Medical Sciences ,Ranchi

³Associate Professor , Department of Radiology , Rajendra Institute of Medical Sciences ,Ranchi

Corresponding Author: Dr Pulak Abhishek

Abstract:

Background Back pain in lower region , is probably one of the commonest ailments people have in India and world over , spanning across both sexes affecting commonly middle and old ages across urban and rural population. In India apart from Tuberculosis, other important reasons are trauma , chronic ailments, inflammation , radiculopathy ,neuropathy and neoplastic reasons . It is further compounded with the fact that people initially resort to homemade therapies for its treatment , and wait and then seek medical consultation. Under these circumstances , an accurate diagnosis can be made by using Magnetic Resonance Imaging i.e MRI . This study was done to describe the various lesions identified using MRI. **Methodology** The present study was hospital based cross sectional starting Feb 2017 to Dec 2017. A total of 236 cases were evaluated and their MRI reports evaluated for the findings. Those patients who were unwilling to participate were excluded. Data was collected using a pretested questionnaire. Standard statistical measures were used to describe the results. **Results** 122 and 114 males and females respectively were studied, age range 20-70 years with a mean age 28.56, the age group of 30-50 was the most affected with disc degeneration. Infective causes primarily Tuberculosis was most common in age group of 30-40. Overall Disc degeneration was the most common finding while overall 13.56 % findings on MRI were Normal. **Conclusion** Middle ages are prone to develop degenerative changes of the discs , MRI helps in pin pointing the reasons behind that , where facility allows MRI should be done to evaluate the presenting cases of Lower Back Pain .

Date of Submission: 09-04-2018

Date of acceptance: 23-04-2018

I. Introduction

Pain in lower back is probably one of the most ignored symptoms affecting middle age males, females of urban or rural area almost in equal proportions across the country. (1) Often it is ignored by the affected ones till it becomes hampering daily routine. It involves spine and back muscles. Generally lower back pain is classified as acute, subacute and chronic depending on time since occurrence namely acute (start <6 weeks), subacute (>6-12 weeks) and chronic lower back pain (≥ 12 weeks)(2). Most adults 2/3rd have suffered from lower back pain in their lives at some point of time.(3) Low back pain has been documented to be having a very high prevalence nearing 85% (4) Low back pain in many cases are self-limiting almost in 95% cases it's hard to find etiology .(5,6)

In order to achieve an accurate diagnosis, apart from X- rays, CT Scans and Bone Scans, MRI plays an important role with its clear soft tissue resolution, better visualization of disc material and identification of any bony pathology. On identification of any lesion, further characterization of lesions were done using T1, T2, T2 fat sat ,myelogram & post contrast MRI (7). It has the added advantage of being devoid of ionizing radiation , better spatial resolution in delineation of the bone ,disc ,ligament ,nerve ,thecal sac , spinal cord & soft tissue. (8)

This study was done in order to understand the nature of presenting patients with lower back pain in Rajendra Institute of Medical Sciences in Ranchi to understand the nature of lower back pain.

II. Methodology

The present study was hospital based prospective starting Feb 2017 to Dec 2017. A total of 236 cases were evaluated and their MRI reports evaluated for the findings. All patients aged 20-70 years ,who were referred to the Radiology department for MRI lumbar spine, with Lower Back pain, were included in the study.

Those patients who had claustrophobia , history of surgery , had ferromagnetic implants installed and not willing to participate in the study were excluded. Data was collected using a pretested questionnaire.

Procedure for Imaging and Image Analysis.

All patients referred for MRI lumbar spine were evaluated using MRI as per standard protocol .Included planes were axial ,sagittal and coronal T1 and T2 weighted images along with T2 fat sat images . According to the need special sequences including myelogram, gadolinium enhanced T1 weighted images were conducted. All images were reviewed on work station.

Statistical Analysis

Standard statistical measures were used to describe the results e.g.mean, standard deviation, percentages etc.

III. Results

Out of total 236 patients In our study 47.46% were male while rest were females. We clubbed annular disc bulge, disc herniation and annular fissures together as disc degenerative diseases .While other etiologies found were Traumatic vertebral collapse, Osteoporotic Collapse , Infection(tuberculosis) and Neoplasm. Age of the patients were in range of 20years to 70 years with mean of 28.56 ± 6 years .(Table 1) The common causes for back pain were Disc Degeneration (68.64%) Traumatic vertebral collapse(3.81%) Osteoporotic Collapse(3.39%) Infection (tuberculosis) (8.47%) and Neoplasm(2.12%) ,almost 14% of patients coming with Lower Back pain didn't had any findings on MRI (Chart 1)

Age Group	Findings						Total
	Disc Degeneration	Traumatic vertebral collapse	Osteoporotic Collapse	Infection	Neoplasm	Normal	
>20 - ≤30	18	2	0	0	0	25	45
>30 - ≤40	65	3	3	15	2	4	92
>40 - ≤50	40	2	0	4	2	1	49
>50 - ≤60	29	2	1	1	1	2	36
>60 - ≤70	10	0	4	0	0	0	14
Numbers	162	9	8	20	5	32	236
Percentage	68.64	3.81	3.39	8.47	2.12	13.56	

Table 1. Table showing the age group and findings of different etiologies

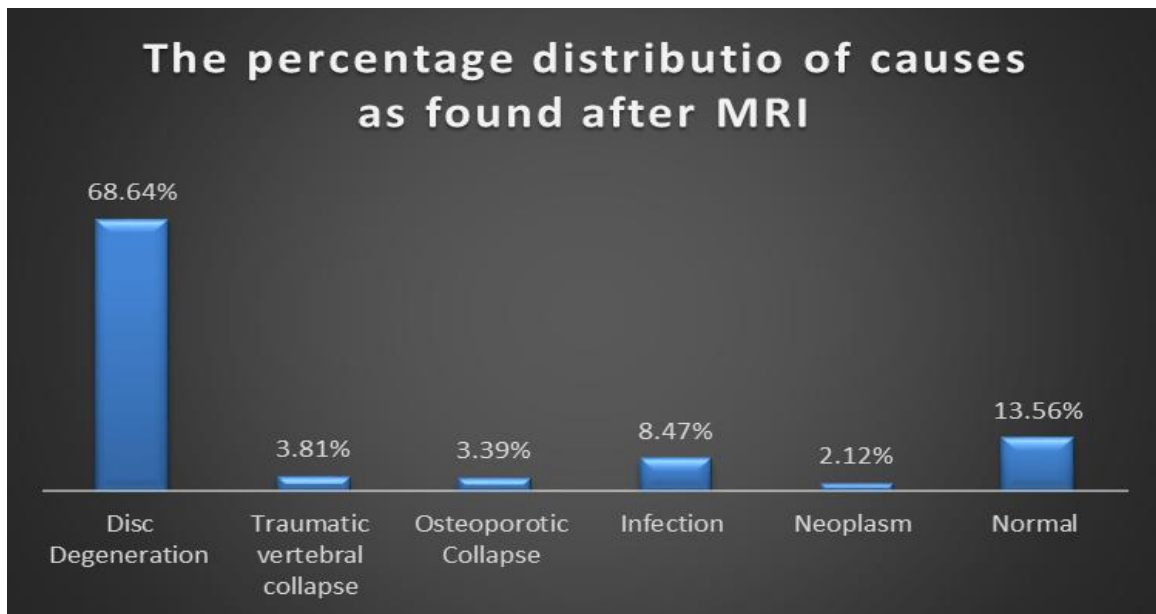


Chart 1 .Frequency Distribution in percentage of the various causes after MRI .

The most common cause in this study for lower back pain was disc degenerative diseases (68.64%) which included disc bulge, disc herniation and annular fissures. (Chart 1) The second important cause was infection primarily Tuberculosis prevalent in this part of country .Though MRI was normal for 13.56% cases ,other incidental cause for back pain were found like ruptured cyst ,hemorrhagic cyst , and pelvic inflammatory diseases in females & ureteric calculus in males.

IV. Discussion

In our study we found males in the age group of 30-50 to be affected most by lower back pain . This finding is similar to recent published data about the prevalence of low back pain which puts the prevalence between 6 to 10% in general population while increasing it to 92% in male dominated professions .(9)

Degeneration of Disc

Mostly degenerative changes are seen in elderly age groups . With increasing age the disc tissue also undergoes biochemical changes with alteration in collagen & proteoglycan content causing decreasing hygroscopic nature of disc resulting in disc dehydration. MRI gives an added advantage in the form of T1 and T2 weighted axial , sagittal and coronal visualization of vertebral plates and intervertebral disk . We found MODIC changes from Type 1 to type 3 as described .(10) Other mentioned studies too found most common cause of lower back pain to be the degenerative disc changes .

Trauma- In our study we found only 3.81% cases to be having trauma evident on MRI .

Infection -Tuberculosis is prevalent in these parts , 8.47% cases were found of having tuberculosis . These findings are similar to the studies and findings published (8,9)

Neoplasm – Generally a rare cause for lower back pain but can range from completely benign tumor to malignant bone tumor . MRI is relatively superior imaging diagnostic modality with a sensitivity of 83% to 100% and specificity of 93% (11) IN our study we got 5 cases of neoplasm which after histopathology exams were classified as malignant giant cell tumor . Other studies too have found similar cases of neoplasm in MRI .

V. Conclusion

MRI is an useful imaging modality for diagnosis of lower back pain. It gives vivid picture of the associated lesions if any and will help in better operability.

Conflicts of Interest

None

References

- [1]. Gopalakrishnan N, Nadhamuri K, Karthikeyan T. Categorization of pathology causing low back pain using magnetic resonance imaging (MRI). *J ClinDiagn Res.* 2015;9(1):17-20.
- [2]. Harrison's Principles of Internal Medicine -19thedition .
- [3]. Jarvik J, Deyo R. Diagnostic evaluation of low back pain with emphasis on imaging. *Ann Intern Med.* 2002;137:586–95.
- [4]. Andersson G. Epidemiological features of chronic low back pain. *Lancet.* 1999;354:581-85.
- [5]. Atlas SJ, Deyo RA. Evaluating and managing acute low back pain in the primary care setting. *J Gen Intern Med.* 2001;16:120–31.
- [6]. Kinkade S. Evaluation and treatment of acute low back pain. *Am Fam Physician.* 2007;75(8):1181–88.
- [7]. Munter MF, Wasserman AB, Hsiu-Mei Wu, Yousem DM. Serial MR Imaging of annular tears in lumbar intervertebral disks. *Am J Neuroradiol.* 2002;23:1105-09
- [8]. Sadhanandham, Ranganathan . Evaluation of low back pain with low field open magnetic resonance imaging scanner in rural hospital of Southern India . *J Neurosci Rural Pract.* 2016 Jul-Sep; 7(3): 368–373.
- [9]. Bindra S, Sinha AG, Benjamin AI. Epidemiology of low back pain in Indian population: A review. *Int J Basic Appl Med Sci.* 2015;5:166–71
- [10]. Modic MT, Steinberg PM, Ross JS, Masaryk TJ, Carter JR. Degenerative disk disease: Assessment of changes in vertebral body marrow with MR imaging. *Radiology.* 1988;166(1 Pt 1):193–9.
- [11]. Kosuda S, Kaji T, Yokoyama H, Yokokawa T, Katayama M, Iriye T, et al. Does bone SPECT actually have lower sensitivity for detecting vertebral metastasis than MRI? *J Nucl Med.* 1996;37:975–8.

Dr Pulak Abhishek "Evaluation of Low Back Pain using MRI and its findings in patients attending Radiology Department of Rajendra Institute of Medical Sciences in Ranchi – A Cross sectional analysis ."IOSR Journal of Dental and Medical Sciences (IOSR-JDMS), vol. 17, no. 4, 2018, pp 25-27.