

Clipping of Middle Cerebral Artery Aneurysm –A Review Of 45 Cases

Dr Pawan Garg; Dr Sanjiv Sinha; Dr Ajay Sharma

Department Of Neurosurgery; Professor, Department Of Neurosurgery; Professor And Head, Department Of Neurosurgery, G.B.Pant Hospital, Delhi.
Corresponding author: Dr Pawan Garg

Abstract: Middle Cerebral Artery Aneurysm (MCAA) Accounts For Approximately 18-20 Percent Of All Intracranial Aneurysms. These Aneurysms Are Divided Into Three Categories According To Their Origin: Proximal Aneurysms, Which Are Located On The Main Trunk, M1 Segment (10-15%); Bifurcation Aneurysms, Which Are Located At The First Major Bifurcation Or Trifurcation (80-85%); And Distal Aneurysms Which Are Located Beyond The Major Bifurcation (5%). In Our Series Of 45 Patients, Total 52 Aneurysms Were Seen. Out Of Them, 12 Aneurysms Were Small Sized (2-7mm); 27 Aneurysms Were Medium Sized; 12 Aneurysms Were Large (15-25mm) Sized And 1(1.92%) Was Giant Aneurysm. We have treated all by surgical clipping of aneurysm. **METHOD:** Data Was Collected From The Admission Record Of The Patients Of Middle Cerebral Artery Aneurysms, Presented To The Department Of Neurosurgery At G. B. Pant Hospital, Delhi During Last 5 Years (Aug. 2003 To July 2008). Total 45 Patients Were Diagnosed To Have MCA Aneurysm And Were Managed In Our Department During This Period. We Retrospectively Reviewed The Records Of These Patients To Analyze Clinical Outcomes. **RESULTS:** Most Common Age Group Was 46-55 Years Which Included 14 Patients. Mean Age Group In Our Study Was 50 Years. 24 Patients Were In Age Group 36-55 Years. 11 Patients Were Included In Age Group Above 55 Years. At Presentation, 27 patients Were In H&H Grade 1; 3 Were In H&H Grade 2; 11 Were In H&H Grade 3; 4 Patients Were In H&H Grade 4. There Was 8.33% Mortality In Small Sized Aneurysms; 37% In Medium Sized; 25% In Large Sized And 100% In Giant Aneurysm. Glasgow Outcome Scale Of 4 And 5 Was Seen In 44% Of Patients Presented With Proximal MCA Aneurysm And 60.5% In Those With Bifurcation And Trifurcation Aneurysm. Glasgow Outcome Scale Of 4 And 5 Was Seen In 28(62.2%) Patients While 13(28.8%) Died. **CONCLUSION:** To conclude, patients presenting with poorer Hunt and Hess grade, World Federation of Neurological Surgeons grade and Fisher grade on admission has poor outcome. Post operative check cerebral angiography is a good tool of assessing the effectiveness of clipping and distal cerebral circulation. The surgical outcome of our series is comparable to various international series. Surgical Clipping Continues To Be A Good Option For The Treatment Of Middle Cerebral Artery Aneurysm.

Keywords: MCAA -Middle Cerebral Artery Aneurysm, H&H-Hunt and Hess, DSA- Digital Subtraction Angiography, Glasgow Outcome Scale, Glasgow Coma Scale

Date of Submission: 10-04-2018

Date of acceptance: 24-04-2018

I. Background

In neurosurgical practice, MCA aneurysms present as subarachnoid hemorrhage (SAH) or as an unruptured incidental aneurysm (UIA). Unruptured incidental MCA aneurysms usually present as a mass effect in the form of increased intracranial tension. MCA aneurysms may be diagnosed as part of routine screening as unruptured MCA aneurysms. Unruptured MCA aneurysms can produce symptoms like headache, temporal lobe epilepsy, visual field deficits and papilloedema. MCA aneurysms are the most common aneurysm manifesting with ischemic symptoms, which can be in the form of transient ischemic attacks and hemi paresis. Epilepsy and hemi paresis are most common disabilities, associated far more frequently with MCA aneurysms than with aneurysms at other sites². Another well known presentation is subarachnoid hemorrhages (SAH) which manifest as headache, loss of consciousness and focal neurological deficit. Unilateral headache in MCA aneurysms rupture is almost always on the side of the aneurysm. Loss of consciousness is seen in about 60% and focal neurological deficit in about 80% of patient of MCA aneurysms². The frequencies of intracerebral hematomas are more common in patients with MCA aneurysms than in patients with ruptured aneurysms at other sites. Most of the intracerebral hematomas occur in patients with MCA bifurcation aneurysms that are directed laterally².

An early Computed Tomography (CT) scan is must to establish the diagnosis of subarachnoid hemorrhages, to localize and quantitate the amount of blood in the cisterns, to predict the location of vasospasm,

and to rule out an intracerebral hematoma. CT scan detects subarachnoid hemorrhage in 90-95 % of patients within the first 24 hours of the ictus. However CT angiography and Magnetic Resonance Angiography (MRA) are other diagnostic modalities. CT angiography is superior to Magnetic resonance angiography as its sensitivity varies from 96-100%. Cerebral Digital Subtraction Angiography (DSA) is regarded as the gold standard for detection of middle cerebral artery aneurysms

MCA aneurysms can be managed surgically or by endovascular means. Surgical approaches for management of MCA aneurysms are pterional or keyhole supraciliary fronto-lateral craniotomy. In the pterional approach, aneurysm can be dissected by opening the Sylvian fissure or through the superior temporal gyrus.

The reported causes of poor outcome in patient with MCA aneurysm are^{1, 2} (a) Severe primary bleeding (b) Subsequent bleeding. (c) Brain infarction due to vasospasm (d) Postoperative infection. (e) Pulmonary embolism. (f) Infarction due to main vessel occlusion. (g) Aneurysmal rupture (h) Postoperative hematoma. (I) Focal neurological deficit like dysphasia, visual field deficit.

Difficulty is encountered in management of middle cerebral artery aneurysms if there is^{1, 2}:- (a) Association of intracranial hematoma usually of diameter ≥ 2.5 cm in patients with ruptured MCA aneurysms. (b) Pre-operative or admission Hunt and Hess grading is higher in patients with MCA aneurysms than in patients with ruptured aneurysms at other sites. (c) The lenticulostriate vessels exits mainly proximal to bifurcation and they are usually adherent to the aneurysm. (d) Calcification or atherosclerosis in the neck. (e) Adhesion of major divisions and sometimes small perforating vessels to the neck. (f) Presence of giant aneurysm which is approximately 9% as compared to 4% seen in other aneurysmal sites. (g) The neck of proximal MCA is often wide making them difficult to clip or coil. (h) Medially directed aneurysm which causes higher risk for perforator injury during surgery.

II. Pathophysiology Of Aneurysmal Rupture²⁸

The consequences of SAH depend on the volume and location of the bleeding as well as the preexisting size of the cerebrospinal fluid (CSF) Space into which the aneurysm ruptures. There may be a very small SAH from the aneurysm that causes only a sudden severe headache and corresponds to a ‘warning leak’ or ‘sentinel hemorrhage’. There is a general correlation between the volume of SAH and the clinical grade, risk of vasospasm, and other complication such as increased intracranial pressure, seizure and hydrocephalus.

The physiological changes such as reduced cerebral blood flow and metabolism, systemic alteration such as hyponatremia, hypovolemia, hyper-metabolism, catabolic state, cardiac arrhythmia, cardiac wall motion abnormality tends to increase with increasingly severe SAH. Bleeding stops by combination of tamponade due to the reduced transmural pressure gradient across the aneurysm and coagulation. The global increase in intracranial pressure which causes transient loss of consciousness does not occur in all patients with SAH.

There is a direct correlation between mean ICP increase and clinical grade, which is:-

a) Clinical grade 1 and 2-Mean ICP of 10 mmHg, b) Clinical grade 2 and 3-Mean ICP of 18mmHg, c) Clinical grade 3 to 5 - Mean ICP of 29mm Hg At present, there are three MRI –compatible aneurysm clips in routine use:- A) Yasargil, B) Sugita, C) Spetzler clips. Common applicator in use is:- A) Olivecrona, B) Yasargil, C) Sugita.

III. Materials And Methods

This retrospective study of “Clipping of middle cerebral artery aneurysm-A review of 45cases: included patients admitted in neurosurgical ward of G.B Pant Hospital from August 2003-July 2008 with middle cerebral artery aneurysms. This included patients of any age, sex, caste and religion presented with sudden onset headache, vomiting and loss of consciousness. They were graded under subarachnoid hemorrhage Hunt and Hess grade 0-5, World Federation of Neurological Surgeons (WFNS) grade 1-5 and Fisher grade 1-4. All patients with subarachnoid hemorrhage were admitted and investigated and those diagnosed as having middle cerebral artery aneurysm were included in the study. Patients were subjected to pterional craniotomy in standard fashion and clipping was performed. Post operatively neurological status was graded according to Modified Rankin Scale (0-5) and Glasgow Outcome Scale (1-5) and patients were followed regularly. Check DSA was done 3 month after surgery in follow up. Digital Subs traction Angiography (DSA) was done in all patients except where it was not possible due to technical reasons. The CT Angiography and MR Angiography were the alternative modes of diagnosing the MCA aneurysm where DSA could not be done. Surgery was done at the earliest possible in all the patients. Pterional craniotomy and opening the Sylvian fissure by splitting the fissure in a medial to lateral direction. The internal carotid artery was identified and followed laterally along the MCA. This approach has the advantage of proximal control and exposing the neck before the dome. The disadvantage was that the dissection performed was relatively extensive and risks injury to the banks of the sylvian fissure.

PROCEDURE- CLIPPING:

Middle cerebral artery aneurysms are approached through either pterional or keyhole supraciliary front lateral craniotomy. Three approaches, which are based on the pterional approach that Yasargil popularized, can be used in surgical treatment of MCA aneurysms.

Clip Application:-

Clipping of MCA more commonly require reconstruction of the origins of the parent vessels at the aneurysm neck. Clip application parallel, as opposed to perpendicular to the axis of the vessels, is an important aspect of reconstruction. It can also be assisted by fenestrated clips. A flush reconstruction, compromises the flow within the lumina of the branch vessels, especially with atherosclerotic aneurysmal necks. Slimline aneurysmal clips are useful for MCA aneurysms particularly those arising from lenticulostriate perforators. The weight of larger clips predispose to avulsion of the aneurysm. It is important to note that how the sylvian fissure rest on the clip after removal of retractors. Larger clips can undergo torquing leading to stenosis or occlusion of the parent vessel.

Table 1: -Surgical approaches to middle cerebral artery aneurysm.

	Medial Transsylvian (Proximal to distal) approach	Lateral Transsylvian (distal to proximal) Approach	Superior temporal gyrus approach
Advantages	Early proximal control Exposure of aneurysm neck before the dome	Require less dissection to reach aneurysm complex	Require less brain retraction. Sylvian veins left undisturbed. Avoids dissection of circle of Willis and risk to perforators. Good visualization of the aneurysm complex between the neck and M2 branches.
Disadvantages	More extensive dissection	Proximal control not achieved early before aneurysm complex is identified. May be difficult to split the sylvian fissure distally in the setting of Subarachnoid hemorrhages and a swollen brain	Does not achieve early proximal control. Possible risk of inducing seizures. Requires slightly larger bone flap
Preferred approach for:	Most bifurcation/trifurcation aneurysms especially those with a short M1 segment aneurysms	Bifurcation aneurysm with a long M1 trunk. Aneurysms distal to the bifurcation	Aneurysms with temporal lobe hematomas particularly when swelling hinders ability to split the sylvian fissure
Contraindicated for:-		M1 segment aneurysm. Bifurcation aneurysm with a short M1	Bifurcation aneurysms with a short M1 Aneurysms that project back over the insula

Pterional Approach:-

- 1) Position of the patient:- The patient is positioned supine with the head on three-four point skeletal fixation devices like Mayfield-Kees or Sugita. A right sided craniotomy is preferred for right handed surgeon and right-sided lesion. The head is directed about 20° vertex down, elevated slightly, and rotated about 30° to the left to bring the malar eminence to the superior point of the operating field. This position will cause the operating field to incline slightly toward the surgeon, allowing the frontal lobes to fall away from the orbital roof. The sphenoid ridge will be directed vertically in the operating field. The skeletal fixation device should be placed with one prong behind the ear, just above the ipsilateral mastoid and with the two prongs on the left side of the head. The prongs should be high enough on the skull (above the linea terminalis) that they do not enter the temporalis muscle which will lead to instability as well as bleeding.
- 2) Skin Incision: Incision begins 1cm in front of the ear, extends upward to the temporal crest, then turns downwards and ends horizontally in one of the natural skin creases of the forehead. Damage to the temporalis muscle and the frontalis branch of the facial nerve must be avoided. Cutting across the muscle fibers produces the atrophy, leading to temporo-mandibular joint problems and a noticeable indentation in the temple. Damage to the temporalis branch of the facial nerve produces weakness of the frontalis muscle and causes the eyelid to droop, thus obscuring upward vision with a cosmetic anomaly. Elevating the temporalis muscle with the skin flap solves the problem. During closure, the muscle must be reattached to the cranium. Failure to reattach the muscle produces a bulge above the zygoma.
- 3) Craniotomy:- The bone flap is initiated with a frontal burr hole just superior to the frontal suture under the linea temporalis. A second hole is placed in the frontal bone 3-4cm superior to the first and 1-2cm

above the orbital rim, avoiding if possible the frontal sinus. A third hole is positioned in the parietal bone along the linea-temporalis variably behind the coronal suture. The final corner of the bone flap is marked by a burr hole in the squamous temporal bone behind the sphenotemporal suture, about 4cm to the third and 3cm posterior to the first. In 1976, first electric powered drill which stops automatically as the dura is encountered was employed. The squamous temporal bone and greater wing of sphenoid are rongeured further inferiorly toward the floor of the middle fossa (allowing more mobility of the temporal lobe) to reach the tentorial edge.

The posterior edge of the greater wing of sphenoid is progressively flattened until a small ridge representing the most lateral aspect of the lesser wing is reached. A small bridging vessel, the orbital-meningeal artery (anastomotic branch of the ophthalmic artery to the middle meningeal artery) is almost seen. Variable amounts of hemorrhagic ooze is expected from the middle of the sphenoid ridge in the distribution of two orbitomeningeal artery and from each side to the ridge along the sphenosquamous and sphenofrontal sutures in the area of two orbito-meningeal artery branches. The bleeding can be easily controlled by wax and cautery.

- 4) Dural opening:- The dura is opened in a semicircular fashion around the sylvian fissure, arched toward the sphenoid ridge and orbit. The frontal lobe is gently retracted allowing easy access and entrance into the carotid, chiasmatic, and lamina terminalis cisterns, thereby releasing CSF and providing the room for easy dural tacking. The lamina terminalis can also be incised allowing CSF release from the third ventricle especially if the basal cisterns are blocked by adherent hematoma.
- 5) Arachnoid opening: Both the sylvian cistern between the basal frontal and temporal lobes and the whole lamina terminalis cistern adhering to the frontal lobes to the optic nerves and chiasm are opened.
- 6) Enlarging the apex of the pyramid:- Using the arachnoid knife, the sylvian cistern is entered at the level of the opercular frontal gyrus. The arachnoid of the sylvian cistern may be thin and transparent or may be milky, yellow, or even opaque following a subarachnoid haemorrhage. The superficial middle cerebral veins are one or more large venous channels that course on the temporal side of the sylvian fissure. They generally empty into the sphenoparietal or cavernous sinuses, but will occasionally continue around the temporal pole to the superior petrosal sinus. The arachnoids of the sylvian cistern should be opened on the frontal side of these veins so that they will not cross the sylvian fissure when the frontal lobe is retracted.
- 7) Aneurysm clipping:- The middle cerebral trunk is prepared for possible temporary occlusion before the aneurysm is dissected. A potential site should select for placement of temporary clips that avoids injury to the lenticulostriate perforating arteries. Aneurysm should be clipped under relative hypotension of systolic blood pressure of 100-120mm Hg. Dissection should begin at the aneurysm base because the body and dome are fragile and are the potential site of rupture. The aneurysm neck should be freed from adhesion to the surrounding arteries and the brain. Many MCA aneurysms are multilobulated or bulbous. Often they have broad neck, making clipping difficult. Using short burst of bipolar, aneurysmal tissue can be shrunk to make it clippable. Sclerotic, calcified and partially thrombosed aneurysm do not respond to cautery and they need thromboembolectomy.

Placing the blades of the clip exactly at the aneurysm-artery junction not only kinks or occludes the arterial branches but also causes aneurysm to tear at its base. After clipping, we may apply additional cautery to the aneurysm and reposition the clip until final position of the clip is achieved. Large, giant, or globular aneurysms have thick walls that prevent the tips of the aneurysm clip from closing. In these cases, we use Drake's tandem-clipping technique. Fenestrated clips are applied proximally and because the crotch of the fenestrated jaws is not held open by the aneurysm wall, the tips of the clip are able to close. A non fenestrated clip is used as a distal clip, which seals the proximal portion of the aneurysm that is missed by the fenestration of the proximal clip²².

TEMPORARY CLIPPING: Temporary clipping of intracranial vessels in aneurysm surgery was introduced by Pool in 1960. The use of temporary clipping has become an important tool in aneurysm surgery. The study included 62 patients, detailing operative protocols and results. Twenty-two had unruptured aneurysms (35%), 15 patients were in grade I (24%), 16 patients were in grade II (25%), 5 patients were grade in III (8%) and 4 patients were in grade IV (7%). The aneurysms were mainly located in the MCA in 29 patients. 11 patients developed a new, persistent post-operative deficit. In 1 case (2%), temporary clipping resulted in the development of deficit. Overall 92% of his patients with temporary clipping had good to excellent outcome, with 3% mortality and 5% morbidity. Thus temporary clipping is a safe procedure. There were 29 patients requiring temporary clipping for MCA aneurysms. 25 were electively clipped, four after intra-operative rupture. 14 of the patients had giant MCA aneurysm, of which eight were clipped following subarachnoid haemorrhage. The median temporary clipping time of patients without deficit was 13 minute⁶.

Sugita or Yasargil temporary clips (Downs, Aesculap) are used for temporary vascular occlusion. The measured blade pressure is 40-80g, depending upon the size of the particular artery to be occluded. For small vessels, Kleinert-Kurtz clips are applied. Usually for a vessel of 2.0mm or less, like the distal MCA or ACA, 40-g-force

temporary clips are sufficient for occlusion. Large vessel like ICA, vertebral, basilar, M1 MCA requires 80-g force temporary clips⁶.

(a) Hunt and Hess grade-

- Unruptured Aneurysm -0
- Asymptomatic or minimal headache and slight nuchal rigidity -1
- Moderate to severe headache, nuchal rigidity, no neurological deficit other than cranial nerve palsy. -2
- Drowsiness, confusion, mild focal deficit. -3
- Stupor, moderate to severe hemiparesis, possibly early decerebrate rigidity and vegetative disturbances -4
- Deep coma, decerebrate rigidity, moribund appearance -5

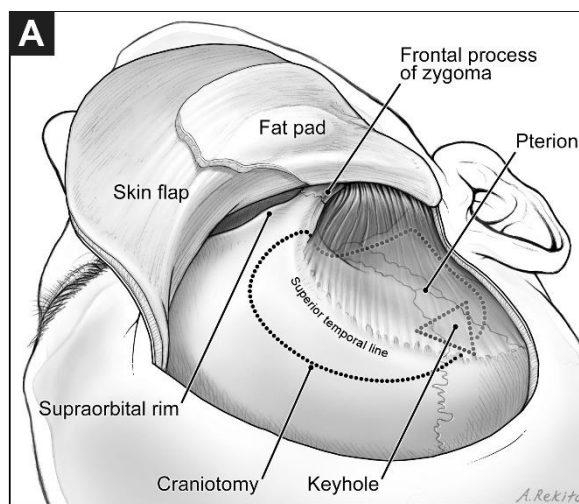
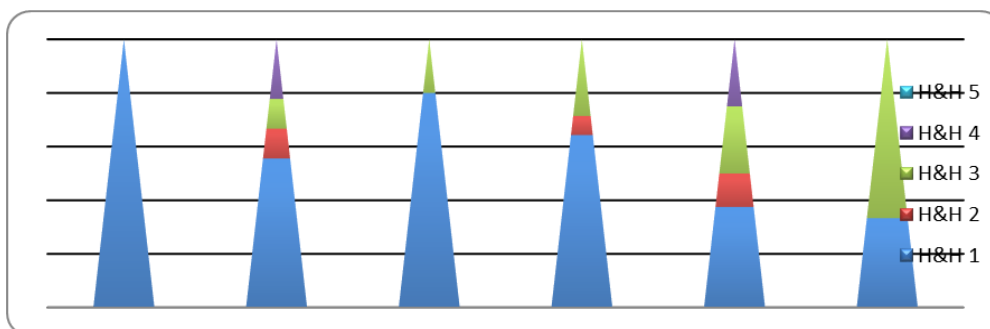


Table 1: Age v/s Hunt & Hess grade at admission

Age	H&H 1	H&H 2	H&H 3	H&H 4	H&H 5	Total
Age 15-	01	00	00	00	00	01
Age 26-35	05	01	01	02	00	09
Age 36-45	08	00	02	00	00	10
Age 46-55	09	01	04	00	00	14
Age 56-65	03	01	02	02	00	08
Age 66-75	01	00	02	00	00	03
Total	27	03	11	04	00	45

Data was available for 45 patients taken in the study. 27 patients were in H&H grade 1 at admission, 3 patients were in grade 2, 11 were in grade 3, 4 patients were in grade 4 and no patients were in grade 5. Most common age group was 46-55 years which included 14 patients. Mean age group in our study was 50 years. 24 patients were in age group 36-55 years. 11 patients were included in age group above 55 years. Only 1 patient was in age group of 15-25 years.

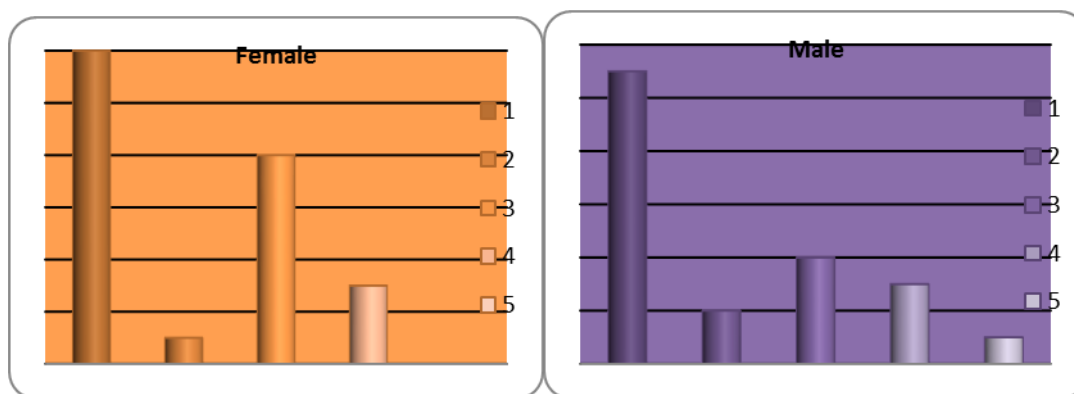


Age v/s Hunt&Hess at admission

Table2: Distribution of patients according to WFNS grading on admission in accordance with age.

WFNS GRADING	Total	Male	Female
1(n=23)	23	11	12
2(n=3)	03	02	01
3(n=12)	12	04	08
4(n=6)	06	03	03
5(n=1)	01	01	00
Total	45	21	24

Data was available for 45 patients in accordance with WFNS grading of patients at the time of presentation. It was seen that 23 patients were in WFNS grade 1 at admission and among them 11 were male and 12 were female. 7 patients were in WFNS grade 4 and 5 at admission and among them 4 were male and 3 were female. 12 patients were in WFNS grade 3 at admission and among them 8 patients were female and 4 were male.

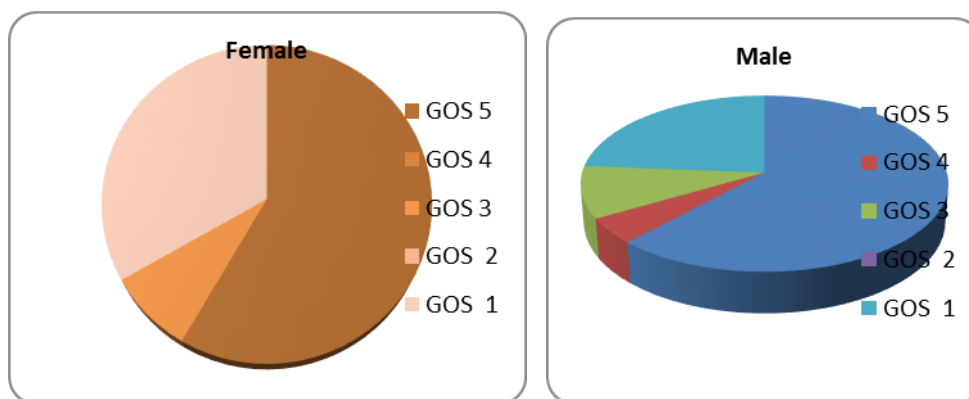


WFNS grading v/s Relation

Table 3: Sex v/s Outcome

Sex	Glasgow outcome scale					Total
	GOS 5	GOS 4	GOS 3	GOS 2	GOS 1	
Male(n=21)	13	01	02	00	05	21
Female(n=24)	14	00	02	00	08	24
Total	27	01	04	00	13	45

Data was available for 45 patients for analysis of sex v/s outcome. 21 patients were male in the series while 24 were female. Out of 21 male patients, 14 patients were in GOS of 4 and 5 after clipping while 5 patients died. Among 24 female patients, 14 patients were in GOS of 4 and 5 while 8 patients died after their surgery. Thus outcome was nearly equal in both sexes.



Sex v/s outcome

Glasgow Outcome Scale:

* Good Recovery- Resumption of normal life despite minor deficit. -5

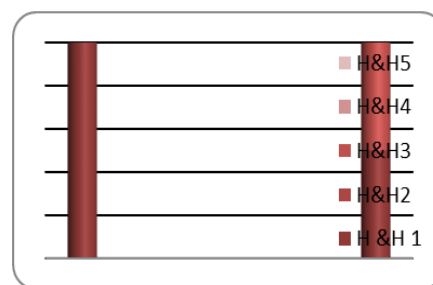
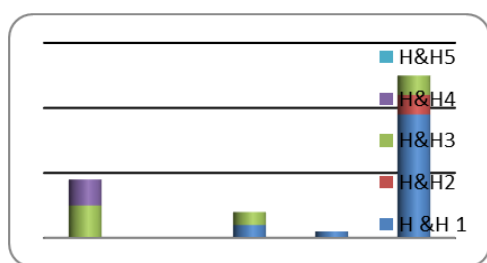
* Moderate Disability (disabled but independent)-Travel by public transportation, can work in sheltered setting-4

- * Severe disability (conscious but disabled)-dependent for daily support.-3
- * Persistent vegetative state-unresponsive and speechless; after 2-3weeks, may open eyes and have sleep/wake cycles-2.
- * Death -1

Table 4: Temporary Clipping, H&H grade and cross tabulation with Glasgow Outcome Scale.

			Glasgow Outcome Scale(GOS)					Total
Temporary Clipping			1	2	3	4	5	
Yes	H&H At admission	1	00	00	02	01	19	22
		2	00	00	00	00	03	03
		3	05	00	02	00	03	10
		4	04	00	00	00	00	04
		5	00	00	00	00	00	00
	Total	09	00	04	01	25	39	
No	H&H At admission	1	04	00	00	00	01	05
		2	00	00	00	00	00	00
		3	00	00	00	00	01	01
		4	00	00	00	00	00	00
		5	00	00	00	00	00	00
	Total	04	00	00	00	02	06	

In this series of 45 patients, temporary clipping was used in 39. In those in whom temporary clipping was used, GOS of 4 and 5 was seen in 26 while 9 patients died. All 4 patients died in those with H&H grade 4 and 5 on admission and in whom temporary clipping was used. Out of 10 with grade 3 H&H at presentation, 5(50%) died with no mortality in grade 1 and 2 H&H. Temporary clipping was not used in 6 patients and among them 2 survived with GOS of 4 and 5 while 4 died.



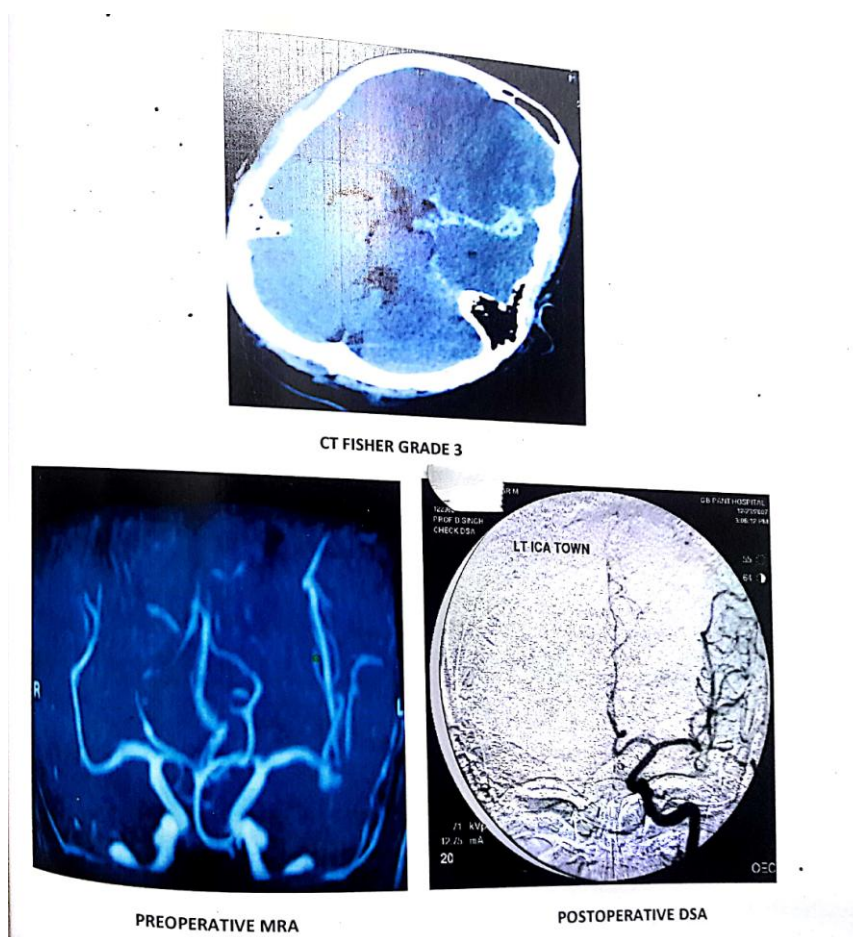
IV. Discussion

Middle Cerebral artery aneurysm is the third most common intracranial aneurysms. In our series, most common age group was 46-55 years which included 14 patients. Mean age group in our study was 50 years. 24 patients were in age group 36-55 years. Total numbers of aneurysms were 52 due to the fact that 7 patients had two aneurysms. Proximal MCA aneurysms were seen in 9(18%) patients; bifurcation/trifurcation aneurysms were seen in 38(73%) patients and distal MCA aneurysm in 5(9.6%) patient. Mirror image aneurysm was seen in 5 cases. Single MCA aneurysms were seen in 38(84.4%) and multiple in 7(15.5%) of patients. Pure mirror image MCA aneurysms were seen in 5(11.1%) patients and all were situated at bifurcation. 12 aneurysms were small sized (2-7mm); 27 aneurysms were medium sized; 12 aneurysms were large (15-25mm) sized and 1(1.92%) was giant aneurysm. Headache was seen in 43, vomiting in 30, loss of consciousness in 18(40%). Meningism was seen in nearly all patients and altered sensorium in 7. Other symptoms and signs like seizures, hemiparesis and aphasia were seen in 15. Temporary vascular occlusion was used in 66(35%) patients during aneurysmal surgery. Out of this, 16(8.6%) patients with middle cerebral artery aneurysms required temporary arterial occlusion during their operation. Occlusion time ranged from 1.5min to 40 min⁵¹. Temporary clipping was used in 39(86%). Median temporary clipping time was 6 min. Out of 10 patients with grade 3 H&H at presentation, 5(50%) died with no mortality in grade 1 and 2 H&H. All 4 patients died in those with H&H grade 4 and 5 on admission and in whom temporary clipping was used. One patient was operated on the basis of MRA due to non availability of DSA machine. In 44(97.7%) patients DSA could well elucidate the site, size, shape and direction of aneurysm and also the associated vasospasm. Check DSA was performed in 15(33.3%) patients only and complete occlusion was achieved in all. In rest 30(66.6%), check DSA could not be performed either due to lost follow up (12 patients who were called but did not turn up in spite of repeated correspondence/telephone) or death after operation (13 patients). 5 patients did not give consent for check angiogram. 20(74%) showed good recovery (GOS of 4 and 5) while 4(15%) died in patients with grade 1H&H. The outcome in 1(25%) showed good recovery while 3(75%) died in grade 4 and 5 H&H. In the whole series,

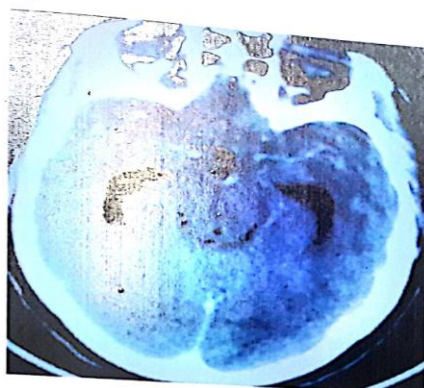
Glasgow Outcome Scale of 4 and 5 was seen in 28(62.2%) patients while 13 (28.8%) patients died with 21% mortality in grade 1 and 59% in grade 3 WFNS. Outcome was good (GOS of 4 and 5) ranging from 44% in proximal to 60.5% in bifurcation /trifurcation aneurysm and 80% in distal MCA aneurysm. There was 8.33% mortality in small sized aneurysms; 37% in medium sized; 25% in large sized and 100% in giant aneurysm. The most common cause of death in patients in our series was severe subarachnoid hemorrhage, Rebleeding and associated vasospasm which comes out to be 8(61.5%) of total death. 28(62.2%) had good recovery while 13(28.8%) died.

V. Conclusion

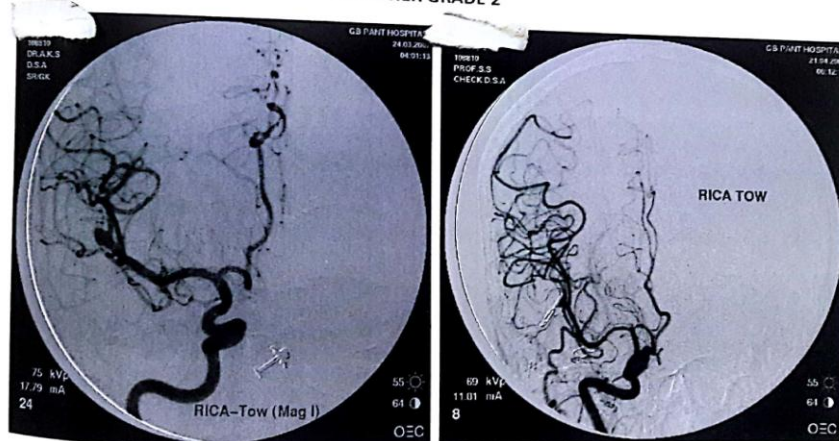
To conclude, patients presenting with poorer Hunt and Hess grade, World Federation of Neurological Surgeons grade and Fisher grade on admission has poor outcome. Post operative check cerebral angiography is a good tool of assessing the effectiveness of clipping and distal cerebral circulation. The surgical outcome of our series is comparable to various international series.



49 YEAR MALE, ADMITTED WITH FISCHER GRADE 3 , H AND HESS GRADE 1, WFNS GRADE 1. ON DSA LEFT MCA TRIFURCATION SMALL SIZE ANEURYSM DIRECTED ANTERO SUP., CLIPPING DONE. POSTOP GCS 5 ANS MRS 0. CHECK DSA – REVEALED NO ANEURYSM



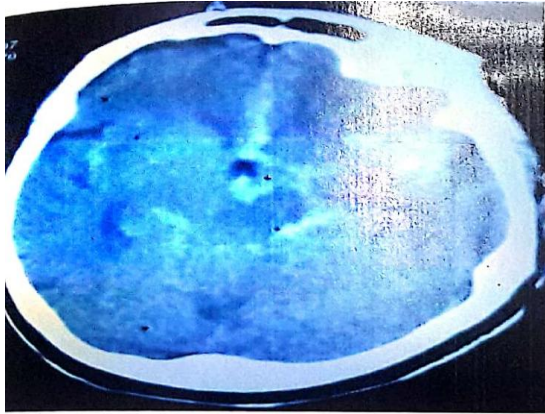
CT FISHER GRADE 2



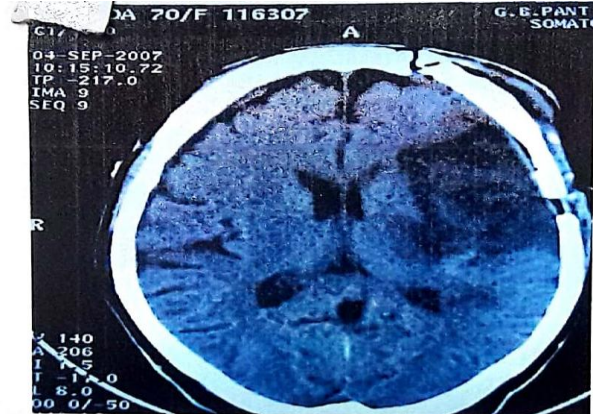
PREOPERATIVE DSA

POSTOPERATIVE DSA

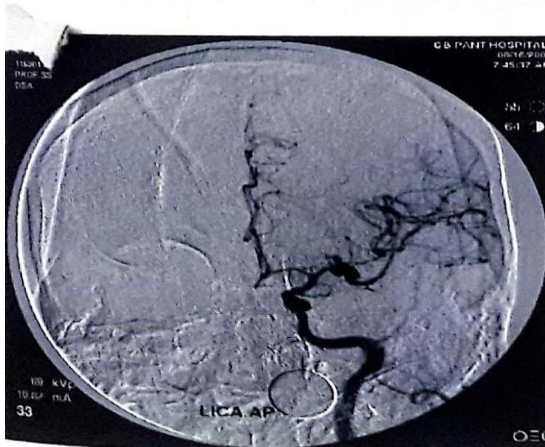45 YEAR MALE WITH FISHER GRADE 2, H AND HESS 1, WFNS-1. DSA-REVEALED TWO MCA ANEURYSM SMALL SIZED. (1) 4X5 MM AT BIFURCATION, (2) 4X4MM AT M2 . CLIPPING DONE. POSTOP GOS WAS 3 ANS MRS 0. CHECK ANGIO REVEALED NO ANEURYSM.



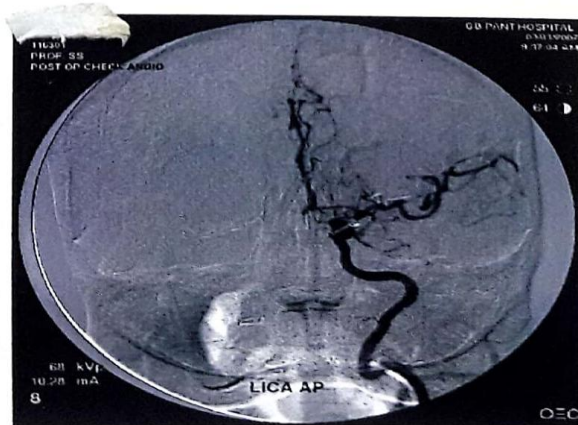
CT SCAN (FISHER GRADE-4)



POSTOPERATIVE CT SCAN

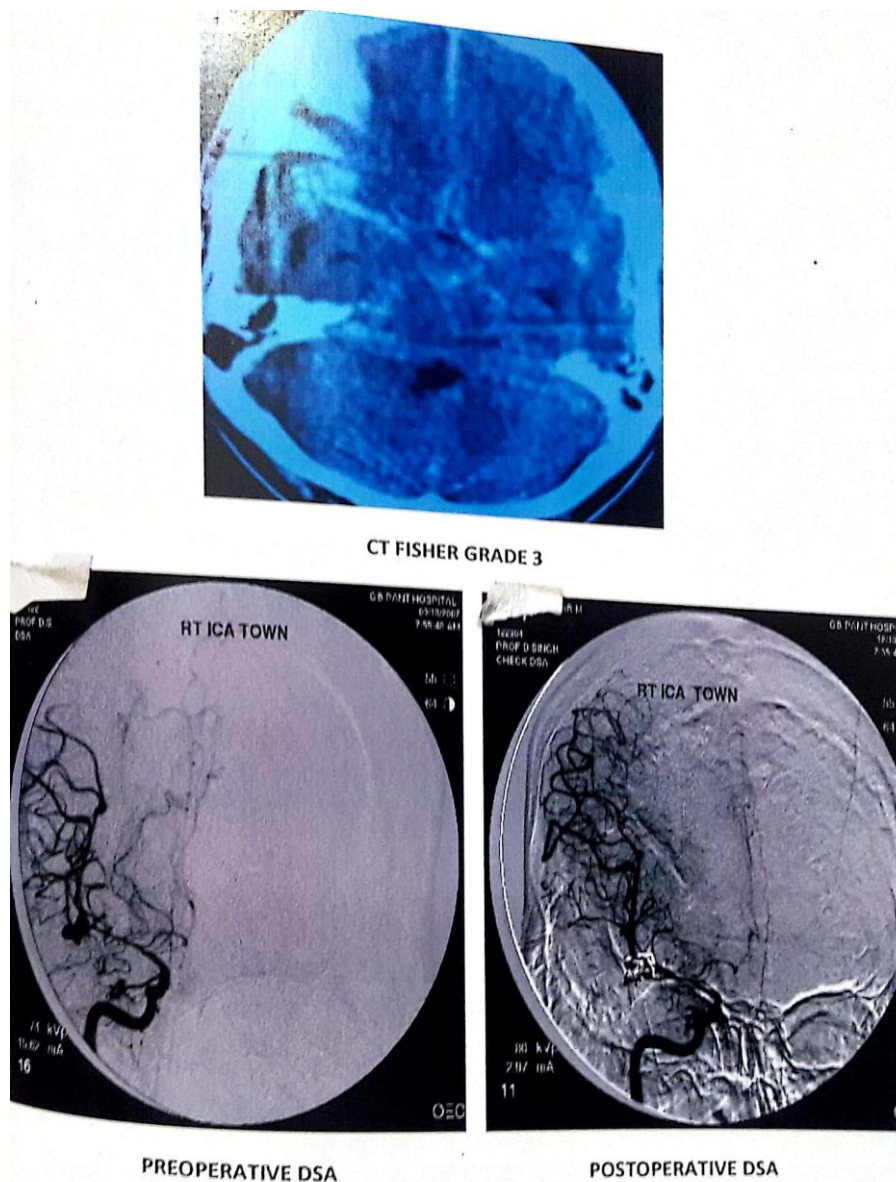


PREOPERATIVE DSA



POSTOPERATIVE CHECK DSA

70 YEAR MALE WITH FISHER GRADE 4, HUNT AND HESS-3 AND WFNS-4. DSA REVEALED LEFT MCA BIFURCATION 8.6X5.3MM DIRECTED ANTERO-INF-LATERALLY. CLIPPING. POST OP GOS-3 AND MRS-5. CHECK ANGIO –NO ANEURYSM



38 YEAR MALE WITH FISHER GRADE -3, HUNT AND HESS-1, WFNS-1, DSA REVEALED RIGHT MCA BIFURCATION 20X14 MM ANEURYSM DIRECTED ANTERO-SUPERO-LATERALLY. CLIPPING DONE, POST-OP GOS-5 AND MRS-0. CHECK DSA REVEALED NO RESIDUAL ANEURYSM OR NECK

References

- [1]. Roberto C, Michael JF: Surgical Management of Middle Cerebral Artery Aneurysms. Neurosurgery 48 No 4: April 2001.
- [2]. Rinne J, Hernesniemi J, Niskanen M, Valapathi M: Analysis of 561 patients with 690 middle cerebral artery aneurysms: Anatomic and clinical features as correlated to management outcome. Neurosurgery 38: 2-11, 1996.
- [3]. Ronkainen J: Familial subarachnoid hemorrhage in East Finland 1977-1990. Neurosurgery 33:787-797, 1993.
- [4]. Juvela S, Porras M, Poussa K: Natural history of unruptured intracranial aneurysm: Risks for aneurysm formation, growth and rupture. Acta Neurochirurgica (supp.)87:27-30, 2002.
- [5]. B.G. Shin, Kim JS, Hong SC: Single stage operation for bilateral middle cerebral artery aneurysm. Acta Neurochirurgica 147:33-38, 2005.
- [6]. Fandy T, Charbel, Auman JI, Diaz FG, Malik GM, Dujovny M, Sanders J: Temporary clipping in aneurysm surgery: Technique and result: Surgical Neurology, 36:83-90, 1991.
- [7]. Rorberto C, Heros, Michael J, Fritch: Surgical management of middle cerebral artery aneurysms. Neurosurgery 48, No.4: April 2001.
- [8]. Michael Bruce Horowitz, Howard Y, Charles J: Management of giant middle cerebral artery fusiform serpentine aneurysm with distal clip application and retrograde thrombosis. Surgical Neurology 41:221-225, 1994.
- [9]. Robert L. Masson, Arthur LD: Aneurysmal intracerebral haemorrhage. Neurosurgery clinic of North America 3, No. 3: July 1992.
- [10]. Day AL: Aneurysm of the ophthalmic segment: A clinical and anatomic analysis. J. Neurosurgery 72:677-691, 1990.
- [11]. Courville CB: Intracranial lesions secondary to congenital (saccular) aneurysm. Bulletin of Los Angeles Neurological Society 30:1-21, 1965.

- [12]. Mohr G, Ferguson G, Khan M: Intraventricular haemorrhage from ruptured aneurysm: Retrospective analysis of 91 cases. *Journal of Neurosurgery* 58:482-487, 1983.
- [13]. Pai S Balaji, Varma RG, Kulkarni RN: Microsurgical Anatomy of MCA Cadaveric brain specimen. *Neurology India* 53:186-190, 2005.
- [14]. Paulo Henrique Pires de Aguiar, Pedro ASJ, Alexandros TP, Marcos VC, Joel AT, Renata S: Middle Cerebral Artery Aneurysm: Challenges for microsurgical Approach. Santa Paula Hospital, Sau Paulo, Brazil, 2008.
- [15]. Kaplan HA: The lateral perforating branches of the anterior and middle cerebral arteries. *Journal of Neurosurgery* 23:305-310, 1965.
- [16]. Rhoton AL, Saeki N, Perlmutter D, Zeal A: Microsurgical anatomy of common aneurysm sites. *Clinical Neurosurgery* 26: 248-306, 1979.
- [17]. Grand W: Microsurgical anatomy of the proximal middle cerebral artery and internal carotid bifurcation. *Neurosurgery* 7:215-218, 1980.
- [18]. Herman LH, Ostrowsk AZ, Gurjian ES: Perforating branches of the middle cerebral artery. *Arch Neurology* 8:32-34, 1963.
- [19]. Lang J, Dehling U: Cerebri media, Abganzonen und Weiten ihrer Ramicorticales. *Acta Anatomy* 108:419-429, 1980.
- [20]. Jain KK : Aberrant roots of the abducent nerve. *Journal of Neurosurgery* 21:349-351, 1964.
- [21]. Umansky F, Francisco BG, Manuel D, Fernando G, Diaz, and James IA: The perforating branches of middle cerebral artery: A microanatomical study. *Journal of Neurosurg* 62:261-268, 1985.
- [22]. Douglas Chyatte, Rebecca P: Nuances of middle cerebral artery aneurysm microneurosurgery. *Neurosurgery* 48, No.2: 339-344, 2001.
- [23]. Ogilvy CS, Crowell RM, Heros RC: Surgical management of middle cerebral artery aneurysm: Experience with transsylvian and superior temporal gyrus approaches. *Surgical Neurology* 43: 15-24, 1995.
- [24]. Michael Bruce Horowitz, Howard Y, Charles J: Management of a giant middle cerebral artery fusiform serpentine aneurysm with distal clip application and retrograde thrombolysis. *Surgical Neurology* 41:221-225, 1994.
- [25]. Hyeon Chul Ryu, Jun –Seob Lim, Kyo-Yong C, Seung-Kyu P, Nam-Gu K, Hong-Jeon J, Young-Cheol O: Effect of continous external ventricular drainage on delayed ischemic neurological deficit after aneurysmal clipping in spontaneous SAH. *Journal of Korean Neurosurgery Society* 41:95-99, 2007.
- [26]. Neal F.Kassell, James C, Torner, Clarke H, John AJ: International cooperative study on the timing of aneurysmal surgery. *Neurosurgery* 73:18-45, 1990.
- [27]. Paul K J, John RWK, Joel DM, and Richard HS: Marked reduction of cerebral vasospasm with lumbar drainage of CSF after SAH. *Journal of Neurosurgery* 100: 215-224, 2004.
- [28]. R.Loch Macdonald, Marcus S, Bryce M: Intracranial Aneurysm. *Neurosurgery Quarterly* 11: No 3, 2001.
- [29]. Abderrezak Zouaoui, Mokrane Sahel, Beatrice, Stephane C, Nafissa D, Ahmed B, Thierry F: Three-dimensional Computed Tomographic Angiography in detection of Cerebral Aneurysms in Acute Subarachnoid Hemorrhage. *Neurosurgery* 41: 125, July 1997.
- [30]. Shiro Nagasawa, Tomio O, Eimei T: Magnetic Resonance Angiographic Source Images for Depicting Topography and Surgical Planning for Middle Cerebral Artery Aneurysms: Technique Application. *Surgical Neurology* 50:62-64, 1998.
- [31]. Huston J: Blinded prospective evaluation of sensitivity of MR angiography to known intracranial aneurysm size. *AJNR Am Neuroradiology* 15: 1607-1614, 1994.
- [32]. Ender Uysal, Ban Yanbulo, Mehmet E, Bekir MK, Muzaffer B: Diagnostic and Interventional Radiology. *Official Journal of the Turkish Society of Radiology*: 2004.
- [33]. Toshinori Hirai, Kukunori K, Ken O, Yuka M, Kenji S, Toshio O, Shozoaburo U, Mutsumasa T: Preoperative Evaluation of Intracranial Aneurysms: Usefulness of Intraarterial 3D CT Angiography and Conventional Angiography with a Combined Unit. *Radiology* 220:499 -505, 2001.
- [34]. Heiserman JE, Dean BL, Hodak JA: Neurological complication of cerebral angiography. *AJNR Annals of Neuroradiology* 15: 1401-1411, 1994.
- [35]. J.Pablo Villaslanca, Parizad H, Neil M, Reza J, Gary D, Sylvester L, John F, Pierre G: Three dimensional helical CT angiography in the diagnosis, characterization, and management of middle cerebral artery aneurysm: Comparison with conventional angiography and intraoperative finding. *Journal of Neurosurgery* 97: 1322-1332, 2002.
- [36]. Deon FL, Wilson TA, Garnette RS: Brief history of aneurysm clips. *Neurosurgery Focus* 11(2): Article 4, August 2001.
- [37]. Dandy WE: Intracranial aneurysm of internal carotid artery cured by operation. *Annals of Surgery* 107: 654, 1938.
- [38]. Dott NM: Intracranial aneurysms: Cerebral arteriography: Surgical treatment. *Edinburg Medicine Journal* 40: 219, 1933.
- [39]. Heifetz MD: A new intracranial aneurysm clip. *Journal of Neurosurgery* 30: 753, 1969.
- [40]. Mayfield FH, Kees GJ: A brief history of the development of Mayfield clips: Technical note. *Journal of Neurosurgery* 35:97-100, 1971.
- [41]. Macfadden JT: The origin and evolutionary principles of spring forceps. *Surgery Gynae and Obstetrics* 130:356-368, 1970.
- [42]. Yasargil MG, Vise WM, Bander DC: Technical adjuncts in neurosurgery. *Surgical Neurology* 8:331-336, 1977.
- [43]. Fisher CM, Kistler JP, Davis JM: Relation of cerebral vasospasm to subarachnoid hemorrhage visualized by CT scanning. *Neurosurgery* 6:1-9, 1980.
- [44]. Bailes JE, Spetzler RF, Hadley MN, Baldwin HZ: Management of morbidity and mortality of poor grade aneurysm patients. *Journal Neurosurgery* 72:559-566, 1990.
- [45]. Vale FL, Bradley EL, Fisher WS: The relationship of subarachnoid hemorrhage and the need for postoperative shunting. *Neurosurgery* 86: 462-466, 1997.
- [46]. Kassell NF, James C, Torner, Clarke H, John AJ: International cooperative study on the timing of aneurysmal surgery: Overall management and result. *Journal of Neurosurgery* 73:18-36, 1990.
- [47]. Hart RG, Byer JA, Slaughter JR: Occurrence and implication of seizures in subarachnoid hemorrhage due to ruptured intracranial aneurysm. *Neurosurgery* 8: 417-421, 1981.
- [48]. Suzuki J, Yoshimoto T, Kayama T: Surgical treatment of middle cerebral artery aneurysms. *Journal of Neurosurgery* 61: 17-23, 1984.
- [49]. Pasztor E, Vajda J, Juhasz J, Toth S, Orosk E: The surgery of middle cerebral artery aneurysms. *Acta Neurochirurgica (Wien)* 82: 92-101, 1986.
- [50]. Yasargil MG: Middle Cerebral Artery Aneurysm: Microneurosurgery. Stuttgart, George Thieme Verlag 2, 124-164, 1984
- [51]. Anthony J, Lindsay S: Temporary Vascular Occlusion during Aneurysmal Surgery. *Surgical Neurology* 27, 47-63, 1987.
- [52]. 52.Mahmoud MT, Ichiro N, Toshio H, Yasushi I, Mitsutoshi I, Yoshihiko W: Endovascular embolization v/s surgical clipping in treatment of cerebral aneurysm: morbidity and mortality with short-term outcome. *Surgical Neurology* 66, 277-284, 2006.

- [53]. Hook O, Norlen G.: Aneurysms of middle cerebral artery. *Acta Chirurgica Scand(Suppl)* 235,1-39,1958.
- [54]. Tristan P.C, Albert, Bon HV, David JL: Treatment of giant middle cerebral artery aneurysms with a flow replacement bypass using laser-assisted non-occlusive technique. *Neurosurgery* 63, 12-22, 2008.
- [55]. Kristin ES, Philippe G, Gerald W, Rafael: Limitation of magnetic resonance imaging and magnetic resonance angiography in the diagnosis of intracranial aneurysms. *Neurosurgery* 63, 29-35,2008.
- [56]. Seung HL, Jae SB: Distal middle cerebral artery M4 aneurysm surgery using navigation-CT Angiography. *J Korean Neurosurgery Soc* 42, 478-480,2007.

Dr Pawan Garg "Clipping of Middle Cerebral Artery Aneurysm –A Review Of 45 Cases." *IOSR Journal of Dental and Medical Sciences (IOSR-JDMS)*, vol. 17, no. 4, 2018, pp 04-16.