

Fibroblastic Meningioma in an HIV Positive Woman

Vivian Kwaghe, Joseph Obande

Corresponding author: Vivian Kwaghe

Abstract: We Report A Case Of A 39- Year Old Hiv Positive Woman Who Presented With A History Of Focal Seizures Involving The Right Upper Limb With Progressive Weakness Of The Right Upper And Lower Limbs. A Presumptive Diagnosis Of Cerebral Toxoplasmosis Was Made And Patient Was Commenced Empirically On Double Dose Cotrimoxazole And Pyrimethamine. A Brain Ct Scan Showed A Huge Mass In The Left Frontal Lobe And A Histopathological Diagnosis Of Fibroblastic Meningioma Was Made. Patient Was On A Failed Art Regimen At The Time Of Development Of Symptoms.

Key- Words: Meningioma, Hiv Infection.

Date of Submission: 28-03-2018

Date of acceptance: 12-04-2018

I. Introduction

According To The Joint Unaids And Who Report Of 2015, 36.7 Million People Worldwide Are Living With Hiv; 70% Of Whom Live In Sub Saharan Africa [1]. Currently, Nigeria Has The Second Largest Number Of People Living With Hiv/Aids In The World [2]. The National Prevalence Is Estimated At 3.1% Among Adults [2].

Meningiomas Are A Diverse Set Of Tumors Arising From The Arachnoid Cap Cells In The Meninges. They Constitute About 30% Of All Brain Tumors With An Estimated Prevalence Of Approximately 97.5 In 100,000 In The United States [3]. The Prevalence Of Meningiomas In Nigeria Is Unknown, Mainly Due To Lack Of Data, But Also Unavailability Of Imaging Facilities In Most Of Our Hospitals; And The High Cost Of Such Facilities Where Available, Making Them Inaccessible To Most Patients. About 90% Of Meningiomas Are Benign In Nature.

The Loss Of Immune Function That Characterizes Hiv Infection Is Associated With The Development Of A Number Of Neoplastic Diseases Including Lymphomas, Kaposi Sarcoma, And Invasive Cervical Cancers [4]. The Commonest Brain Tumor Associated With Hiv Infection Is Primary Cns Lymphoma.

We Report The Case Of Meningioma In An Hiv Positive Woman Who Was On A Failed Art Regimen At The Time Of Diagnosis.

II. Case Report

A 39yr Old Nigerian Woman Who Had Been Positive For Hiv-1 For 8yrs Presented With A 2 Month History Of Partial Seizures Involving The Right Upper Limb, With Associated Progressive Weakness Of The Right Upper And Lower Limbs. There Was Associated Decline In Cognitive Function As Well As Urinary And Fecal Incontinence That Started One Week Prior To Presentation. She Had Been On Antiretrovirals Since She Was Found To Be Hiv-Positive With Poor Adherence. On Examination The Power On The Right Limbs Was 2/5, With Associated Oral Thrush. Her Cd4 Cell Count Was 66cells/MI, And The Viral Load Was 127,283 Copies/MI. She Was Commenced Empirically On Double Dose Cotrimoxazole And Pyrimethamine While Waiting For Patient To Source For Funds For Brain Ct Scan. She Was Also Switched To Second Line Arv's After Proper Adherence Counselling, As Well As Anticonvulsants. A Brain Ct Scan Done Two Weeks Later Showed A Large Hyper Dense Lesion In The Left Frontal Lobe With Density Of 49hu On Native Scan And 62hu After Contrast Administration With Associated Features Of Raised Intracranial Pressure. A Radiological Diagnosis Of Cns Lymphoma Was Made. A Consult Was Sent To A Neurosurgeon Who Reviewed The Patient And Performed A Left Craniotomy (Frontoparietotemporal) + Simpson Ii Excision With Duroplasty.

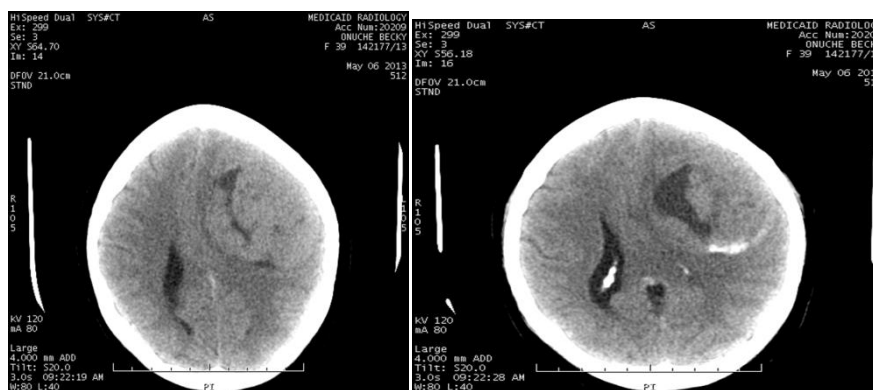


Figure 1

Figure 2

Histopathological Examination Revealed A Meningioma Of The Fibroblastic Variant. Patient Made Significant Improvement Post-Surgery And Was Discharged A Week Later.

III. Discussion

Hiv Infection Has Been Shown To Predispose To The Development Of Cancers. Four Cancers Have Been Classified As Aids-Defining; These Include Primary Cns Lymphoma And Other Forms Of Non-Hodgkin's Lymphoma, Kaposi Sarcoma And Cervical Cancer [5]. Other Types Of Cancer Are Also More Likely To Develop In People With Hiv Than In People Who Are Not Infected, Including:

- Anal Cancer
- Hodgkin Disease (Hodgkin Lymphoma)
- Melanoma Skin Cancer
- Liver Cancer
- Lung Cancer
- Mouth And Throat Cancers
- Testicular Cancer
- Squamous Cell And Basal Cell Skin Cancers.

The Loss Of Immune Function And Associated Opportunistic Infections By Viruses Such As The Epstein-Barr Virus, Human Herpes Virus 8 And Human Papilloma Virus Have Been Linked To The Development Of Cancers In People Infected With Hiv [6, 7, 8].

Meningiomas Are A Group Of Tumors That Arise From The Arachnoid Cap Cells In The Meninges. Even Though Hiv Infection Has Not Been Directly Linked To The Development Of Meningioma, Yingqun Tao Et Al Had Earlier Reported That The Hiv-Tat Protein Might Have A Close Relationship With Meningioma Pathogenesis And Malignancy [9]. Hiv Tat Proteins Are Potent Transcriptional Activator Proteins That May Lead To Mutations On Chromosome 22. The Most Frequent Genetic Mutations (~50%) Involved In Meningiomas Are Inactivation Mutations In The Neurofibromatosis 2 Gene (Merlin) On Chromosome 22q [9].

Meningiomas Occur Frequently In Middle-Aged Women (50-55years). We Report A Case Of Meningioma In A 39 Year Woman, Suggesting That In The Setting Of Hiv Infection Meningiomas May Occur At A Younger Age. In 2010, Moataz Et Al Reported A Case Of Meningioma In A 25 Year Old Hiv Positive Man [10]; And In 1999, Khurshid Et Al Reported Four Cases Of Meningioma In Hiv Positive Men With A Mean Age Of 40 [11].

The Cd4 Cell Count At The Time Of Diagnosis For This Case Was 66 Cells/MI, An Indication Of Advanced Hiv Infection. Of The Four Cases Reported By Khurshid Et Al, Three Had Cd4 Cell Counts Less Than 100. This May Suggest The Fact That Patients With Advanced Hiv Infection Are More At Risk Of Developing Cancers Including Meningiomas.

In Sub-Saharan Africa Where Imaging Techniques Are Lacking In Most Facilities, Hiv Patients Presenting With Focal Neurologic Deficits With Seizures Are Empirically Treated For Cerebral Toxoplasmosis. Response To Treatment As Evident By Improvement In Motor Function Is Most Often Used To Confirm The Diagnosis. This Patient Showed No Improvement In Motor Function With The Empiric Treatment For Toxoplasmosis. Clinicians Practicing In Sub-Saharan Africa Should Think Of An Alternative Diagnosis, Possibly Meningioma, When Managing Hiv Patients Presenting With Focal Neurologic Deficits And Seizures, And In Whom Empiric Treatment For Toxoplasmosis Is Not Showing Any Improvement In Motor Function.

The Importance Of Neuro- Imaging In The Management Of Hiv/Aids Patients With Neurological Manifestation Cannot Be Over Emphasized. Cases Of Meningiomas And Other Forms Of Neuro-Aids Have Been Missed Due To Lack Of Neuro-Imaging In Most Facilities In Sub Saharan Africa Where 70% Of Cases Of

Hiv/Aids Live. Governments Of These Countries Should Make Every Effort To Provide Such Facilities So As To Improve The Care Of People Living With Hiv/Aids.

In Summary, We Present A Case Of Meningioma In An Hiv Patient With Severe Immunosuppression. Hiv Infection Predisposes To The Development Of Tumors. Even Though Meningiomas Are Rare Tumors That Occur In The Elderly, In The Presence Of Hiv Infection Meningiomas May Occur In A Younger Age.

References

- [1] Unaided 2015 Global Report. <http://www.aidsdatahub.org/global-aids-response-progress-reporting-2015>.
- [2] United States Embassy In Nigeria. Nigeria Hiv/Aids Fact Sheet 2015. <http://photos.state.gov/libraries/nigeria/231771/public/december-hivfactsheet.pdf>.
- [3] Claus Eb, Bondy MI, Schildkraut Jm, Et Al. Epidemiology Of Intracranial Meningioma. *Neurosurgery* 2005; 57(6):1088-1095; Discussion 1088-1095.
- [4] Gunthel Cj, Northfelt Dw. Cancers Not Associated With Immunodeficiency In Hiv Infected Persons. *Oncology (Williston Park, N.Y)* 1994. 8 (7): 59-64; Discussion 64, 67-8, 70.
- [5] Hajjar M, Lacoste D, Brassard G Et Al. Non-Acquired Immune Deficiency Syndrome-Defining Malignancies In A Hospital-Based Cohort Of Human Immunodeficiency Virus Infected Patients: Bordeaux, France, 1985-1991. *J Natl Cancer Inst.* 1992; 84:1593-1595.
- [6] McClain Kl. Epstein-Barr Virus And Hiv-Aids Associated Diseases. *Biomed Pharmacother*: 2001 Sept; 55(7):348-52.
- [7] Corey Casper, Anna Wald, John S. Pauk, Et Al. Correlates Of Prevalent And Incident Kaposi's Sarcoma-Associated Herpes Virus Infection In Men Who Have Sex With Men. *The Journal Of Infectious Diseases*, 2002; 185:990-993.
- [8] Dimie Ogoina, Bolanle Olufunke Musa, Geoffrey Chukwubuike Onyemelukwe. Human Papilloma Virus (Hpv) Infection Is Associated With Hiv-1 Infection And Aids In Hiv-Infected Adult Patients From Zaria, Northern Nigeria. *Pan Afr Med J.* 2013; 15:38.
- [9] Tao Y, Wei Q, Xu Z, Bai R, Li Y, Luo C, Dong Y, Et Al. Holistic And Network Analysis Of Meningioma Pathogenesis And Malignancy. *Biofactors* 2006; 28(3-4):203-219.
- [10] Moataz A, Abdullah T, Oscar B Et Al. Atypical Meningioma In A Young Hiv Patient. *J Med Cases* • 2010;1(2):39-41.
- [11] Khurshid A, Joseph Jt, Rachlin J, Cooley Tp, Kleefeldj, Dezube Bj. Meningioma In Four Patients With Human Immunodeficiency Virus Infection. *Mayo Clin Proc* 1999;74(3):253-257.

Vivian Kwaghe "Fibroblastic Meningioma in an Hiv Positive Woman" *IOSR Journal of Dental and Medical Sciences (IOSR-JDMS)*, vol. 17, no. 4, 2018, pp 01-03.