

Post Traumatic Phakic Lens Herniation – A Rare Case Report

Dr Rashmi kumar¹, Dr Bhawesh Chandra Saha², Dr. Bibhuti Prasanna Sinha³,
Dr Nilesh Mohan⁴, .Dr.Santosh Thakur⁵

¹Senior Resident, RIO, IGIMS, Patna

²Senior Resident, AIIMS, Patna

³Professor And HOD, RIO, IGIMS, Patna

⁴Additional Professor, RIO, IGIMS, Patna

⁵DNB Std., RIO, IGIMS, Patna

Corresponding Author: Dr. Bhawesh Chandra saha

Abstract: Blunt Trauma Can Result In Indirect Scleral Rupture With Subsequent Dislocation Of The Crystalline Lens In The Subconjunctival Or Subtenon Space. There Are Evidences That Timely And Effective Intervention Can Ensure Good Visual Recovery. Blunt Trauma Has Protean Ocular Manifestations With Phacocoele Being A Rare Event, Resulting From Indirect Scleral Rupture Of The Globe. The Eye Has Been Described To Behave Like An Incompressible Sphere Because Of Its Liquid Contents. Hence, Blunt Trauma Of Sufficient Magnitude Can Result In Rupture Of The Eyeball Either At The Site Of Impact (Direct) Or In A Remote Area (Indirect). This Indirect Rupture Of Sclera Leads To Dislocation Of The Crystalline Lens Into The Subconjunctival Or Subtenon Space. We Report A Case With Traumatic Phacocoele With An Aim To Evaluate The Clinical Presentation, Management And Visual Outcome.

Keywords: Blunt Trauma, Phacocoele, Scleral Rupture

Date of Submission: 28-03-2018

Date of acceptance: 12-04-2018

I. Case Report

A 55 Years Old Woman Presented With Complaint Of Sudden Profound Diminution Of Vision In Her Left Eye Since Last Night Following Trauma With Fist Due To Domestic Violence. On Ocular Examination, Visual Acuity Was Unaided 6/6 ;N12 In RE And PL (+), PR Inaccurate In LE. Mild Ptosis Was Present In LE Due To Lid Edema. Pupil Was Well Reacting In RE But Dilated And Fixed In LE. (Fig.1)

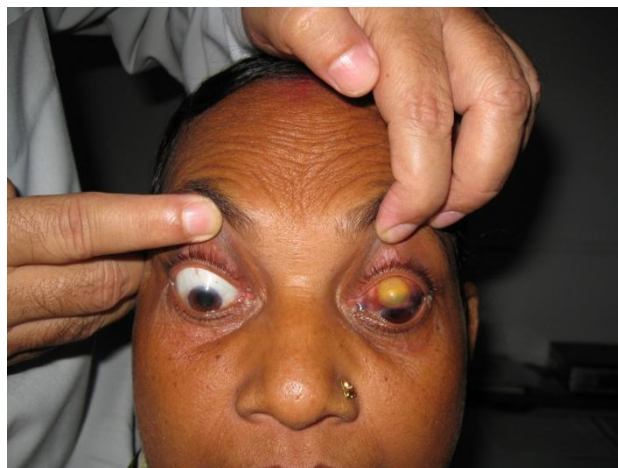

Fig 1. Gross External Examination Of The Eyes

On Slit Lamp Examination RE Was Within Normal Limits But LE Showed Presence Of A Well-Delineated Subconjunctival Mass along with A Superior Iris Defect (Figure 2,3). Anterior Chamber was deep and filled with Blood And Inflammatory Debris. Bulbar Conjunctiva And Cornea were Intact. Patellar Fossa Was Empty.

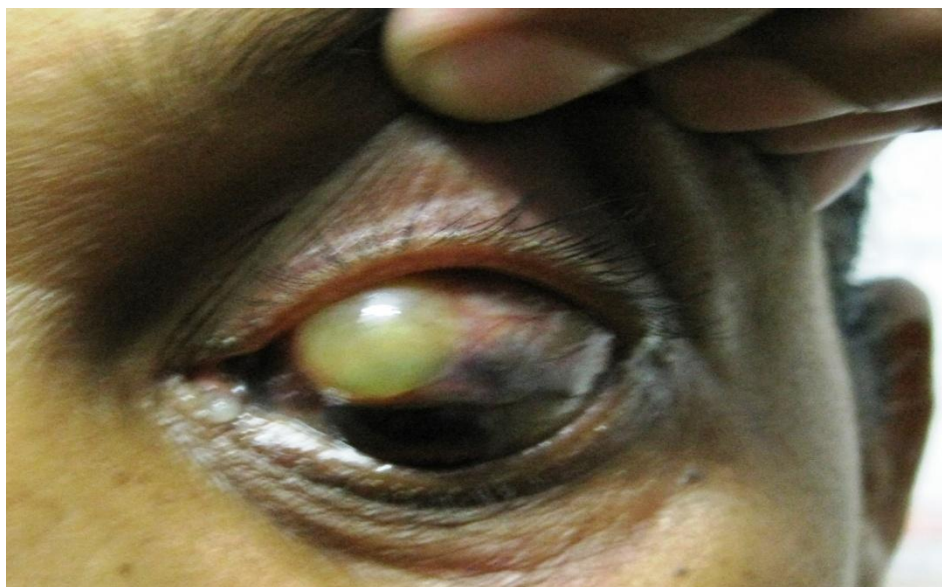


Fig 2.Slit Lamp Examination Of LE

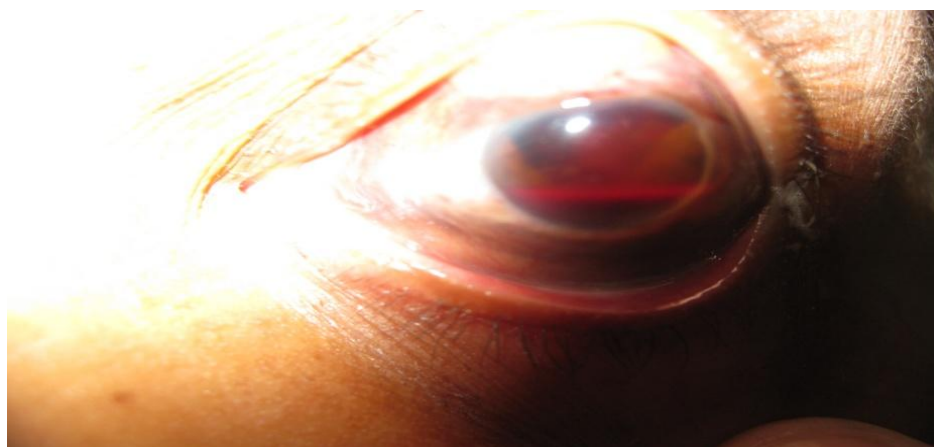


Fig 3.Slit Lamp Examination Of LE

Detailed Slit-Lamp Biomicroscopic Examination Revealed Normal Fundus In RE With Poor Fundal Glow In LE. Gentle B-Scan Ultrasonography Of LE Showed Absent Lens Echoes With Low To Moderate Amplitude Echoes In The Vitreous Cavity Suggestive Of Vitreous Haemorrhage. There Was No History Of Any Previous Intra Ocular Surgery.

A Clinical Diagnosis Of Occult Scleral Perforation With Uveal Prolapse And Dislocation Of The Crystalline Lens Was Made.

Exploration And Surgical Repair Of Ruptured Sclera Along With Lens Removal And Anterior Vitrectomy Was Performed (Fig.4) .

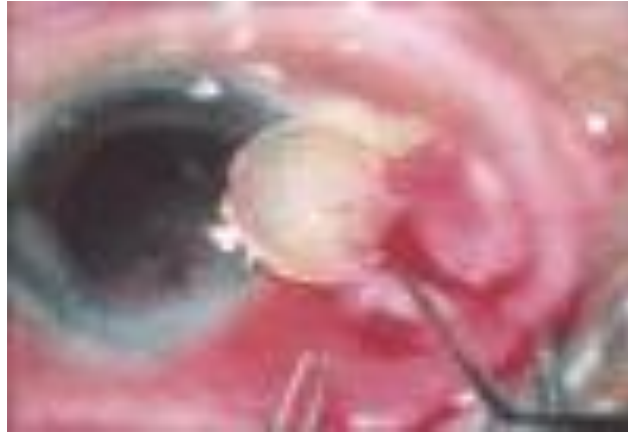

Fig 4. Surgical Removal Of The Dislocated Lens

The Decision Of Intraocular Lens Implantation With Scleral Fixation Was Done At The Time Of Surgery (Fig.5).

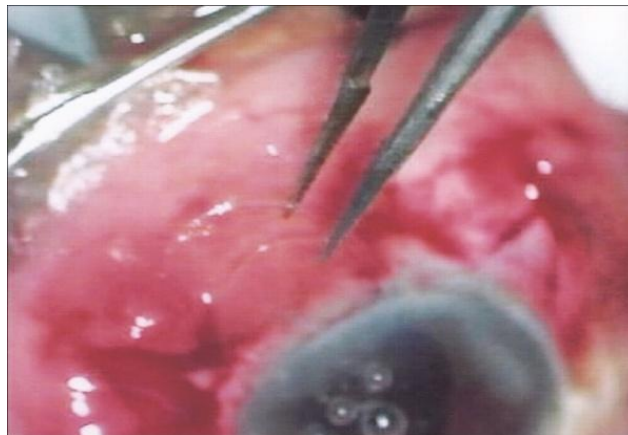


Fig.5 Implantation Of IOL

Visual Acuity On First Post Operative Day Was 2/60 Which Improved To 6/60 Unaided At One Month And BCVA Of 6/18 At 3 Months.

II. Discussion

Phac•O•Cele (Fak'ō-Sēl) Literally Implies Hernia Of The Lens Of The Eye Through The Sclera. [Phaco- + G. *Kēlē*, Hernia]. Most Cases Of Phacocoele Are Associated With Blunt Trauma, Existence Of Scleral Rigidity, Hard Crystalline Lens, And A History Of Scleral Surgery.

Phacocoele Has Been Reported To Comprise 13% Of All Lens Luxations.^{1,2} It Was First Reported By Fejér In 1928.³ The Predominant Site Of Indirect Scleral Rupture Is The Superonasal Quadrant⁴ Followed By The Superotemporal Quadrant.¹ The Scleral Rupture Frequently Occurs Between The Limbus And. Spiral Of Tillaux.¹

In The Present Case, Phacocoele Was In The Superior Quadrant. However, Charan And Mathur⁶ Reported Inferior Displacement And Krámar *Et Al.*⁷ Reported Superotemporal Displacement Of Lens Following Blunt Trauma. Subconjunctival Luxation Of Crystalline Lens Is Very Rare In Children Due To Elasticity Of Outer Coats Of The Globe And Softer Crystalline Lens. Indirect Ophthalmoscopy And Posterior Segment Ultrasound Can Not Localize The Lens However, Anterior Segment Oct Can Localize A Heterogeneous Reflecting Body In The Area Of The Swelling, Suggesting A Possible Phacocoele .

In Conclusion We Would Like To Emphasize That Though The Most Common Victims Of Blunt Trauma Are Young Individuals, Phacocoele Is Seen Much More Frequently At A Later Age Because Of The Increased Scleral Rigidity And Hard Crystalline Lens. This Study Provides Evidence That Timely And Effective Intervention Can Ensure Good Visual Recovery.

References;

- [1] Cherry Pm. Indirect Traumatic Rupture Of The Globe. Arch Ophthalmol. 1978;96:252–6.
- [2] Mcdonald Pr, Purnell Je. The Dislocated Lens. Jama. 1951;145:220–6.
- [3] Fejér Aj. Subconjunctival Lens Dislocation. Am J Ophthalmol. 1928;11:254–6.
- [4] Lister W. Some Concussion Changes Met With In Military Practice. Br J Ophthalmol. 1924;8:305–18.
- [5] Yurdakul Ns, Ugurlu S, Yilmaz A, Maden A. Traumatic Subconjunctival Crystalline Lens Dislocation. J Cataract Refract Surg. 2003;29:2407–10.
- [6] Charan H, Mathur Gb. Subconjunctival Dislocation Of Lens: A Case Report. Int Surg. 1969;52:115–6.
- [7] Krámar Po, Brandt De. Subconjunctival Dislocation Of The Lens. Arch Ophthalmol. 1976;94:110–1.

Dr.Rashmi Kumari"Post Traumatic Phakic Lens Herniation – A Rare Case Report"IOSR
Journal of Dental and Medical Sciences (IOSR-JDMS), vol. 17, no. 4, 2018, pp 74-77.