

Immediate Loading of Implants in the Partially Edentulous Maxilla: A Case Report of a Novel Technique with Strategic Implants

Vivek Gaur¹, Anita Doshi², Stefan Ihde³, Gabriela Fernandes⁴, Valeri Lysenko⁵

¹ Private dental practice, Etah, Uttar Pradesh, India

² Prosthodontist, Private dental practice, Mumbai, Maharashtra, India

³ Head of Dental Implants Faculty, International Implant Foundation, Munich, Germany

⁴ Department of Oral Biology, UB School of Dental Medicine, SUNY Buffalo, Buffalo, New York, USA

⁵ Associate Professor, Head of Department, Department of Dentistry and Oral and Maxillofacial Surgery, Kharkiv Medical Academy of Postgraduate education, Kharkiv, Ukraine

Corresponding author: Vivek Gaur

Abstract: Recently the technology of the Strategic Implant[®] has gained popularity worldwide, owing to its unique horizontal retention design that functions by getting engaged into the basal (2nd or 3rd) cortical bone, thus allowing it to be placed even in those cases, where the vertical bone supply is reduced such as moderate to severe or even ultimately resorbed ridges. The aim of this paper is to present the clinical application of a new, smooth surfaced single-piece bi-cortical screw implants (with multiunit abutment) with immediate loading protocol to restore partially edentulous distal maxilla without sinus lift procedure. Here, we report the case of a 50-year-old, healthy female patient with a history of bilaterally missing maxillary posterior teeth. We restored the premolars and molars with fixed screw retained prosthesis within 72 hours of flapless cortical screw implants placement (comprising multi-unit abutment heads).

Key-words: Strategic Implant[®], immediate functional loading, single-piece dental implants, cortical implantology,

Date of Submission: 08-05-2018

Date of acceptance: 25-05-2018

I. Introduction

Crestal implants (i.e. implants inserted from the top of the alveolar crest into the bone such as cylinders, screws and other types which are inserted into the jaw bones to stay in a defined relationship with the crestal, "1st" cortical) are indicated in situations where an adequate vertical bone supply is present. Although such crestal implants are dominating the implant market their success unfortunately depends on the stability of the 1st cortical, and they demand large amount of vertical bone. If such bone is missing various bone augmentation procedures become part of a treatment with crestal implant types¹. The principal problems of all these crestal implant systems are identical, although manufacturers of such implants frequently claim that "their" implant is superior to all others. Typically implantologists world-wide tend to change their "preferred implant system" as a result of those advertised claims, however after maximum a few years they change the system again, because they have seen that their hopes and the claims were not realized. Augmentations increase the overall costs of dental implant treatment as well as the number of necessary operations and thereby the risks. The primary treatment modality for the distal upper jaw is a sinus lift procedure with bone augmentation inside the maxillary sinus, done in order to increase bone height there. Typical complications are excessive bleeding, Schneiderian membrane perforation, post-operative infection on the oral side, (recurrent) sinusitis, loss of callus and augmentation, as well as donor site morbidity in case of autogenous grafting. All these complications as well as the additional costs lead to a situation where patients tend to avoid augmentations, there arises a need to seek alternative treatment modalities in order to overcome these limitations¹.

One of the greatest challenges of restoring missing teeth in the posterior maxilla results from the fact that both from the sinus-side and from the oral cavity jaw bone tends to resorb and it also tends to deteriorate in quality after tooth extraction. This thereby gives rise to unfavorable conditions that may impede the placement of implants in that region²⁻⁴. The technology of the Strategic Implant[®] overcomes this problem in a different manner compared to both conventional implant systems and conventional technology. Their load transmitting

¹Manufacturer: Simpladent GmbH, Dorfplatz 11, CH-8737 Gommiswald, Switzerland

threads are anchored in native, residual, cortical bone areas often far from the actual clinical tooth, i.e. distant in a vertical and/or sagittal and/or horizontal direction⁵. The Strategic implant® not only avoids any additional surgical procedures but also provide reliable anchor in cortical bone even in severely reduced vertical bone heights, and it can (actually must) be loaded immediately without any waiting period. The technology of the Strategic Implant® is a modern implantology procedure which utilizes stable cortical portions of the jaw bones for retention of the dental implants. Cortical bone provides excellent quality for retention of these unique and highly advanced implants. Dental implantology with the Strategic Implant® follows the application of the rules of orthopedic surgery & traumatology⁶. Basal bone is defined as the resorption-stable part of the osseous tissues of the mandible and maxilla which are underlying the alveolar processes.⁷ It is a stable and almost unchangeable formation of trajectorial bone in the mandible and maxilla.⁸ The basal bone is present throughout life; it is very strong and forms the stress bearing part of our skeleton. If dental implants are anchored in this bone they can be loaded (actually splinted) with fixed tooth restorations immediately. In the technology of the Strategic Implant® the rules of traumatology and orthopedic surgery apply more than anything else, although the actual work is done by dentists and in the oral field. Many of the rules had to be transferred actively by the founders of the technology and they are described today in a number of essential textbooks which have been published in all major languages of the world.

The aim of this paper was to present the clinical application of a new, smooth surface, one-piece (with multiunit abutment) cortically anchored screw implant with immediate loading protocol. The implant neck is bendable, which allows to achieve parallelism easily and without extra parts and costs. This article reports the successful clinical case of immediate functional loading of such implants in the lateral edentulous maxilla with screw retained prosthesis, without any sinus lifts or bone augmentations and with no risk of peri-implantitis.

II. Case Report

A 50-year-old, healthy female patient with bilaterally missing upper posterior teeth presented to the clinic with a chief complaint of difficulty in chewing and a desire to have fixed restored teeth for the same. Clinical examination [Figure 1 & 2] revealed bilaterally missing premolars and molars in the maxillary arch. Radiographic examination [Figure 3] revealed severely atrophic posterior maxillae and increased pneumatization of the maxillary sinus. The decision was made to use a single-piece immediate loading smooth surface bicortical screw implants with multiunit abutment with screw retained prosthesis (Figure 4). Local anesthesia was achieved with lidocaine 2% with adrenaline 1:100000. Infiltration was made in the greater palatine area of the soft palate and lateral buccal vestibule and posterolateral part of palate. Following soft tissue cleaning with antiseptic 5% Betadine solution (water based), flapless surgery preparation of osteotomy sites was carried out using the sequential order of calibrated drills recommended by the manufacturer, cooled with saline solution in external mode at a speed of 27000 rpm, implant beds were prepared with the use of a 2.0 mm drill (30 mm long). For the distal maxilla we used the straight handpiece, for the anterior implants angled handpieces 1:1 were used. Two long one-piece implants with a diameter of 3.6 mm and a length of 23 mm and 29 mm were placed and anchored in the cortical in pterygoid plate of the sphenoid bone on the right side, where superior primary stability is achievable. Implants with the length of 26 mm and 23 mm were placed and anchored in the distal maxilla in the left side of the patient, with one implant being anchored in the pterygoid process of the sphenoid bone. The more anterior distal implant reached through the palatal side of the alveolar bone of the maxilla up to the cortical of the nose. Anteriorly, in the premolar area, two long single-piece implants with a diameter of 3.6 mm and a length of 17 mm and 14 mm were placed and anchored in anterior wall of sinus and canine buttress area on both sides. The implants were bent to a favorable position of the internal thread so that screw access holes come occlusally (figure 5 and 6). Immediately after surgery final impression was taken for final prosthesis. Open tray impression posts were fitted on to BECES® MU implants and both side all four impression post were splinted with pattern resin for accurate impression (figure 7) and open tray impression was taken with putty and light body of polyvinyl siloxane material. Within 72 hours final metal fused to ceramic prosthesis screwed in onto the implants and final tightening of screw done at 35 N torque (Figure 10 and 11). Access holes were blocked with Teflon and covered with composite material (Figure 13). Very good result of this treatment was achieved with high patient satisfaction (Figure 14).

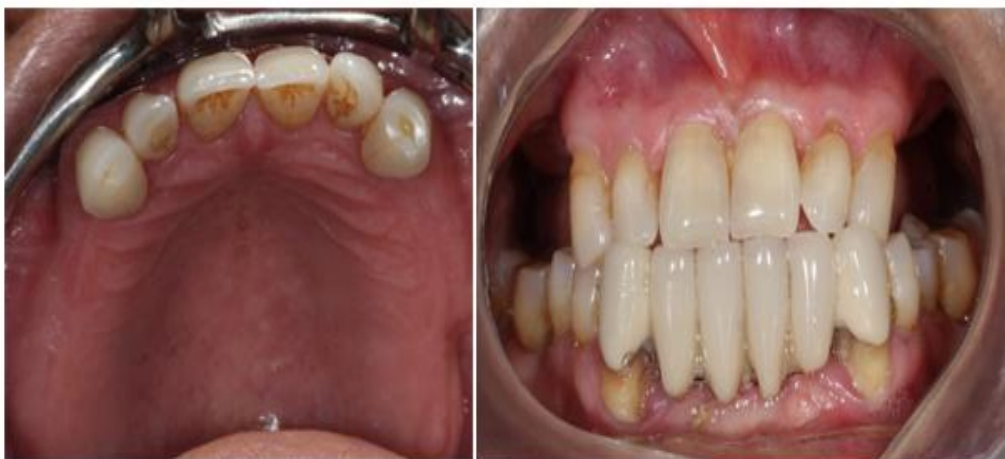

Figure 1 and 2: Clinical intra-oral examination. The lower jaw shows periodontal involvement but does not need immediate treatment or extraction. After this implant treatment the lower premolars and molars will be under regular functional load, which will increase chances for higher mineralization and prolong tooth survival.

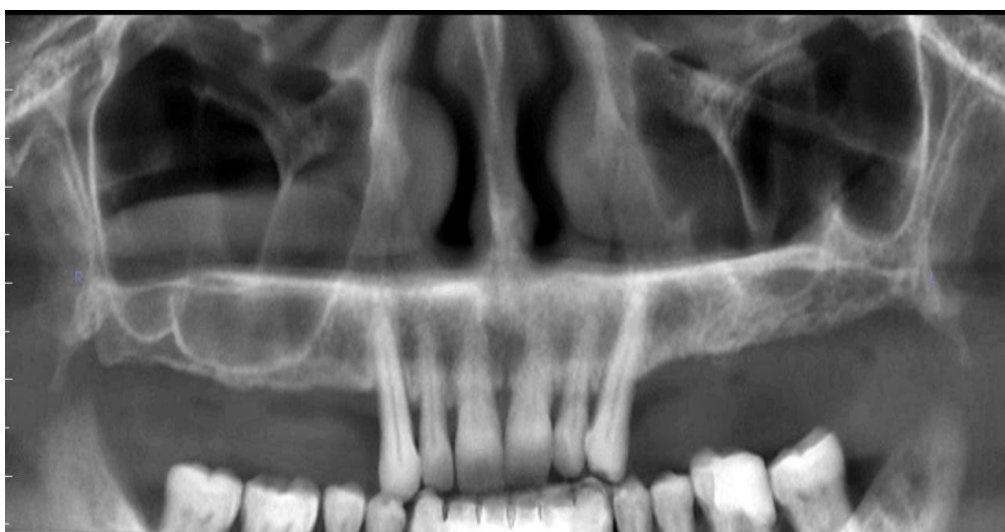

Figure 3: Radiographic pre-operative view.



Figure 4: BECES® MU (single piece multi-unit) implant on the delivery holder

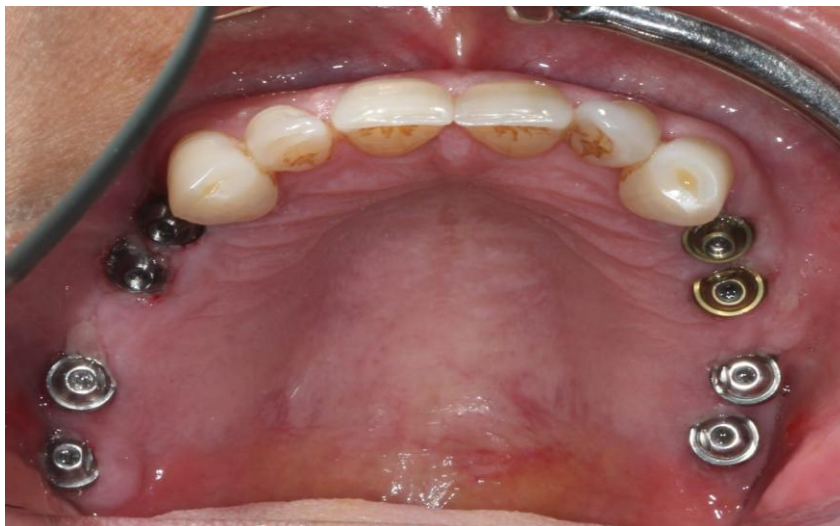

Figure 5: Implant placement

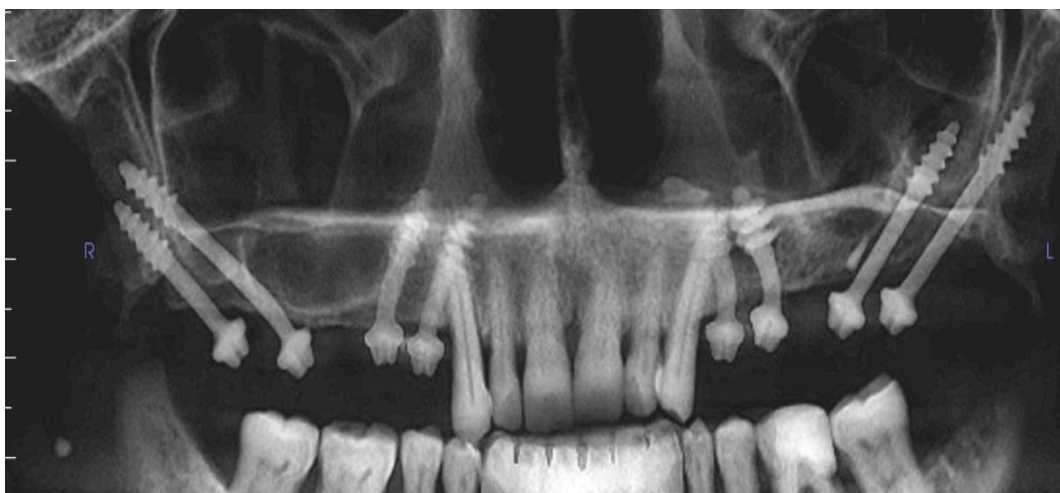

Figure 6: Radiographic view post implant placement.

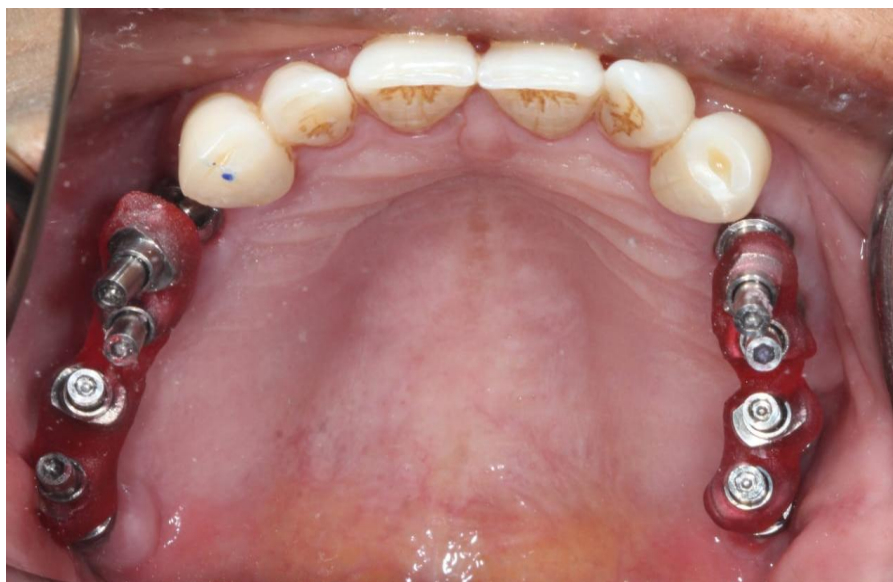

Figure 7: Impression post splinted with pattern resin and before pick-up impression

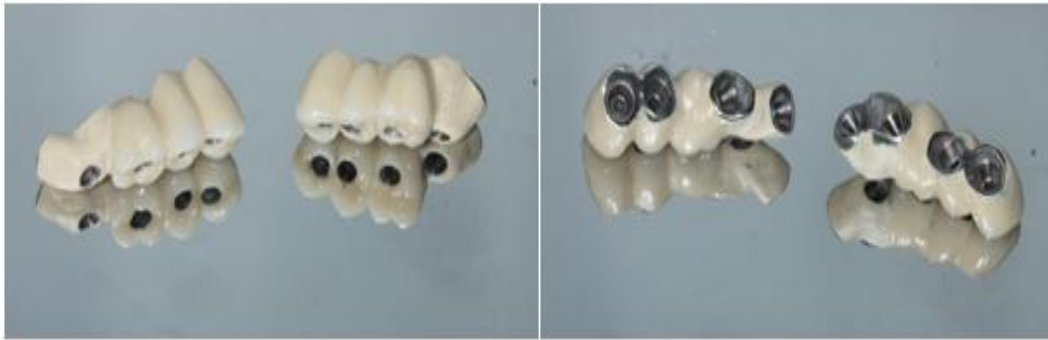

Figure 8 and 9: Screwable porcelain-fused-to-metal restoration (outer and inner view)

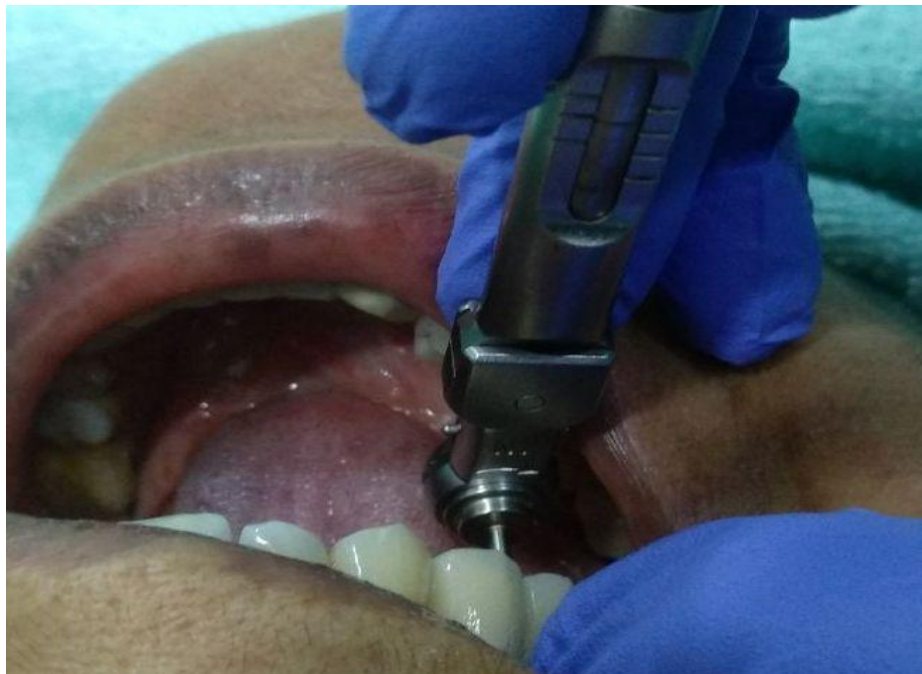


Figure 10: Final torque given at 35N

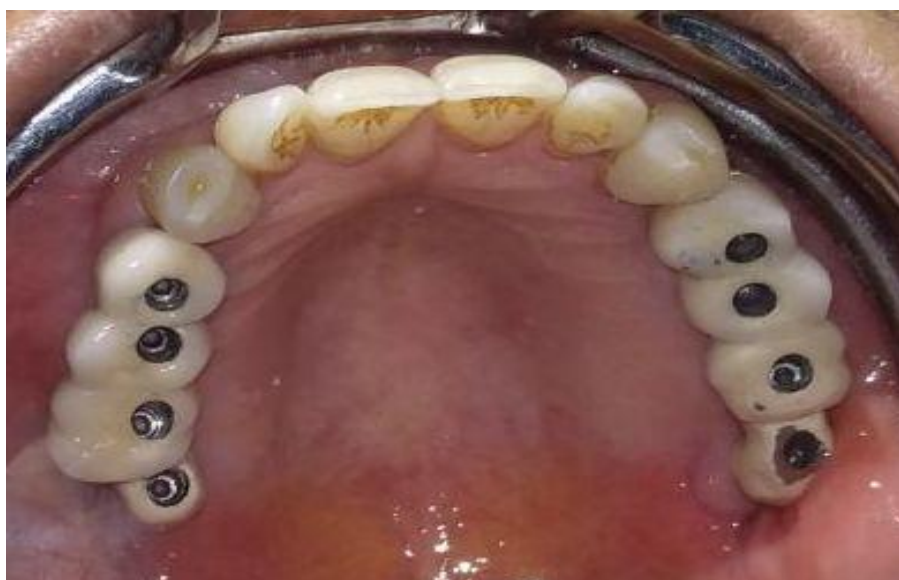

Figure 11: Final Prosthesis

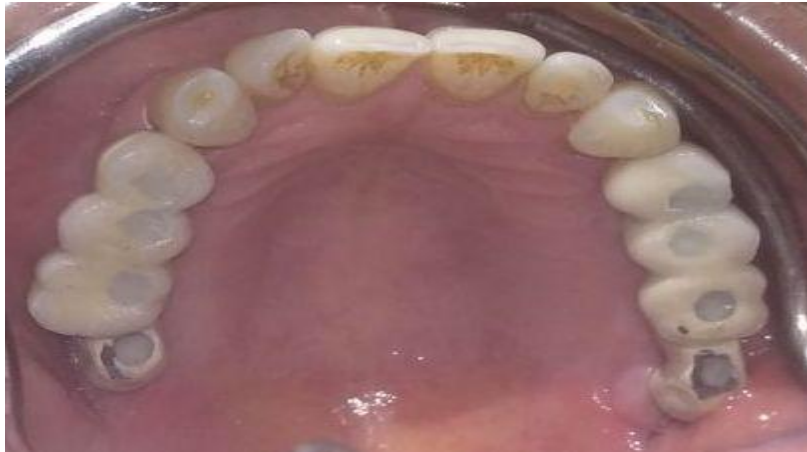

Figure 12: After sealing the holes in the prosthesis with Teflon and covering with composite material

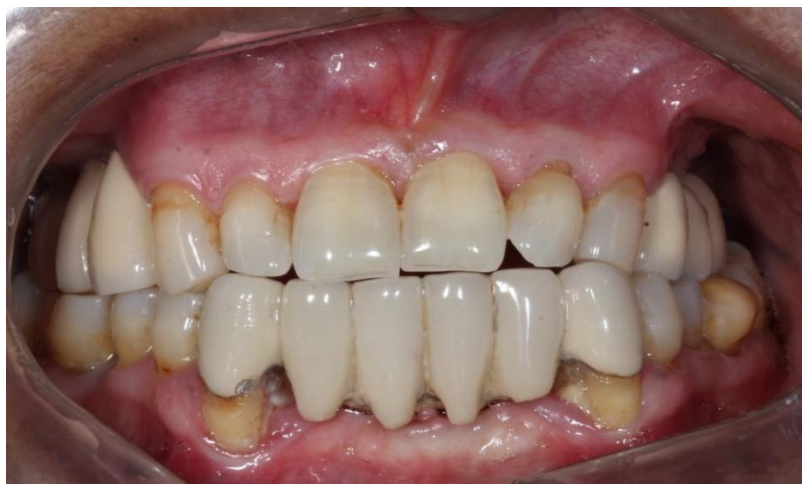

Figure 13: Post-operative view

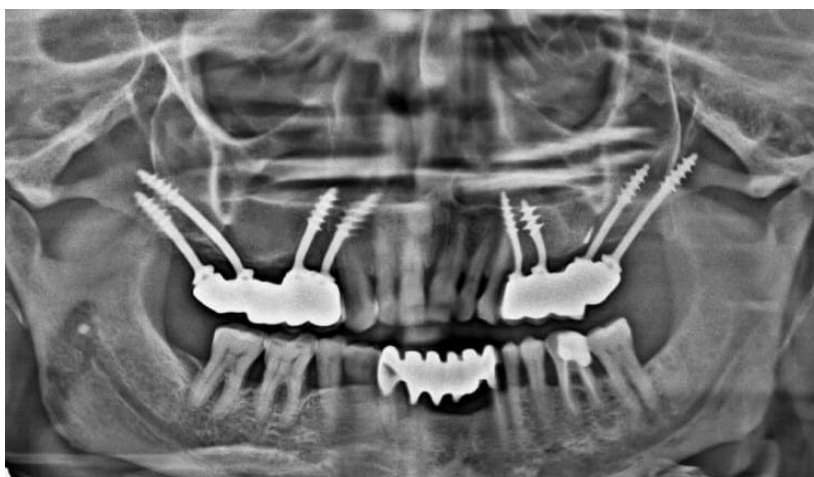

Figure 14: Post-operative radiographic view

III. Discussion

The expanded sinus cavity and shrinking posterior maxillary alveolar bone both make it difficult to place conventional dental implants posterior to the first premolar without sinus augmentation. Placement of an implant into the pterygoid plate area has been used to overcome these anatomic obstacles, allowing successful restoration of the area⁹. Balshi et al¹⁰, Pi¹¹ Fernandez and Fernandez¹², Balashi and Wolfinger¹³ reported results of pterygomaxillary implants with a high success rate.

Vila-Bioscaet al.¹⁴ compared pterygoid implants with the sinus lift technique. The authors explained the main indications, advantages and inconveniences of both procedures. They considered the pterygoid implant technique to be less invasive, with a usually shorter intervention time and interval to patient rehabilitation.

There is a general tendency to reduce treatment times and to simplify treatment procedures in order to increase patient acceptance and to reduce the risk of complications. In implant dentistry, treatment time can be shortened through early or immediate loading. It is widely accepted that immediate loading is desirable if the outcome in terms of implant survival and treatment success is comparable with that of conventional loading.

The Strategic Implant® totally changed the possibilities of dental implantology world-wide. Sinus lift procedures have become avoidable today because all patients have sufficient native bone for anchoring these implants, even if the formerly necessary "vertical bone" is missing. BECES MU implants are placed flapless, i.e. they require only a minimally invasive procedure through gum¹⁵. Masticatory load transmission⁷ is confined to the horizontal implant segments and essentially to the cortical bone structures. This virtually eliminates the need for vertical bone augmentation procedures.

Advantages of the technology of the Strategic Implant®:

1. No bone graft is necessary
2. The anterior-posterior spread is maximized; there is no need for cantilevering.
3. Treatment time is shorter than with sinus grafting, no healing time.
4. Safe load transmission into basal and cortical bone
5. No peri-implantitis¹⁶
6. Immediate functional loading
7. Minimally invasive, minimal surgical complications, simple prosthetic treatment.

IV. Conclusion

There are today advanced options for immediate implant placement and immediate functional loading of implants in distal maxilla available. The technology of the Strategic Implant® avoids nowadays bone grafting. One such case is shown here as an example. The Strategic Implant® allows treatments in a much shorter chair time and with less and cheaper parts compared to traditional Multi-Unit Implant systems. This helps us to treat many more patients than earlier, in fact we hope to provide fixed teeth to everyone as soon as the technology will spread further and enough dentist technicians (or computerized equipment for individual but automatized prosthesis production) are available.

References

- [1]. Ihde S. Comparison of basal and crestal implants and their modus of application. Smile Dental Journal 2009;4:36-46.
- [2]. Jaffin RA, Berman CL. The excessive loss of Branemark fixtures in type IV bone: A 3 year analysis. J Periodontol 1991;2:2-4
- [3]. DaSilva JD, Schnitman PA, Wohltle PS, Wang HN, Koch GG. Influence of site on implant survival: 6 years results (abstract). J Dent Res 1992;71:256.
- [4]. Weber HP, Fiorellino JP. The biology and morphology of the implant-tissue interface. AO 1992;85:61,64.
- [5]. Tomas Goldmann, Stefan Ihde, Jiri Kuzelka, Lucie Himmlova. Bendable vs. Angulated dental implants: consideration of elastic and plastic material properties based on experimental implant material data and FEA Biomed Pap Med Fac Univ Palacky Olomouc Czech Repub. 2008, 152(2):1.
- [6]. Yadav RS, Sangur R, Mahajan T, Rajanikant AV, Singh N, Singh R. An Alternative to Conventional Dental Implants: Basal Implants
- [7]. The Glossary of Prosthodontic Terms – 8. J Prosthet Dent 2005;94(1):17.
- [8]. Weiss CM, Weiss A. Principles and practice of implant dentistry. 1st edition. The United States of America Mosby, Inc. 2001.
- [9]. Graves, Stuart L. The Pterygoid Plate Implant: A Solution for Restoring the Posterior Maxilla. Int Journal of Periodontics & Restorative Dentistry; Dec 1994, Vol. 14 Issue 6, p512
- [10]. Balshi TJ, Lee HY, Hernandez RE. The use of pterygomaxillary implants
a. in the partially edentulous patient: a preliminary report. Int J Oral Maxillofac Implants 1995;10:89-98.
- [11]. Pi-Urgell J. Implantes en la región pterigomaxilar: estudio retrospectivo con seguimiento de 1 a 10 años. RCOE 1988;3:339-48.
- [12]. Fernández J, Fernández L. Placement of screw type implants in the pterygomaxillary-pyramidal region: a surgical procedure and preliminary results. Int J Oral Maxillofac Implants 1997;12:814-9.
- [13]. Balshi TJ, Wolfinger GJ. Analysis of 356 pterygomaxillary implants in edentulous arches for fixed prosthesis anchorage. Int J Oral Maxillofac Implants 1999;14:398-406.
- [14]. Vila-Biosca M, Marcet-Palau JM, Faura-Solé M. Implantes pterigoideos versus elevación sinusal. Comparación crítica. Arch Odontostomatol 1999;15:523-35.
- [15]. IHDE Dental. [Online]. Cited 2015 February 2; Available from: URL: <http://www.boi.ch/index.php/en/>.
- [16]. For details and literature see on www.peri-implantitis.info/en

Vivek Gaur "Immediate Loading of Implants in the Partially Edentulous Maxilla: A Case Report of a Novel Technique with Strategic Implants ."IOSR Journal of Dental and Medical Sciences (IOSR-JDMS), vol. 17, no5, 2018, pp 34-40