

## Lag screw osteosynthesis in the management of oblique mandibular fractures- Analysis of outcome in ten patients

Manoj Kumar KP<sup>1</sup>, Sujatha Varma<sup>2</sup>

Professor<sup>1</sup> Dept.of Oral &Maxillofacial Surgery KMCT Dental College, Manassery Kozhikode, Kerala,India

Assistant Professor<sup>2</sup> Dept.of Oral and Maxillofacial Pathology, Govt.Dental college, Kozhikode, Kerala,India

Corresponding Author: Manoj Kumar KP

---

**Abstract:** The management of facial trauma, though frequent, is a demanding aspect of work, a maxillofacial surgeon encounters in his practice. Mandible being the prominent and mobile bone of orofacial skeleton, fractures is common in occurrence. Rigid internal fixation in facial bone fractures is aimed to obtain absolute stability and immobilization. The aim of this study is to analyze the clinical outcome in ten patients who underwent open reduction and rigid internal fixation with lag screw osteosynthesis technique for mandibular fractures.

**Key words:** fracture, mandible, lag screw technique, osteosynthesis

---

Date of Submission: 22-04-2018

Date of acceptance: 08-05-2018

---

### I. Introduction

Fracture of the mandible occurs more frequently than any of the other bones of facial skeleton. Objectives of mandibular fracture management include the restoration of a functional occlusion, anatomic form and facial aesthesia. Rigid internal fixation resists the forces of muscles of mastication; achieve an excellent reduction of the fracture and primary bone healing. It is associated with a lower rate of infection, non union and mal union when compared with the standard therapy of open or closed reduction combined with maxillo mandibular fixation.

The basic concept of lag screw osteosynthesis is to produce interfragmentary compression which stabilizes the fractured segments.<sup>1</sup> This is achieved by engaging a cortical screw which has threads along its entire length. The term lag screw is probably the most misunderstood of all terms involved with rigid internal fixation as it is used both to describe a type of screw as well as a technique of screw placement.

Lag screw osteosynthesis is a form of compression osteosynthesis in which the bone segments are bound to one another as a result of traction from the screw.<sup>2</sup> A true lag screw has threads only on its terminal end. When used, the threads engage the far cortex, while the head seats against the near cortex, providing compression up on tightening. Lag screw technique is achieved with a cortical screw which has threads along its entire length by overenlarging the hole in the near cortex. This procedure is more commonly used in maxillofacial surgery than the true lag screw<sup>3</sup>. This study is intended to assess the efficacy of lag screw technique in the management of oblique fractures of mandible.

### II. Materials and methods

This study was carried out on patients of Department of Oral and Maxillofacial Surgery KMCT Dental College and Hospital, Kozhikode, Kerala. Ten male patients who sustained oblique fractures of mandibular symphysis and body were included in this study. A detailed clinical and radiographic examination was carried out to rule out head injury and injury to vital organs. The occlusion of teeth, type and location of fractures were assessed by radiographs.

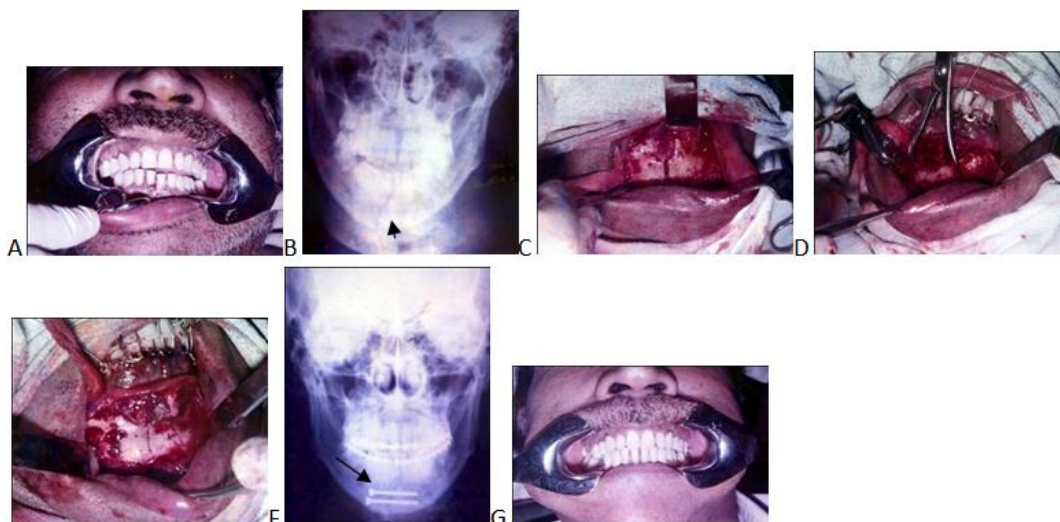
After establishing the diagnosis, the treatment plan was explained to the patient and an informed consent was obtained. All of the patients received pre-operative parenteral antibiotics. Fractures of symphysis were accessed intra orally, while those of body of mandible were accessed through extra oral approach. Patient data is summarized in Table 1.

Once the fracture site was exposed and debrided thoroughly, a modified towel clip with its tips bent outward was used to assist in firmly reducing the segments before lag screw placement (Figure 1,2-D). To provide a purchase for the towel clip, small drill holes were placed approximately 10 mm away from each side of the fractured segment. A bur hole was made using a 2.7mm drill bit in the outer cortex of the fractured segment, along the line which bisects the angle perpendicular to the fracture line and bone surface. Then a 2mm drill bit was used to drill the distal fragment through the previous bur hole. With a 2.7mm tap, the thread hole was cut in to the distal fragment. For lodging the spherical screw head, a corresponding bed was created

(counter sinking) in the outer cortical bone over the gliding hole. Thus the 2.7mm cortical bone screw can glide through the hole in the outer fragment end and obtain its firm hold in the thread of the inner cortical bone. The wounds were closed in two layers.

Post operatively the reduction and immobilization were assessed by trying to move the fractured segments manually in opposite direction. During the immediate post-operative follow period, the patients were examined clinically for signs of infection, mobility of fractured segments, and derangement of occlusion and whether they developed any sensory disturbances. The follow up period ranged from 3 months to 18 months. (Table 2)

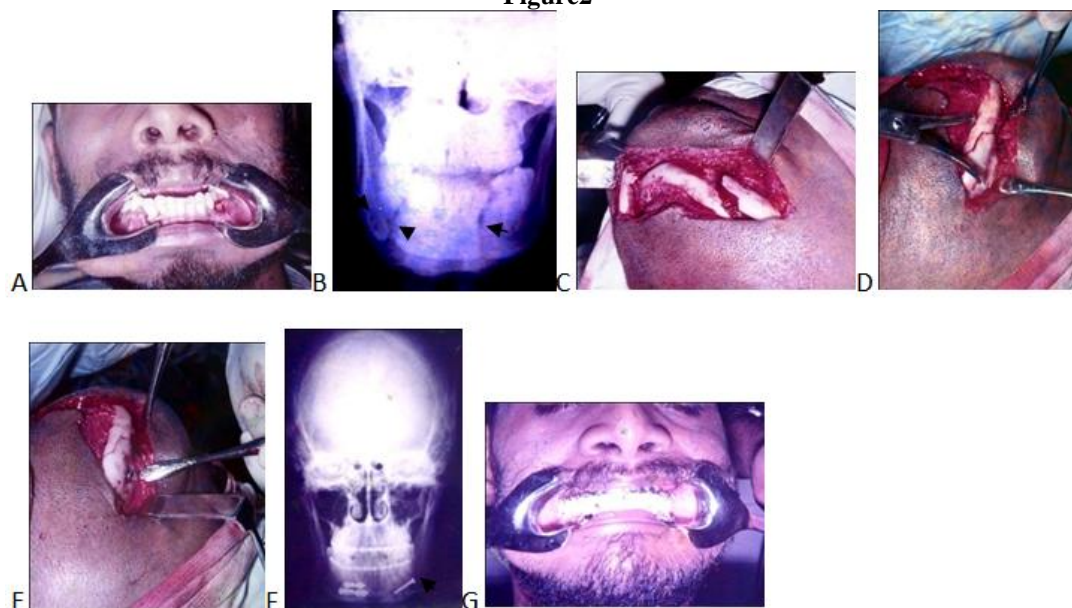**Figure1**



**Figure1**

- A -52 year old male-fracture of mandibular symphysis(note the deranged occlusion)
- B -Radiograph(AP view –skull)-arrow mark indicates the fractureline
- C- Intra operative photograph –exposureof fracture site
- D-Reduction of fracture segments
- E-two lag screws placed and immobilisation achieved
- F- Post operative Radiograph(Antro Posterior view –skull)-- arrow mark indicates the lagscrews
- G-Post operative photograph –note the teeth in perfect occlusion

**Figure2**



**Figure 2**

A -25year old male-fracture of body of mandible( bilateral )with deranged occlusion  
 B -Radiograph(Antro Posterior view –skull)-arrow marks indicatethe fracture sites  
 C- Intra operative photograph –exposureof fracture site  
 D-Reduction of fracture segments  
 E-one lag screw placed on the left body of mandible  
 F- Post operative Radiograph(A Pview –skull)-- arrow mark indicates the lagscrews ,miniplates and screws on the opposite side  
 G-Post operative photograph

**Table 1**

Sl.no	Age, gender	Cause of trauma	Fracture site	Occlusal derangement present/absent	Displacement of fracture present/absent	Tooth in fracture line yes/no	Periodontal status	Pre operative Sensory disturbance Present/absent
1	23,male	Road traffic accident	Symphysis, left condyle	P	P	N	GOOD	P
2	21 male	„	Left body	P	P		GOOD	P
3	15 male	„	Left body	P	P	Y	GOOD	N
4	22 male	„	Right body	P	P	Y	GOOD	N
5	28male	„	Symphysis	P	P	N	GOOD	N
6	25 male	Fall	Symphysis, left condyle	P	A	N	POOR	N
7	24 male	Road traffic accident	Right body	P	P	N	GOOD	N
8	52 male	„	Symphysis	P	P	N	POOR	N
9	25 male	„	Bilateral body	P	P	N	GOOD	N
10	32 male	„	Right body	P	A	N	GOOD	N

**Table 2**

Sl.no	Approach	No. of lag screws placed	Removal of tooth in fracture line Y/N	Deranged occlusion Y/N	Mobility of fracture segments present/absent	Infection Present/absent	Post operative Sensory disturbance Present/absent
1	Intra oral	1	N	Y	N	N	P
2	Extra oral	1	N	N	N	N	P
3	Extra oral	1	N	N	P	P	N
4	Extra oral	1	N	N	N	N	N
5	Intra oral	1	N	N	N	N	N
6	Intra oral	1	N	N	N	N	N
7	Extra oral	1	N	N	N	N	N
8	Intra oral	2	N	N	N	N	N
9	Extra oral	1	N	N	N	N	N
10	Extra oral	1	N	N	N	N	N

**P –Present, A –Absent**

**Y-Yes, N-No**

**III. Discussion**

The lag screw technique was first introduced to maxillofacial surgery by Brons and Boering in 1970.<sup>4</sup> There is general agreement that compression of a fracture site is a useful adjunct to stability. Compression probably does not stimulate osteogenesis, but provides intimate apposition and mechanical stability, allowing primary healing to occur. Inter fragmentary compression and rigid immobilization can be accomplished with a minimum of implant material using lag screw osteosynthesis principle<sup>5</sup>. At least two screws are necessary to resist rotational movement of segments in oblique fractures of mandible as the shear forces may allow rotation of mandibular fragments around the screw<sup>4</sup>. Application of arch bars to the teeth may prohibit rotational forces. In our study, a single screw was used in all but one case. Arch bars were retained for three weeks and the patients were instructed to follow a soft diet for the period. Fixation was found to be stable in all cases.

The use of lag screws alone has got several unique advantages over bone plate fixation. The major advantage is that the lag screws can be applied rapidly, and the fracture gap completely disappears in most cases due to the compression imparted by the screws. Lag screws are cost effective also when compared with that of bone plates<sup>6</sup>. Lag screws can be employed as a minimal access technique for management of anterior mandible fracture with several advantages over conventional methods.<sup>7</sup> Anchor lag screws were found to better than conventional lag screws in terms of bone resorption and loosening of screws<sup>8</sup>.

Despite the many advantages lag screw fixation offer, there are certain contraindications for its use. The most important ones are comminution and bone loss in the fracture segments. If the intervening bone is unstable due to comminution, or it is missing, compression across this area may cause displacement of bone segments, over riding of segments or shortening of the fracture gap, all leading to deranged teeth occlusion<sup>9</sup>. Inter fragmentary compression force, insertion force of the screws along with the vascular insult in elevating the periosteum inhibits the diffusion of nutrients in to the bone, leading to necrosis.

Lag screw osteosynthesis is technique sensitive<sup>10,11</sup>. Selecting the point of entry in to the bone and the alignment of the drill are crucial in determining the success of the procedure. An adequate amount of bone should be present between the head of the screw and the fracture line<sup>12</sup>. Countersinking of the outer cortex is one of the most important steps in lag screw technique. This is necessary to maintain an adequate reduction following the insertion of screws. Inadequate countersinking may displace the segments or cause fracture of outer cortex. Since the medullary bone offers insufficient rigidity to the screws, one must avoid deeper countersinking to avoid the situation in which the screw head rests on medullary bone<sup>3</sup>. In one of our cases, mobility of fracture segment resulted, due to the excessive countersinking of buccal cortex.

There is considerable evidence that the presence of implant causes impairment of phagocytic activity by poly morpho nuclear leukocytes<sup>13</sup>. When compared with miniplate osteosynthesis, lag screw technique involves a minimum of implant material, thus reducing the chance of infection. Rigidity has been shown to prevent bacteria from being continually pumped through the fracture site<sup>13</sup>. In one of our cases, post-operative mobility was present, leading to infection.

The role of teeth in fracture line in promoting post-operative infection is difficult to determine. Presence of tooth in fracture line makes the fracture compound to the oral cavity.<sup>14</sup> Many of the studies recommend the removal of teeth along the fracture line as they may become non vital and lead to pulpal or periodontal infections. In our experience, there were teeth present in the fracture line in two cases, but we did not remove them and no post operative complications ensued.

Despite good clinical results, lag screws do not meet the needs for rigid internal fixation in mandibular condyle fractures.<sup>15</sup> Two of our patients had concomitant fractures of condyle, which were managed by closed reduction method. Pre operative sensory disturbances in patients who sustain mandibular fractures were found to correspond to the degree of displacement of fractures segments.<sup>16</sup> In our series of cases, only two patients had preoperative sensory disturbances of the lower half of face on the affected side. This may be attributed either to the traction or compression of inferior alveolar nerve along the fractured mandibular segments. Post operative sensory disturbance was not encountered in any of our patients.

To summarize; the lag screw technique can be effectively used with very minimal complications by an experienced maxillofacial surgeon.

#### **IV. Conclusion**

The lag screw technique when properly applied may be an easy and inexpensive way to treat fractures of mandible.

#### **References**

- [1]. Perren SM. Physical and biological aspects of fracture healing with special reference to internal fixation. Clin Orthop Relat Res. 1979 (138):175-96.
- [2]. Zachariades N, Mezitis M, Papademetriou I. Use of lag screws for the management of mandibular trauma. Oral Surg Oral Med Oral Pathol Oral Radiol Endod. 1996; 81(2):164-7.
- [3]. Ellis E 3rd, Ghali GE. Lag screw fixation of mandibular angle fractures. J Oral Maxillofac Surg. 1991. 49(1):13-21; discussion 21-2.
- [4]. Brons R, Boering G. Fractures of the mandibular body treated by stable internal fixation: a preliminary report. J Oral Surg. 1970; 28(6):407-15.
- [5]. Dawson DE, Gapany M, LaVelle WE. Titanium lag-screw osteosynthesis for the restoration of mandibular continuity in mandibular "swing" procedures. Laryngoscope. 1990; 100(11):1241-4.
- [6]. Ellis E 3rd. Use of Lag screws for fractures of mandibular body. J Oral maxillofac surg. 1996; 1314-16
- [7]. Jadwani S, Bansod S. Lag screw fixation of fracture of the anterior mandible: a new minimal access technique. J Maxillofac Oral Surg. 2011; 10(2):176-80. doi: 10.1007/s12663-011-0176-2. Epub 2011 Apr 7.
- [8]. Kumar V, Mehrotra D, Mohammad S, Singh RK, Singh V, Singh G, Gambhir S. Anchor lag screw vs conventional lag screw in mandibular fractures: A series of 30 cases. J Oral Biol Craniofac Res. 2013; 3(1):15-9. doi: 10.1016/j.jobcr.2013.01.002. Epub 2013 Jan 31
- [9]. Ellis E 3rd, Ghali GE. Lag screw fixation of anterior mandibular fractures. J Oral Maxillofac Surg. 1991; 49(3):234-43

- [10]. Iizuka T, Lindqvist C, Hallikainen D, Paukku P. Infection after rigid internal fixation of mandibular fractures: a clinical and radiologic study. *J Oral Maxillofac Surg.* 1991;49(6):585-93
- [11]. Kallela I, Iizuka T, Laine P, Lindqvist C. Lag-screw fixation of mandibular parasymphiseal and angle fractures. *Oral Surg Oral Med Oral Pathol Oral Radiol Endod.* 1996 ; 82(5):510-6.
- [12]. Ilg P, Ellis E III. A comparison of two methods for inserting lag screws. *J Oral Maxillofac Surg.* 1992 ; 50(2) 119–123
- [13]. Koury M, Ellis E III. Rigid internal fixation for the treatment of infected mandibular fractures. *J oral Maxillofac Surg* 1992;50:434-43
- [14]. Neal DC, Wagner WF, Alpert B. Morbidity associated with teeth in the line of mandibular fractures. *J Oral Surg.* 1978 ; 36(11):859-62
- [15]. Kallela I, Söderholm AL, Paukku P, Lindqvist C .Lag-screw osteosynthesis of mandibular condyle fractures: a clinical and radiological study. *J Oral Maxillofac Surg.* 1995; 53(12):1397-404; Discussion 1405-6.
- [16]. Iizuka T, Lindqvist C .Sensory disturbances associated with rigid internal fixation of mandibular fractures. *J Oral Maxillofac Surg.* 1991; 49(12):1264-8.

Manoj Kumar Kp "Lag screw osteosynthesis in the management of oblique mandibular fractures- Analysis of outcome in ten patients" *IOSR Journal of Dental and Medical Sciences (IOSR-JDMS)*, vol. 17, no. 5, 2018, pp 51-55.