

Hemiballism Secondary to Controlateral Sub thalamic Hemorrhage Caused by Acenocoumarol Overdose: a Case Report

Naima Chtaou^{1,2}, Aouatef El Midaoui^{1,2}, Zouhayr Souirti¹,
Mohammed Faouzi Belahsen^{1,2}

¹Neurology Department, Hassan II University Hospital, Fez, Morocco

²Laboratory of Epidemiology and Public Health, Faculty of Medicine and Pharmacy, Sidi Mohammed BenAbdellah university Fez, Morocco
Corresponding Author: Naima Chtaou

Abstract: The estimated prevalence of movement disorders among patients with cerebrovascular disease is 1% with an incidence of 0.08% at 1 year [1]. Hemiballism secondary to controlateral subthalamic haemorrhage caused by acenocoumarol overdose is exceptional. To the best of our knowledge, no similar case has been reported in the literature.

We describe the case of a 70-year-old Moroccan man who presented with involuntary left arm and leg movements. Anamnesis revealed that he was taking vitamin K antagonist (acenocoumarol: Sintrom®) during 5 months for a deep vein thrombosis of lower limb.

The brain CT revealed a focal hemorrhage in the subthalamic nucleus. The results of laboratory tests that the international normalized ratio was very high (INR: 8.8).

A diagnosis of hemiballism secondary to controlateral STN haemorrhage caused by an overdose of acenocoumarol was made.

Acenocoumarol was stopped and the patient was treated by neuroleptic: Risperidone 1 mg once a day with improvement of symptoms.

This case report highlights the possibility of hemiballism secondary to controlateral subthalamic haemorrhage caused by acenocoumarol overdose.

Keywords: Hemiballism- Hemorrhage stroke- Subthalamic nucleus

Date of Submission: 12-06-2018

Date Of Acceptance: 27-06-2018

I. Introduction

Hemiballism is a rare hyperkinetic movement disorders characterized by unilateral flinging and violent involuntary movements of one side of the body. Stroke of the controlateral basal ganglia, especially the subthalamic nucleus (STN), is the most common cause of acute development of hemiballism. We report the unusual case of patient presenting with hemiballism secondary to small of subthalamic haemorrhage caused by anticoagulant overdose

II. Case report

A 70 year-old man without a history of hypertension who suddenly developed involuntary left arm and leg movements. Anamnesis revealed that he was taking vitamin K antagonist (acenocoumarol: Sintrom®) during 5 months for a deep vein thrombosis of lower limb.

On neurologic examination, the movements were rapid, uncontrollable, predominantly in the left arm, and minimally in the left leg. Involuntary movements were not seen in the axial musculature. The ballistic movements were decreased at rest and disappeared during sleep. No peribuccal and tongue involuntary movements were noted. There was no motor and no sensory impairment. Blood pressure was normal: 120mmHg/60mmHg.

On the day of admission, brain CT revealed a focal hemorrhage in the STN (figure 1). The results of laboratory tests, including complete blood cell counts, serum electrolyte levels and liver function tests were normal, but the international normalized ratio was very high (INR: 8.8).

A diagnosis of hemiballism secondary to controlateral STN haemorrhage caused by an overdose of acenocoumarol was made.

The ultrasound control of lower limb was normal. Acenocoumarol was stopped and the patient was treated by neuroleptic: Risperidone 1 mg once a day with improvement of symptoms. A control brain MRI was performed after 2 months and revealed hypointensity in the right STN on T2 weighted and gradient echo (figure 2)

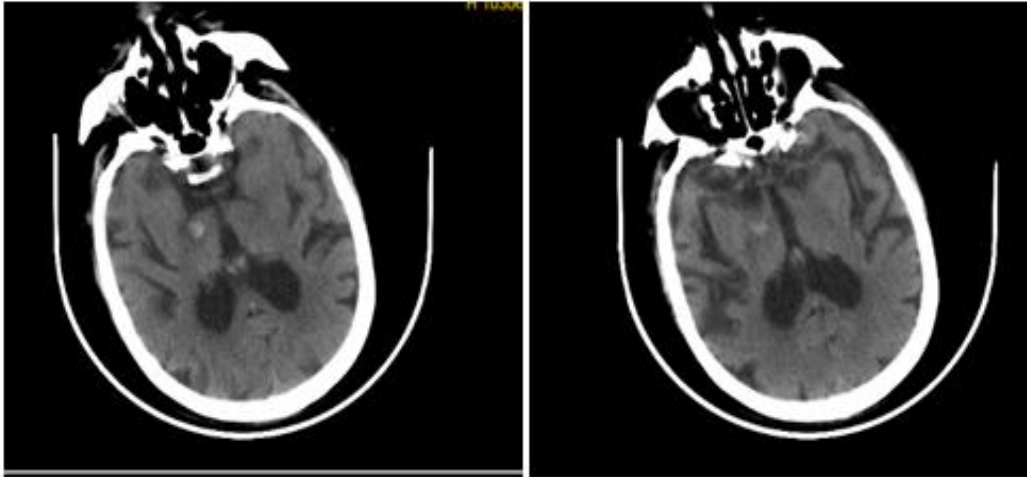


Figure 1: Axial unenhanced CT shows focal hemorrhage in the right sub thalamic nucleus

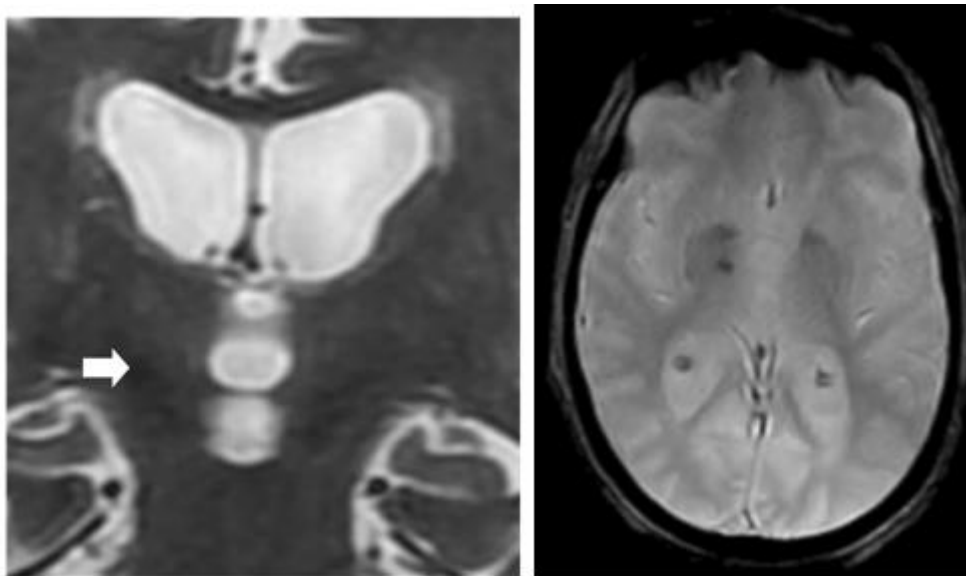


Figure 2: MRI of the patient 2 months postevent. Coronal T2-weighted and gradient-echo (T2*) MRIs show a focal haemorrhage in the right subthalamic nucleus.

III. Discussion

Hemiballismus is a rare hyperkinetic movement disorder characterized by high amplitude, violent and proximal involvement of the extremities localized in the one side of the body. Classically, it has been related most often to lesions of the contralateral STN (2). The pathophysiology of hemiballism remains controversial. One of the potential mechanism proposed is when a lesion of the subthalamic nucleus may cause a loss of subthalamic excitation in the medial pallidum. It can also reduce striato-pallidal inhibitory influences and lead to reduced excitatory projections from the STN to the pars interna of the globus pallidus followed by disinhibition of the thalamic neurons (3). For our patient, damage to STN by focal hemorrhagic lesion might have caused decrease in subthalamic excitatory activity and subsequent hemiballism. In literature, other regions including cortex, caudate, putamen, thalamus, and brainstem have been reported to be in association as causative lesions of hemiballism(1).

Many etiologies exist for this rare movement disorder. Vascular causes (Ischemic and Hemorrhagic stroke) and metabolic (nonketotic hyperglycemia) are the most common (4). Stroke is responsible for the disorder in 50–75% of cases, usually lacunar infarction or, less often, hemorrhages (5). There have been several reported cases of patients with small isolated haemorrhagic lesions in STN (6). The most common reported cause of subthalamic hemorrhage was associated with hypertension (2-7). In our case, there was no history of

hypertension and the cause of hemorrhage is likely due to an overdose of anticoagulant. No publication was found reporting the same case.

Other more rare causes of hemiballism include encephalitis, vasculitis, central nervous system (CNS) Lupus, cerebral toxoplasmosis with Acquired Immunodeficiency Syndrome (AIDS), mass lesions (neoplasms and cysts), and multiple sclerosis (4). Hemiballism has also been rarely reported to be drug induced from levodopa, phenytoin, oral contraceptives and neuroleptics (4).

In literature some exceptional causes were also reported like the development of hemiballism after an iatrogenic injury to the subthalamic nucleus (8), several cases of hemiballism were related to head trauma(5) and hemiballism due to subthalamic nucleus hemorrhage after liver transplantation was also reported (9). In most cases, prognosis is favorable (10). Hemiballism resolves with time, and often no treatment is necessary. Our patient showed improvement after administration of neuroleptics.

IV. Conclusion

Hemiballism is the most dramatic movement disorder seen in clinical practice, this report is the first of its kind in the literature wherein hemiballism arising as a result of STN haemorrhage caused by anticoagulant overdose.

References

- [1]. Chung SJ, Im JH, Lee MC, Kim JS. Hemichorea after stroke: clinical-radiological correlation. *J Neurol* 2004; 251:725–9.
- [2]. Kazuyuki N, Nobutaka H, Yasuyuki O. Hemiballism with leg predominance caused by contralateral subthalamic haemorrhage. *BMJ Case Rep* 2015. doi: 10.1136/bcr-2014-208525.
- [3]. Alexander GE, Crutcher MD. Functional architecture of basal ganglia circuits: neural substrates of parallel processing. *Trends Neurosci* 1990; 13:266–71.
- [4]. Hawley J.S., William J.W. Hemiballismus: Current concepts and review. *Parkinsonism and Related Disorders* 18 (2012) 125e129.
- [5]. Grandas F. Hemiballismus. *Handbook of Clinical Neurology*, Vol. 100 (3rd series). Hyperkinetic Movement Disorders.
- [6]. Hasegawa H, Mundil N, Samuel M, et al. The treatment of persistent vascular hemidystonia-hemiballismus with unilateral GPi deep brain stimulation. *Mov Disord* 2009;24:1697–8.
- [7]. Tateno H, Suzuki K, Okamura M, Takekawa H, Nishihira T, et al. (2014) Hemiballism-Hemichorea Following Subthalamic Nucleus Hemorrhage. *SOJ Neurol* 1(1), 2. DOI: <http://dx.doi.org/10.15226/2374-6858/1/1/00103>.
- [8]. Aqueel Pabaney¹, Rushna Ali¹, Peter A. Lewitt², Christos Sidiropoulos², Jason M. Schwalb¹ Successful Management of Hemorrhage-Associated Hemiballism After Subthalamic Nucleus Deep Brain Stimulation with Pallidal Stimulation: a Case Report. *World Neurosurgery* 84 [4]: 1176.e1-1176.e3, October 2015.
- [9]. J. M. Provenzale, J. P. Glass. MRI in hemiballismus due to subthalamic nucleus hemorrhage: An unusual complication of liver transplantation. *Neuroradiology*, May 1996, Volume 38, Supplement 1, pp S75–S77.
- [10]. Hiroshi N, Takeshi T, Kazunori N, Yukio I. Transient hemiballism caused by a small lesion of the subthalamic nucleus. *Case Reports / Journal of Clinical Neuroscience* 15 (2008) 1416–1418.

Naima Chtaou "Hemiballism Secondary to Controlateral Sub thalamic Hemorrhage Caused by Acenocoumarol Overdose: a Case Report." *IOSR Journal of Dental and Medical Sciences (IOSR-JDMS)*, vol. 17, no. 6, 2018, pp 01-13.