

Rare presentation of nasopharyngeal angiofibroma in adult

Dr. Gautam Kumar Nayak¹, Dr. Pradeep Singh Rawat², Dr. Arup Kakoti³,

Dr. Jyotirmoy Phookan⁴, Dr. Rajarshi Mitra⁵

^{1,4}Associate Professor, Department Of Ent, Gauhati Medical College and Hospital

^{2,5}Post Graduate Trainee, Department Of Ent, Gauhati Medical College and Hospital

³Registrar, Department Of Ent, Gauhati Medical College and Hospital

Abstract: JNA is a histologically benign yet locally aggressive vascular tumor occupying the nasopharynx, seen in adolescent male aged between 5-25 years. The incidence of nasopharyngeal angiofibroma in elderly is extremely low. It is characterized by paroxysms of unprovoked painless profuse epistaxis. These lesions typically arise from sphenopalatine foramen which presents as nasopharyngeal mass.

Keywords: nasopharyngeal angiofibroma, epistaxis, nasopharyngeal mass, adult patient

Date of Submission: 29-05-2018

Date Of Acceptance: 14-06-2018

I. Introduction

JNA constitutes of less than 0.5% of all head and neck neoplasms [1]. It is benign, non-encapsulated highly vascular tumor with single endothelial cell lining of vessels without muscularis layer on histological examination [2]. In very few cases it has been reported in men over 25 years old or females [3]. The tissue origin lies near to the posterolateral wall of nasal cavity just close to the superior border of sphenopalatine foramen [4]. Median age of onset of symptoms is 14 to 18 years. Most common symptomatic presentation of these patients include repeated episodes of epistaxis, nasal obstruction, headache and rest other symptoms depends on the spread of tumor which includes facial, otological, ophthalmological and neurological symptoms. Imaging techniques like CECT (contrast enhanced computed tomography), and magnetic resonance imaging MRI are useful in the assessment of staging of tumor [5]. Biopsy is avoided due to its vasculature. Preoperative embolization is preferred and along with angiography is done to reduce intraoperative bleeding. Treatment modalities including surgery with radiotherapy, hormonal therapy, cryotherapy, electrocoagulation and chemotherapy have been mentioned in literature. Still total surgical excision with radiotherapy is treatment of choice. Various approaches like trans Palatine, mid facial degloving, lateral rhinotomy are described. In 1996, Kamel popularized endoscopic trans nasal endoscopy route for surgery. Newer techniques like Gamma knife are now also used for small size tumor [6].

II. Case report

A 39-year-old male presented to the OPD of ENT department Gauhati medical College and Hospital, Guwahati with complain of bleeding from right nose since last three years associated with nasal obstruction which got aggravated since last one month. There was no associated history of allergy, discharge and trauma. Nasal endoscopy was done which showed fleshy and firm mass which bleeds on touch and occupying right nasal cavity. Contrast enhanced CT scan shows polypoidal lesion in right nasal cavity abutting the nasal septum encroaching nasopharynx with mild bony erosion in this sphenoid sinus and asymmetrical dilation of right sphenopalatine foramen. Laboratory test did not show any abnormality on blood morphology and coagulation profile. Patient was put in OT for endoscopic approach but due to excessive bleeding around 1000 ml from the mass procedure was abandoned. Later patient was operated by lateral rhinotomy approach with endoscopic assistance and intraoperative mass was seen involving right nasal cavity, choana and extending laterally to maxillary sinus. Mass with dimensions around 4×3×1.5 cm was removed as a whole and send for histopathology, which show features of Nasopharyngeal angiofibroma with high fiber elements.

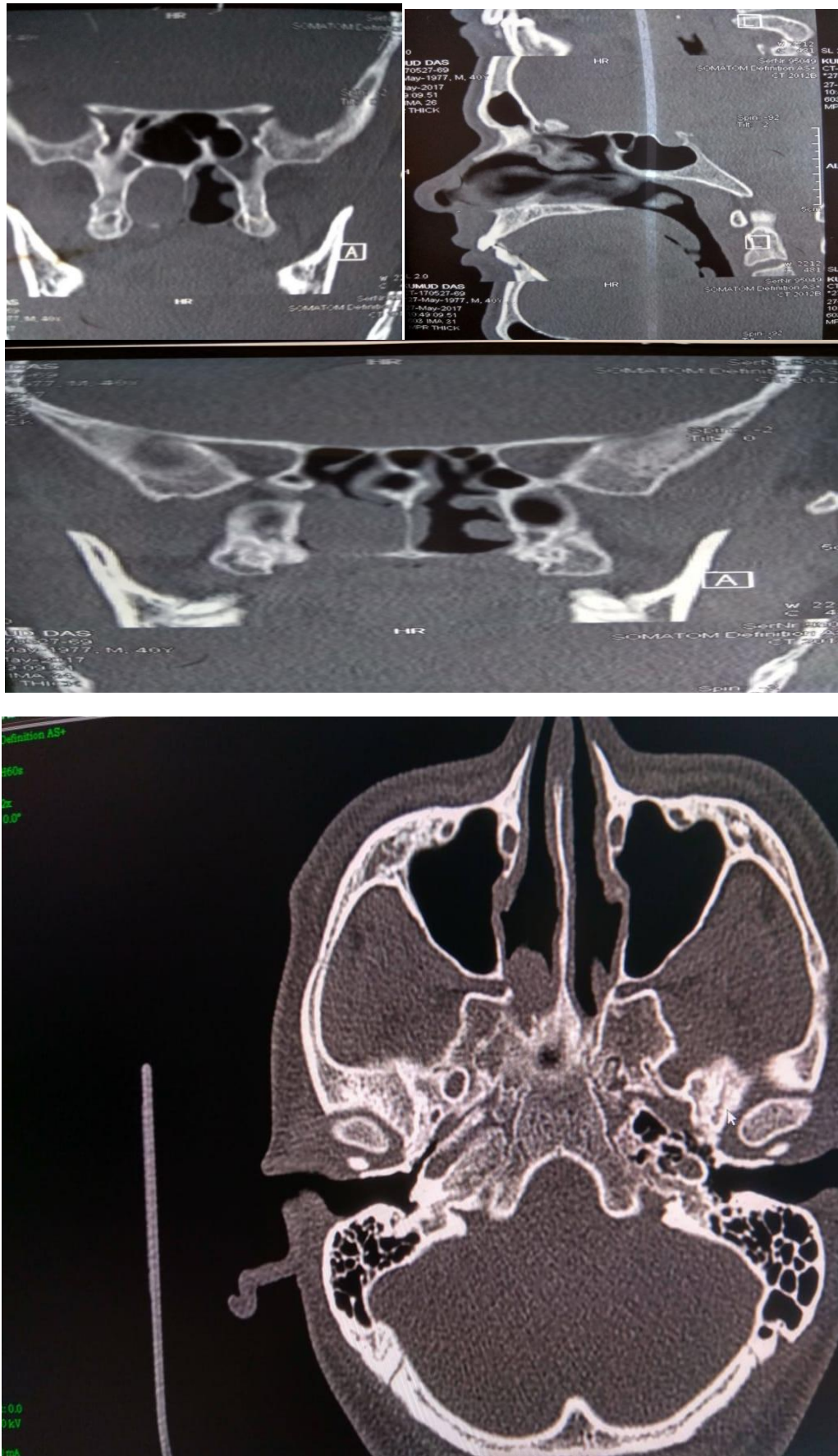


Fig. CT Scan shows polypoidal lesion in right nasal cavity abutting the septum and encroaching the posterior choana and dilated sphenopalatine foramen.

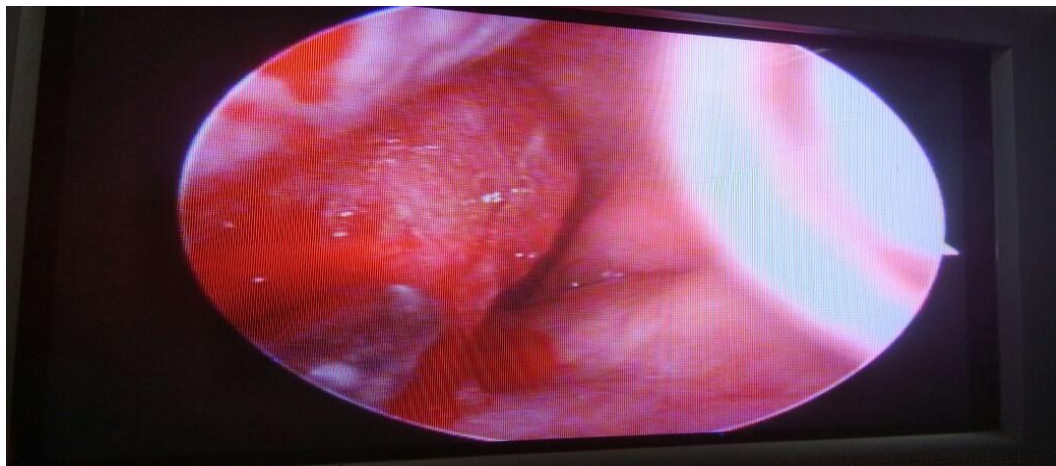


Fig.DNE showing fleshy mass in nasal cavity which bleeds on touch

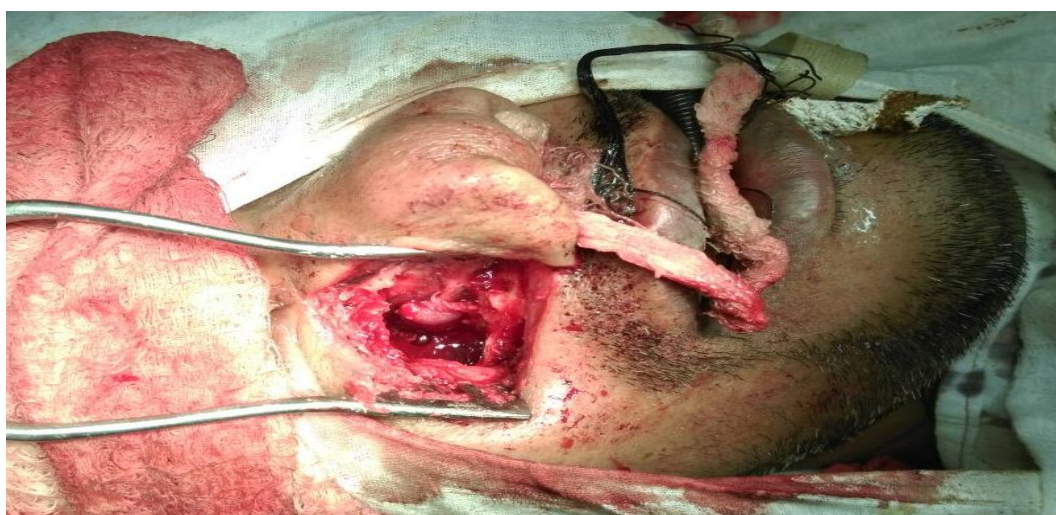


Fig. Intraoperative picture showing lateral rhinotomy incision and mass in nasal cavity.

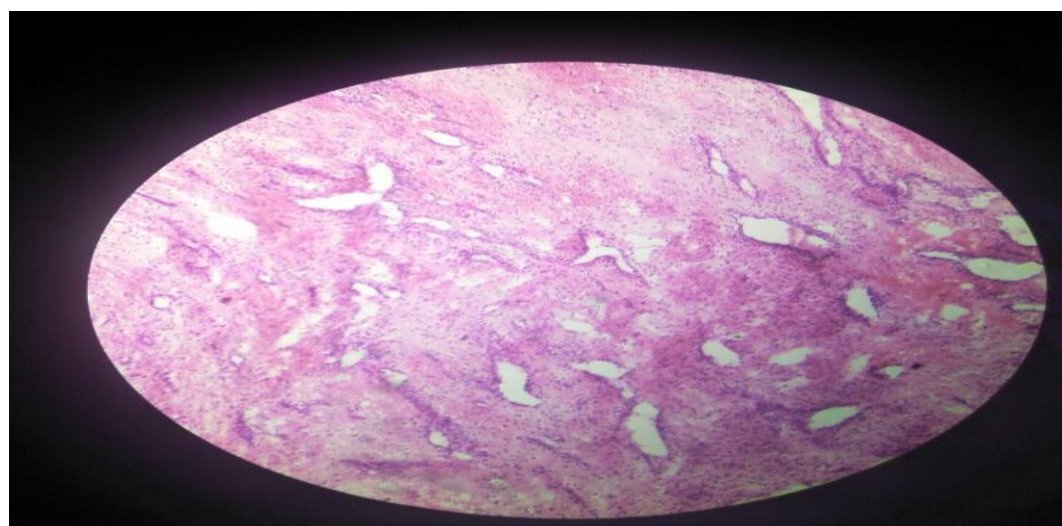


Fig. Histopathology slide showed subepithelial loose edematous fibrocollagenised stroma with numerous dilated and small vascular channels, lined by plump endothelial cells.



Fig. Postoperative picture of patient with lateral rhinotomy scar

III. Discussion

As per literature extremely rare, the nasopharyngeal angiofibroma can occur in elderly adults. Lukomski et al. in a study showed low incidence of this disease in adults [7]. These are composed of both vascular and fibrous elements intermingling together [8]. This patient usually presents with nasal obstruction and epistaxis out of which one symptom usually predominance depending on the proportion of elements. A lot of theories exists about the pathogenesis of JNA which is considered as a hamartomatous nidus of inferior turbinate tissue mass located in nasopharynx with testosterone acting over it, this why it presents in adolescent age. There is also evidence of increased type of androgen receptor and successfully tumor regression after anti-androgen therapy [9]. Other theory by Andrade, because of its high frequency in teenage males is due to intranuclear accumulation of androgen receptors and by a high number of growth factors (VEGF - endothelial growth factor, TGFB - transforming growth factor beta) [10]. However, some theories also state it as a vascular malformation due to incomplete regression of the first branchial artery [11]. Some consider it to be vascular malformation originating from endothelial cells [12]. Work has also been done by studying the expression of various growth factors and oncogenes such as C-KIT and C-MYC over nasopharyngeal angiofibroma [13]. The tumor can spread to various anatomical sites in and around Sphenopalatine foramen from where the tumor originates. The tumor usually extends along the path of least resistance like nasal cavity, nasopharynx, pterygopalatine fossa, maxillary sinus, infratemporal fossa, sphenoid sinus. and middle cranial Fossa [14]. The spread of JNA may be related to the number and laterality of the vessels that supply it [15].

Early diagnosis and treatment are required for good prognosis of JNA. The tumor having extending to orbit and intra cranial extension are difficult to treat. Pathognomic radiological sign of JNA is anterior bowing of posterior maxillary wall (Holman miller sign) [16]. Diagnosis by imaging is based on site of origin, hyper visualization after contrast enhancement and pattern of growth. Ultimately the diagnosis is made by clinical history, radiological examination and histopathology report.

IV. Conclusion

Nasopharyngeal angiofibroma in adult male population is extremely rare. Adult male presenting with profuse bleeding should not be taken lightly. Uncommon features such as age of the patient, should be kept in mind and clinician must be able to correlate clinical and radiological features for accurate diagnosis. These unusual presentations make us think about the need of more research work regarding origin and pathogenesis of nasopharyngeal angiofibroma.

Reference

- [1]. Paris J., Guelfucci B., Moulin G., Zanaret H., Triglia M., Diagnosis and treatment of juvenile nasopharyngeal angiofibroma. *Eur Arch Otorhinolaryngol*, 2001;258:120-4.
- [2]. Liu L, Wang R, Huang D, et al. Analysis of intra-operative bleeding and recurrence of juvenile nasopharyngeal angiofibromas. *Clin Otolaryngol Allied Sci*. 2002; 27:536-40
- [3]. Gallard A.L., Anastacio V.M., Piatto V.B., Maniglia J.V., Molina F.D., A seven-year experience with juvenile nasopharyngeal angiofibroma. *Braz J Otorhinolaryngol*, 2010;76(2):245-50
- [4]. Bremer JW, Neel HB III, DeSanto LW, Jones GC. Angiofibroma: treatment trends in 150 patients during 40 years. *Laryngoscope* 1986;96:1321-9.
- [5]. Mishra S, Praveena NM, Panigrahi RG, Gupta YM. Imaging in the diagnosis of juvenile nasopharyngeal angiofibroma. *J Clin Imaging Sci*. 2013;3(Suppl 1):1

- [6]. Park C.K., Kim D.G., Paek S.H. et al., Recurrent Juvenile Nasopharyngeal Angiofibroma Treated with Gamma Knife Surgery. *J Korean Med Sci*, 2006;21:773-7
- [7]. Lukomski M., Danilewicz M., Pajor A., Juvenile angiofibroma in adults. *Otolaryngol Pol*, 2008;62(1):20-6
- [8]. Huang RY, Damrose EJ, Blackwell KE, et al. Extra nasopharyngeal angiofibroma. *Int J Pediatr Otorhinolaryngol*. 2000; 54: 59–64.
- [9]. Schick B, Rippel C, Brunner C, Jung V, Plinkert PK, Urbschat S. Numerical sex chromosome aberrations in juvenile angiofibromas: Genetic evidence for an androgen-dependent tumor? *Oncol Rep*. 2003;10:1251–5.
- [10]. Andrade N.A., Andrade J.S.C., Silva P.D.M. et al., Angiofibroma Nasofaríngeo: Revisão dos aspectos genéticos e moleculares. *Arq Int ORL*, 2008;12(3):442-449
- [11]. Eloy Ph, Watelet JB, Hatet AS, et al., Endonasal endoscopic resection of juvenile nasopharyngeal angiofibroma. *Rhinology*, 2007;45:24-30
- [12]. Liang J, Yi Z, Lianq P. The nature of juvenile nasopharyngeal angiofibroma. *Otolaryngol Head Neck Surg* 2000; 123:475-81.
- [13]. Renkonen S, Häyry V, Heikkilä P, Leivo I, Haglund C, Mäkitie AA, et al. Stem cell-related proteins C-KIT, C-MYC and BMI-1 in juvenile nasopharyngeal angiofibroma – do they have a role? *Virchows Arch*. 2011;458:189–95.
- [14]. Liang J, Zixiang Y, Ping L (2000) The nature of juvenile nasopharyngeal angiofibroma. *Otolaryngol Head Neck Surg* 123:475-81
- [15]. Sennes LV, Butugan O, Formigoni LG, Bento RF. Juvenile nasopharyngeal angiofibroma: a study on extension and vascularization. In: Stammberger H, Wolf G, eds. XVII European Rhinologic Society & International Symposium of Infection and Allergy of the Nose. ERS & ISIAN Meeting '98. Proceedings. Bologna, Italy: Monduzzi Editore, 1998:433-7
- [16]. Garça MF, Yuca SA, Yuca K. Juvenile nasopharyngeal angiofibroma. *Eur J Gen Med*. 2010;7:419–25.

Dr. Pradeep Singh Rawat "Rare presentation of nasopharyngeal angiofibroma in adult" *IOSR Journal of Dental and Medical Sciences (IOSR-JDMS)*, vol. 17, no. 6, 2018, pp 57-61